

IMAGERIE et IMPLANTOLOGIE

*Dr Denis Bossard. Radiologue.
Hôpital Privé Jean Mermoz LYON*

13 Janvier 2011

plan

- Radiologie: principes
- Radiologie conventionnelle
 - Panoramique dentaire
 - Autres
- Scanner
- Cone-Beam CT
- Avenir

Radiologie: PRINCIPES

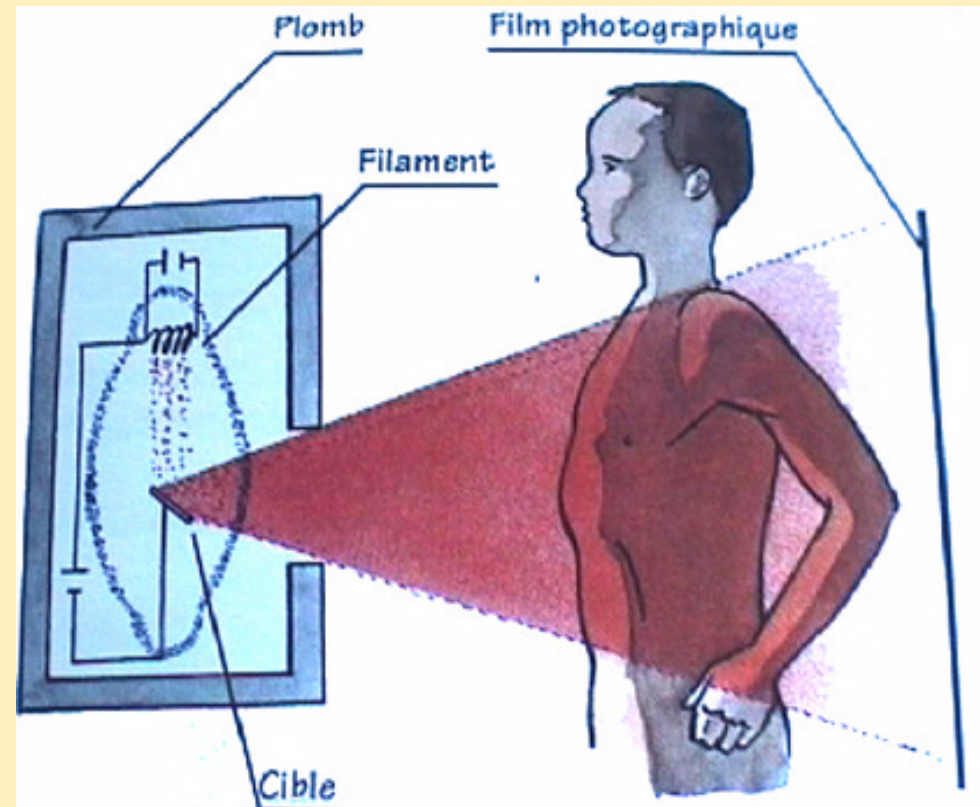
Les rayons X

- sont invisibles à l'œil (courte longueur d'onde: $1/10000000$ mm)
- Mais traversent la matière.

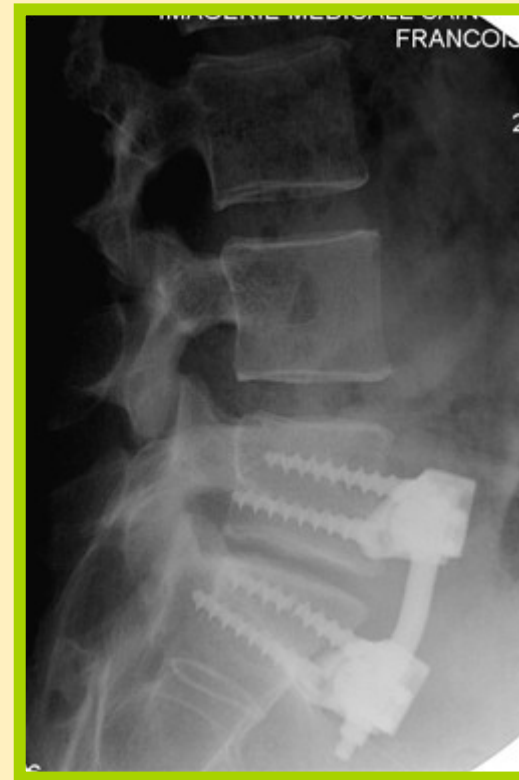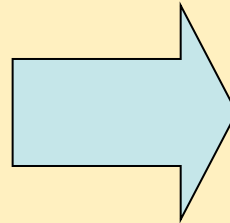
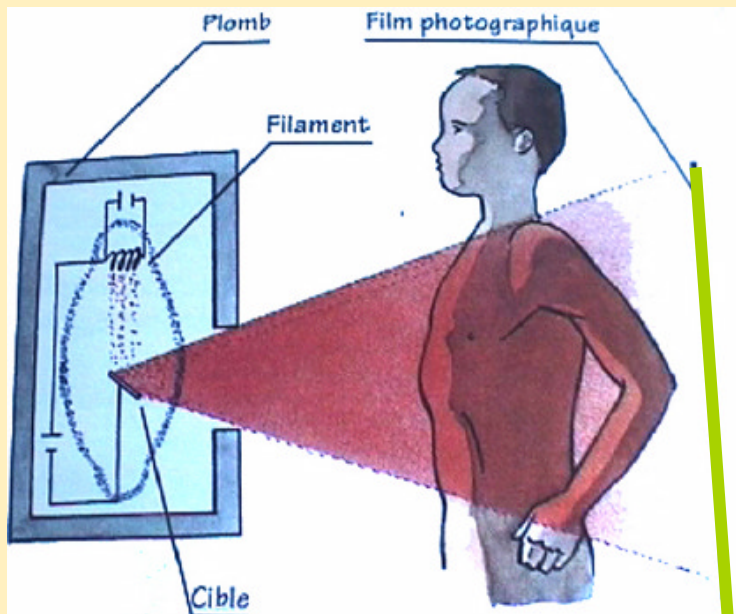
Radiologie: PRINCIPES

Les rayons X : Tube de Coolidge:

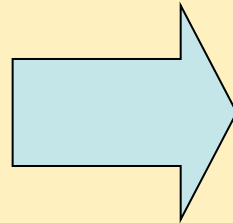
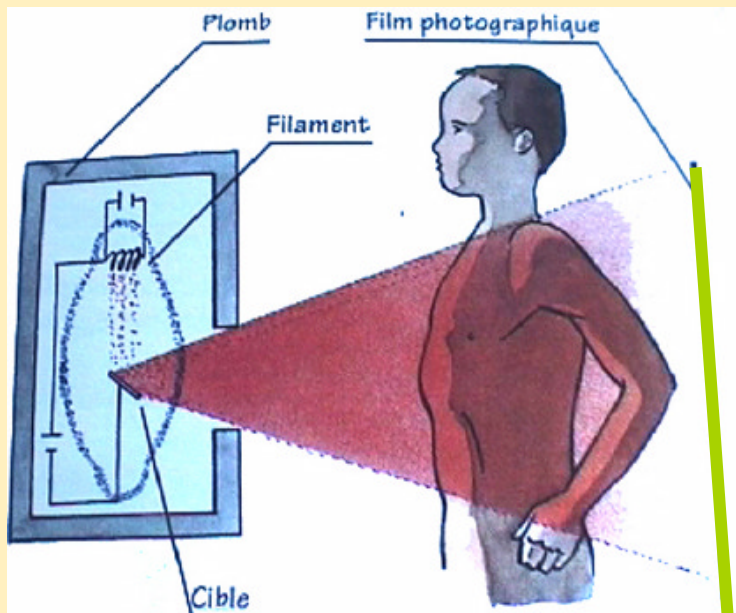
- filament de Tungsten dans le vide + alimentation électrique: émission d' électrons.
- Percussion des électrons sur une cible positive:
- Production de Photon X
- Formation d' un faisceau.



Radiologie: PRINCIPES



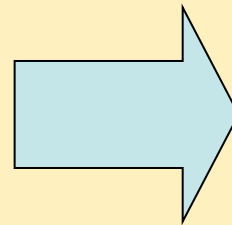
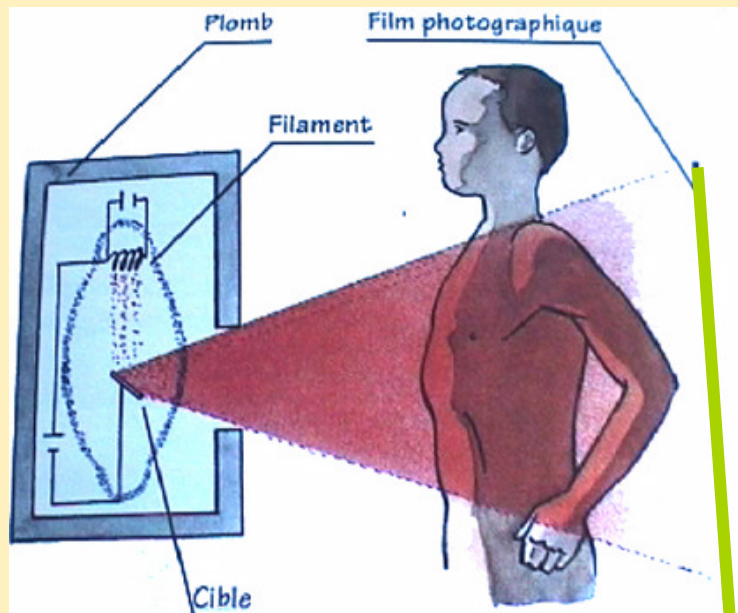
Radiologie: PRINCIPES



FILM ARGENTIQUE

- Développement
- Unique
- Non modifiable
- Usure
- Statique...

Radiologie: PRINCIPES



CAPTEUR NUMERIQUE

- Pas de developmt.
- Modifiable
- Transmissible et Archivable:
 - Réseau
 - Imprim. laser
 - CD...

Radiologie

CONVENTIONNELLE

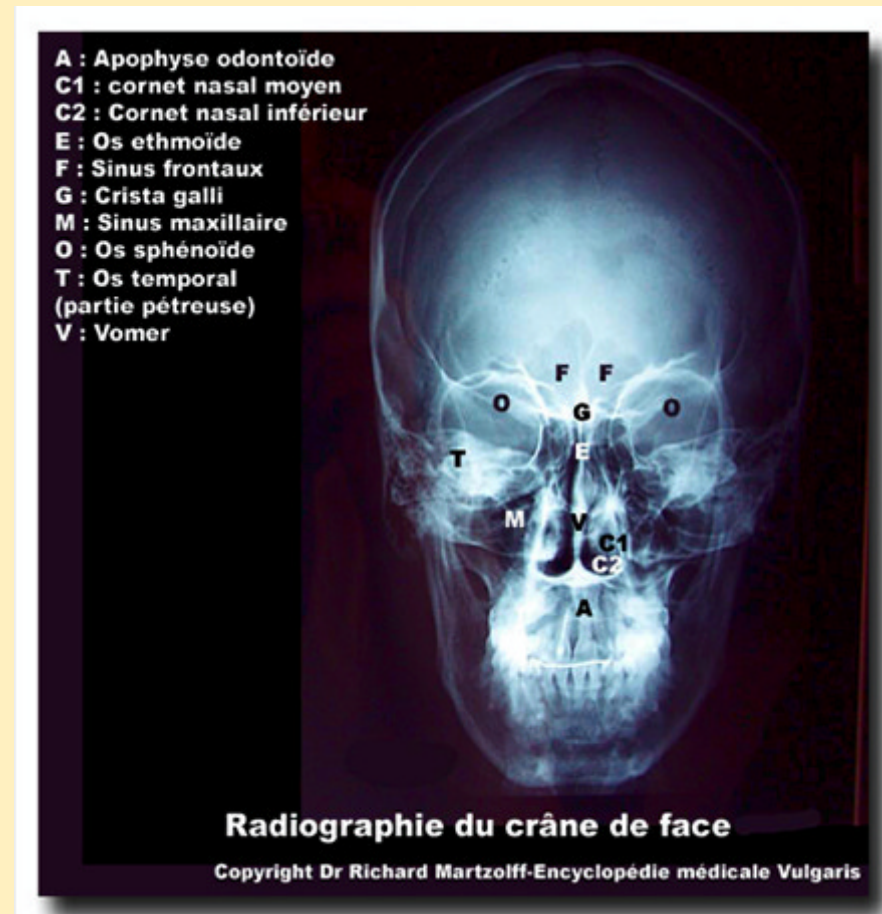
- Le PANORAMIQUE DENTAIRE
- Les clichés endo-buccaux
- Autres

Le PANORAMIQUE DENTAIRE

- Ou ORTHOPANTOMOGRAMME
- Ou OPT
- Ou « ORTHO »
- Ou « PANO »

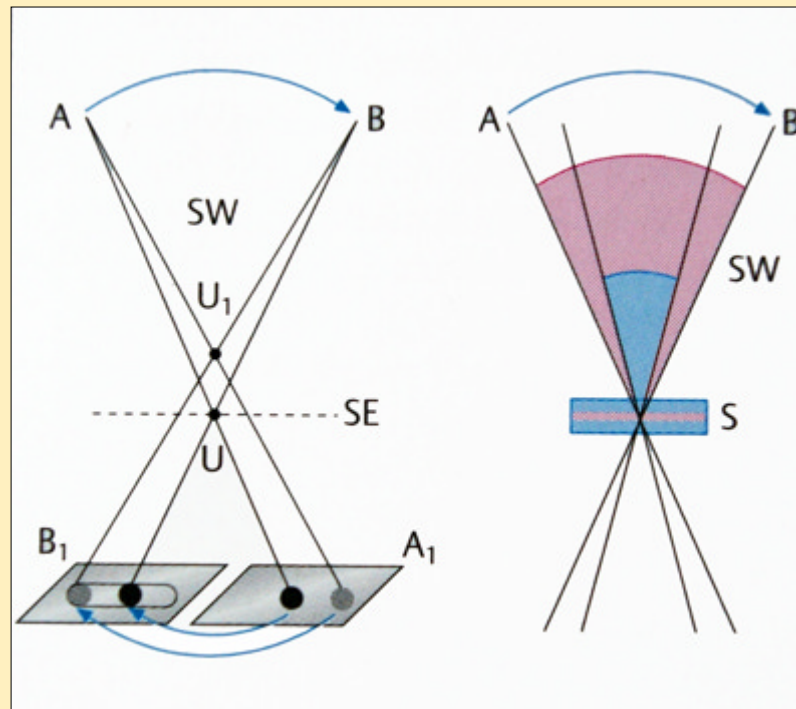
Le PANORAMIQUE DENTAIRE

- Principe: comment ne garder que les dents (ou presque...).



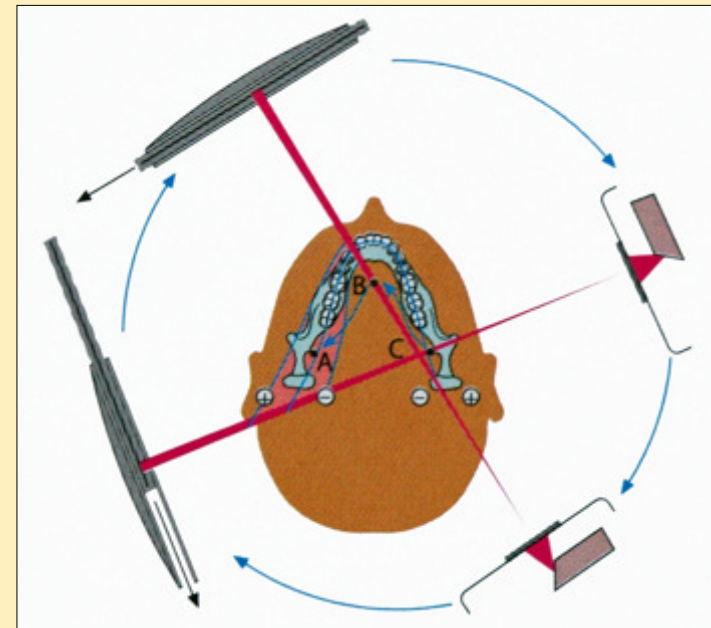
Principe

- Technique en coupes
 - Trajet du foyer de rayons X (AB)
 - Trajet inverse du récepteur d'images (A1B1)
 - Plan de coupe (tomographie ou zonographie)



Principe

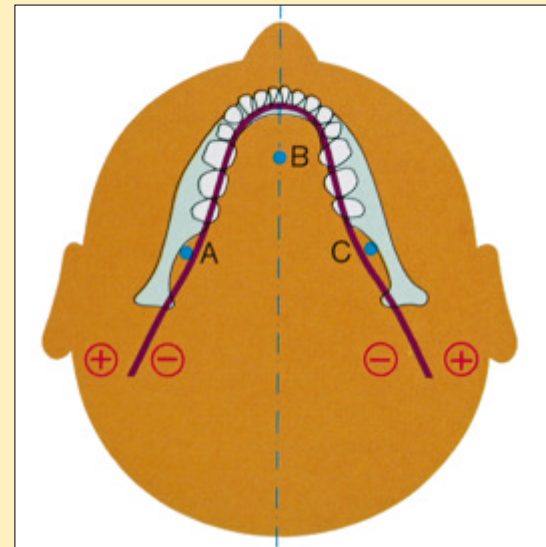
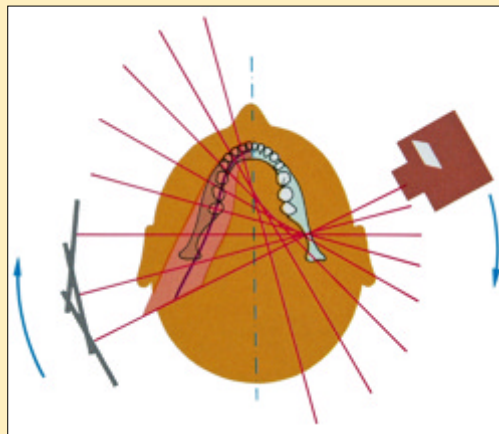
- OPT
 - Foyer de RX et support du récepteur
 - => déplacement dans le sens horaire
 - Récepteur d'images
 - => glissement en sens inverse
 - RX : fente verticale
(foyer et récepteur)



Principe

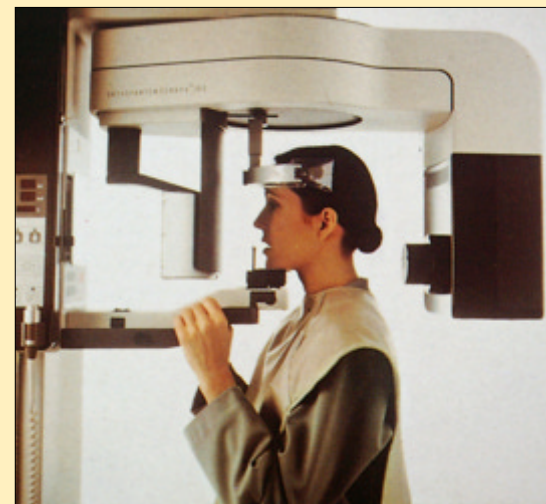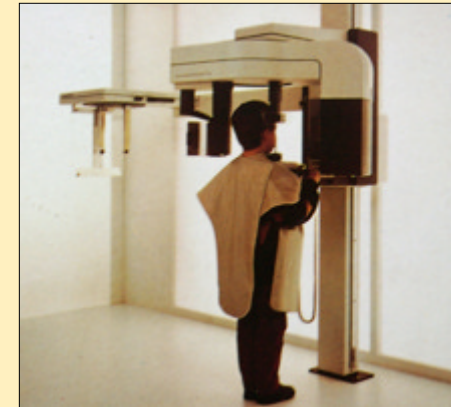- Epaisseur de coupe
 - Adaptée à l'âge et à la configuration mandibulaire (signes + et -)
 - Variations : 9 mm (région médiane) à 20 mm (ATM)
- Trajet elliptique de la coupe
 - Autour de 3 colonnes de rotation du faisceau RX

(C, B, A) (Paatero, 1940)



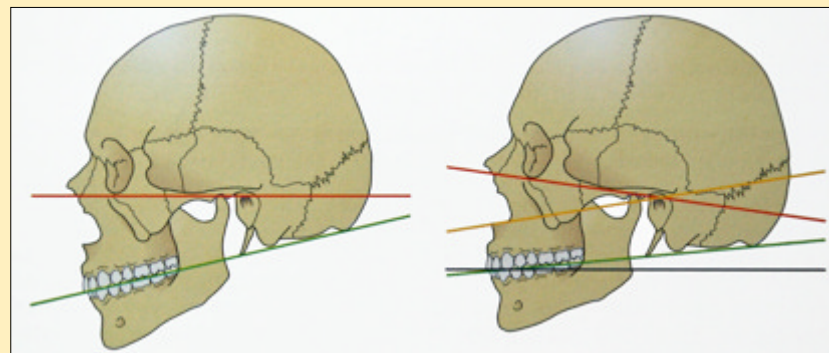
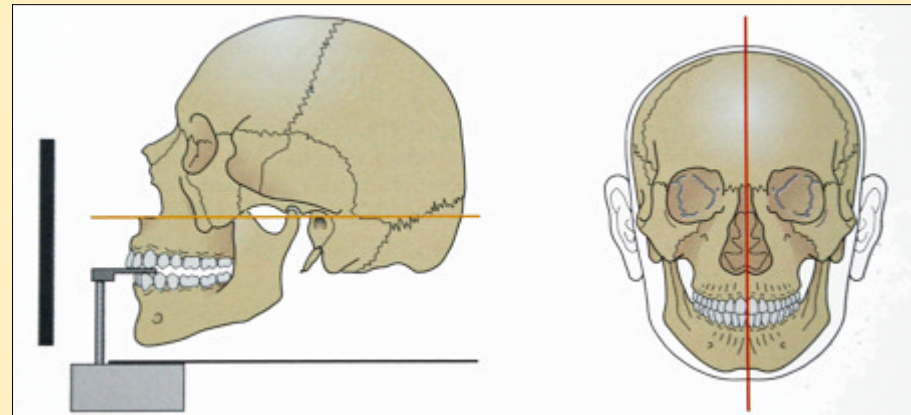
Positionnement du patient

- Pieds joints légèrement en avant du centre de gravité du corps
- Préhension des poignées
- Regard à l'horizontal
- Morsure de la pièce occlusale
- Céphalostat adapté à la taille du crâne
- Langue contre le palais
- Respiration régulière et peu profonde



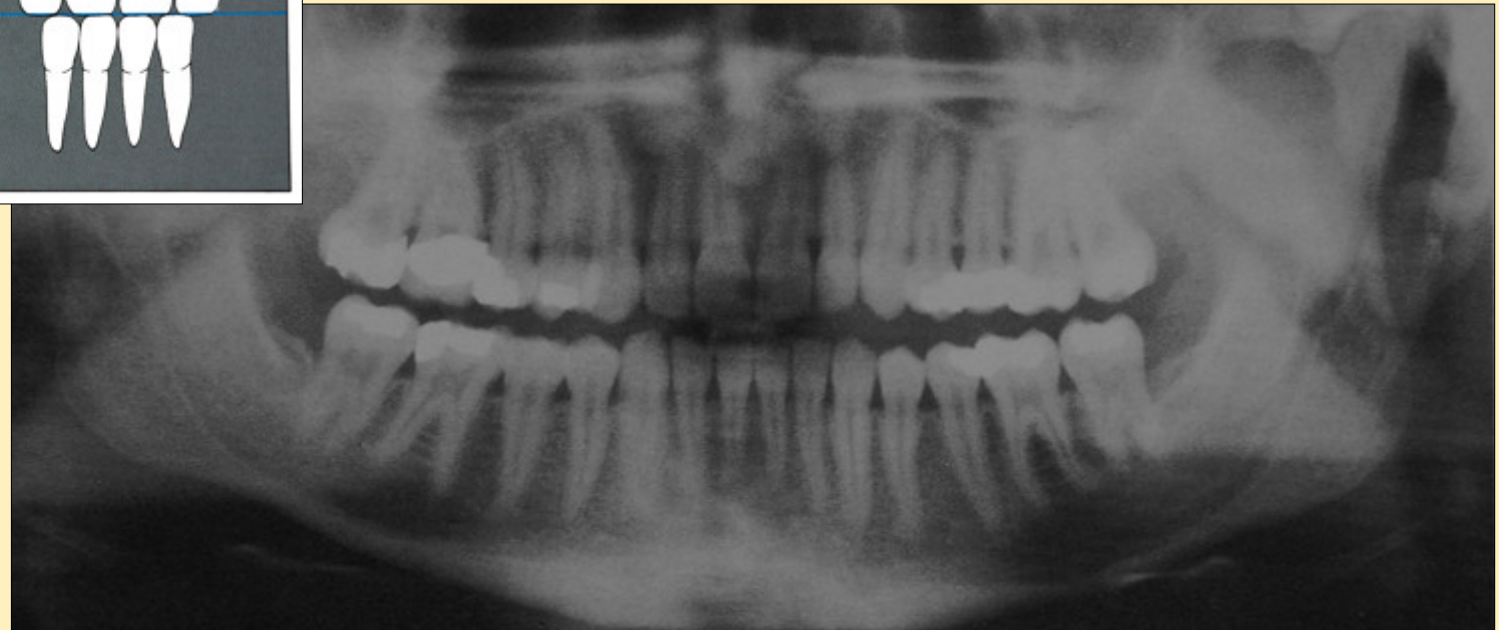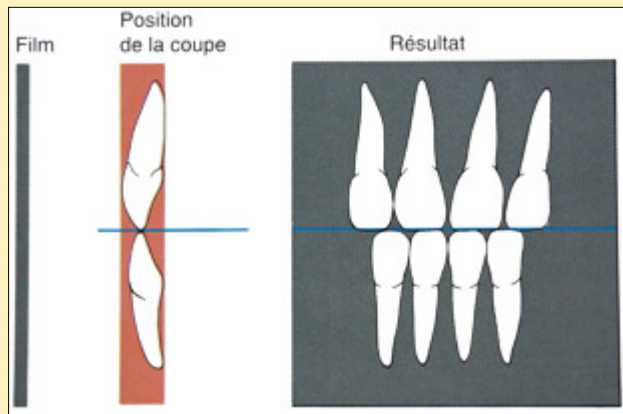
Positionnement du patient

- Vue de profil : plan d'occlusion horizontal
=> Plan de Camper horizontal
- Vue de face :
=> PSM vertical



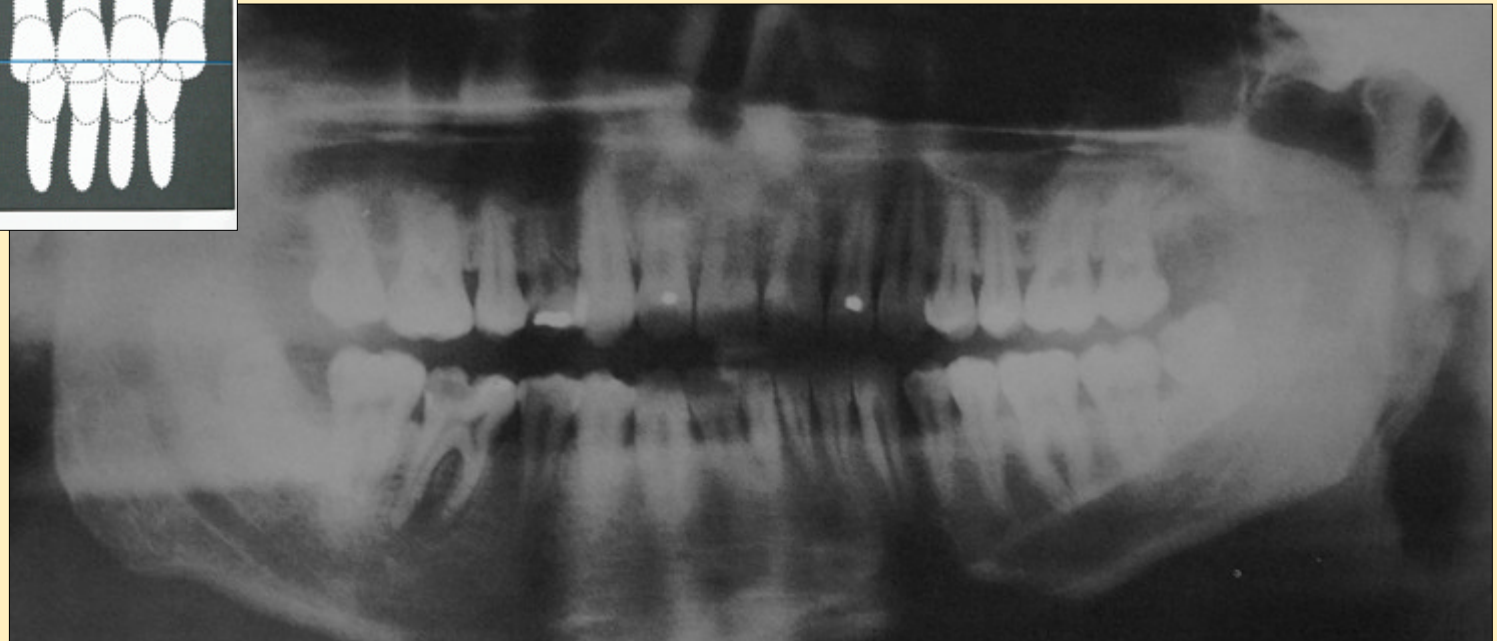
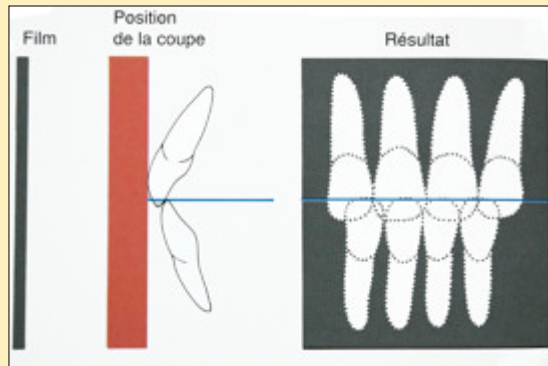
Erreurs de position

- Région incisive
 - Situation correcte



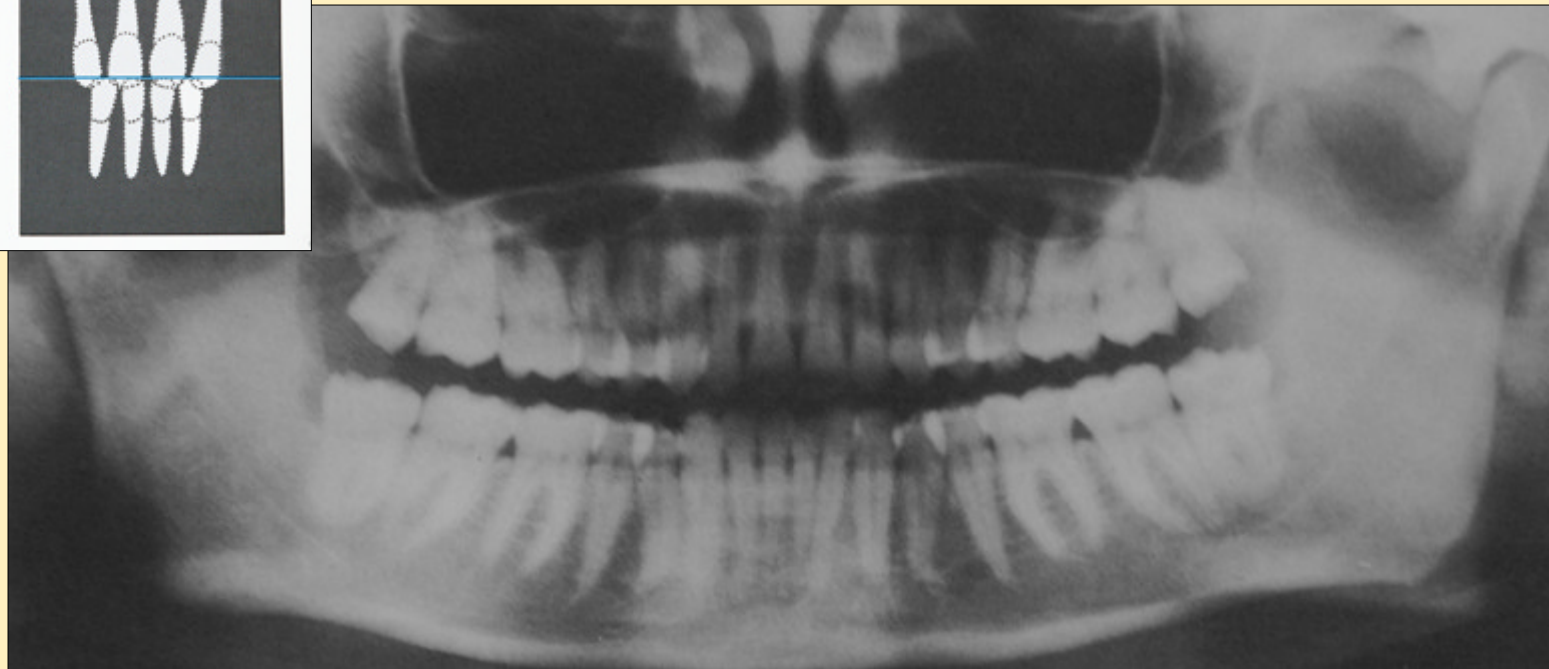
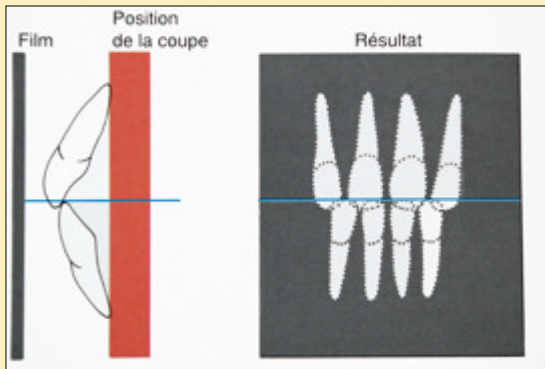
Erreurs de position

- Région incisive
 - Situation *en arrière* du plan de coupe
 - => aspect *flou et élargi*



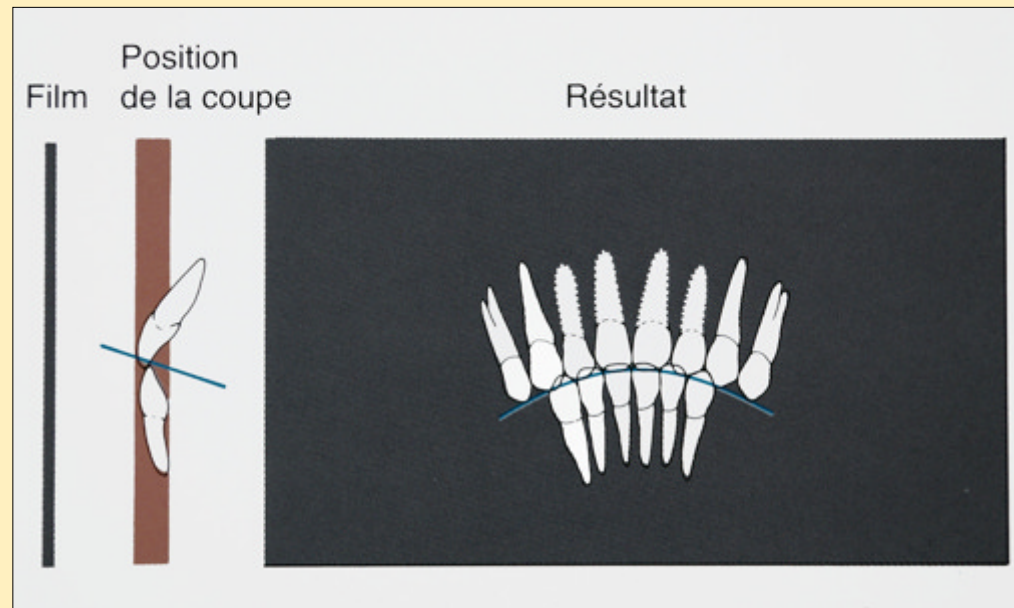
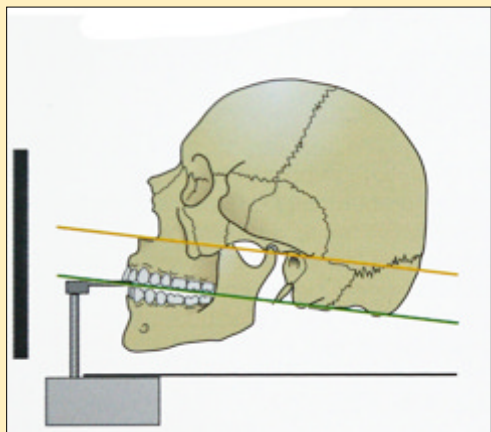
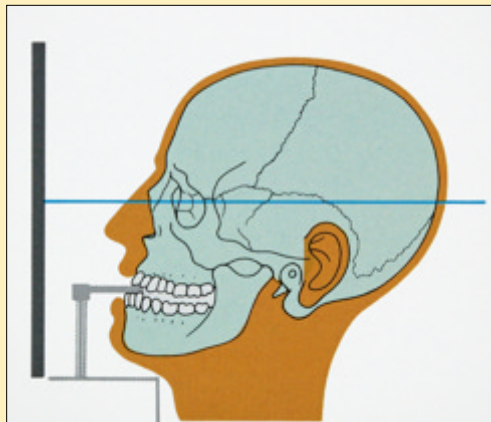
Erreurs de position

- Région incisive
 - Situation *en avant* du plan de coupe
 - => aspect *flou et rétréci*



Erreurs de position

- Extension cervicale (Pièce occlusale trop haute)
=> plan occlusal abaissé vers l'arrière



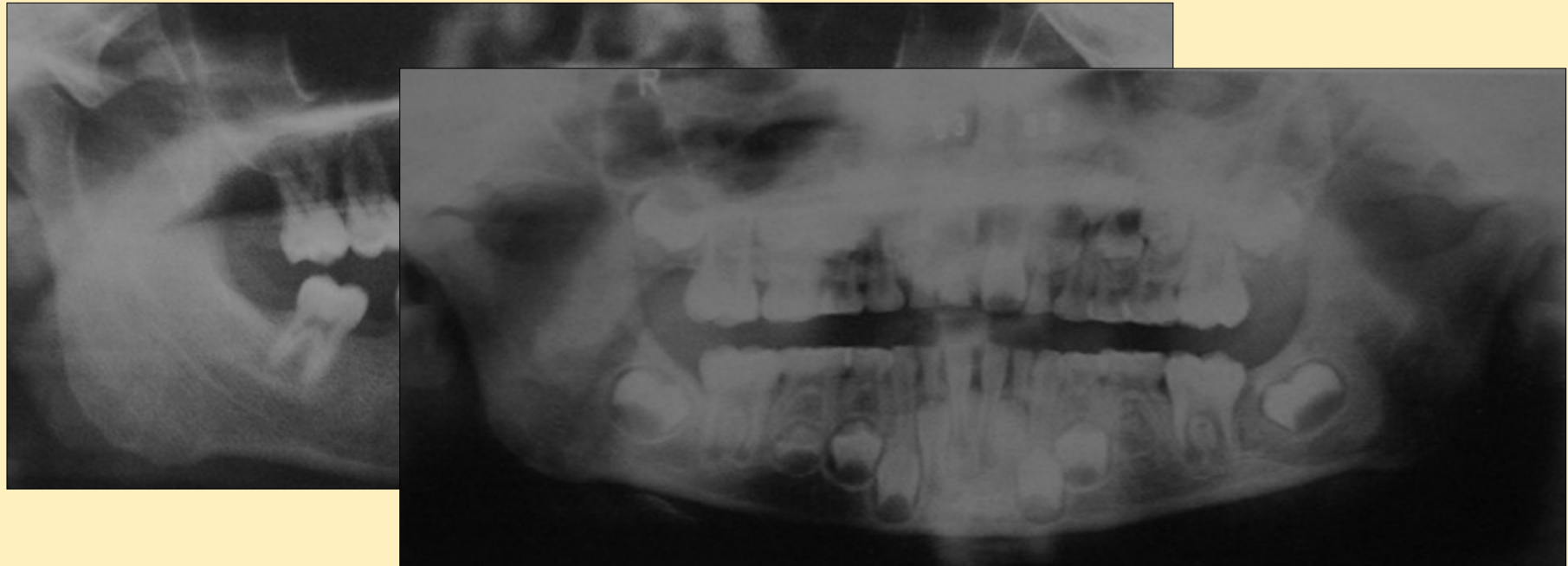Erreurs de position

- **Extension cervicale** (Pièce occlusale trop haute)
=> plan occlusal abaissé vers l'arrière

Plan occlusal et voûte palatine + plancher FN : arcs concaves vers le bas

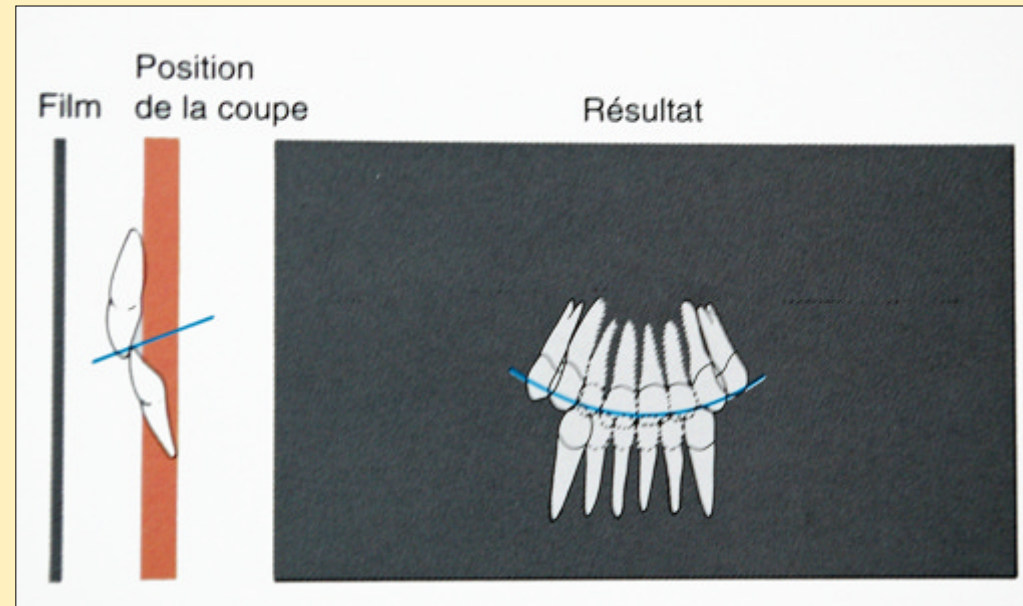
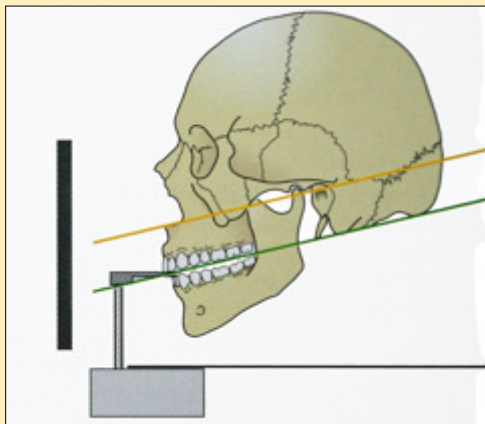
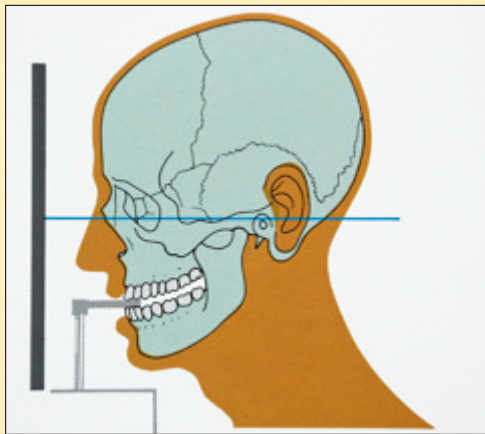
Région apicale dents maxillaires : ± masquée

Période de dentition : gêne l'étude des germes



Erreurs de position

- Flexion cervicale (Pièce occlusale trop basse)
=> plan occlusal élevé vers l'arrière



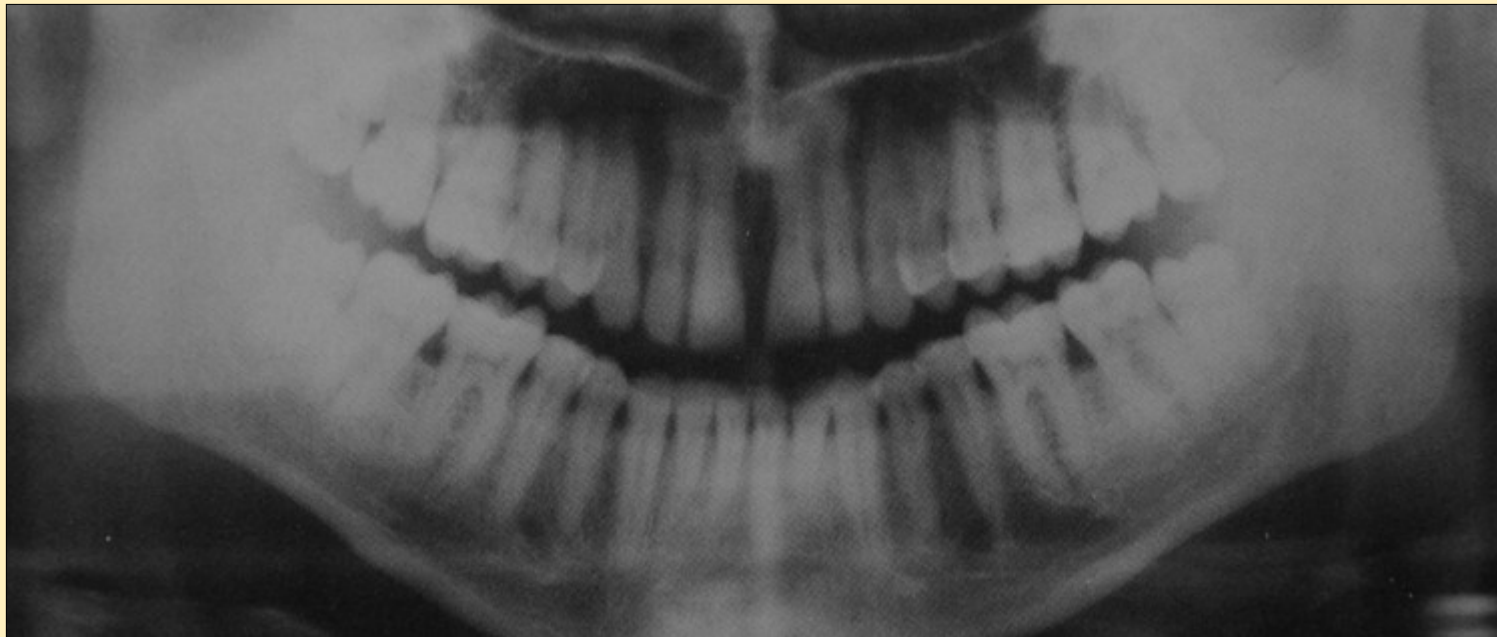
Erreurs de position

- Flexion cervicale (Pièce occlusale trop basse)
=> plan occlusal élevé vers l'arrière

Plan occlusal : arc concave vers le haut

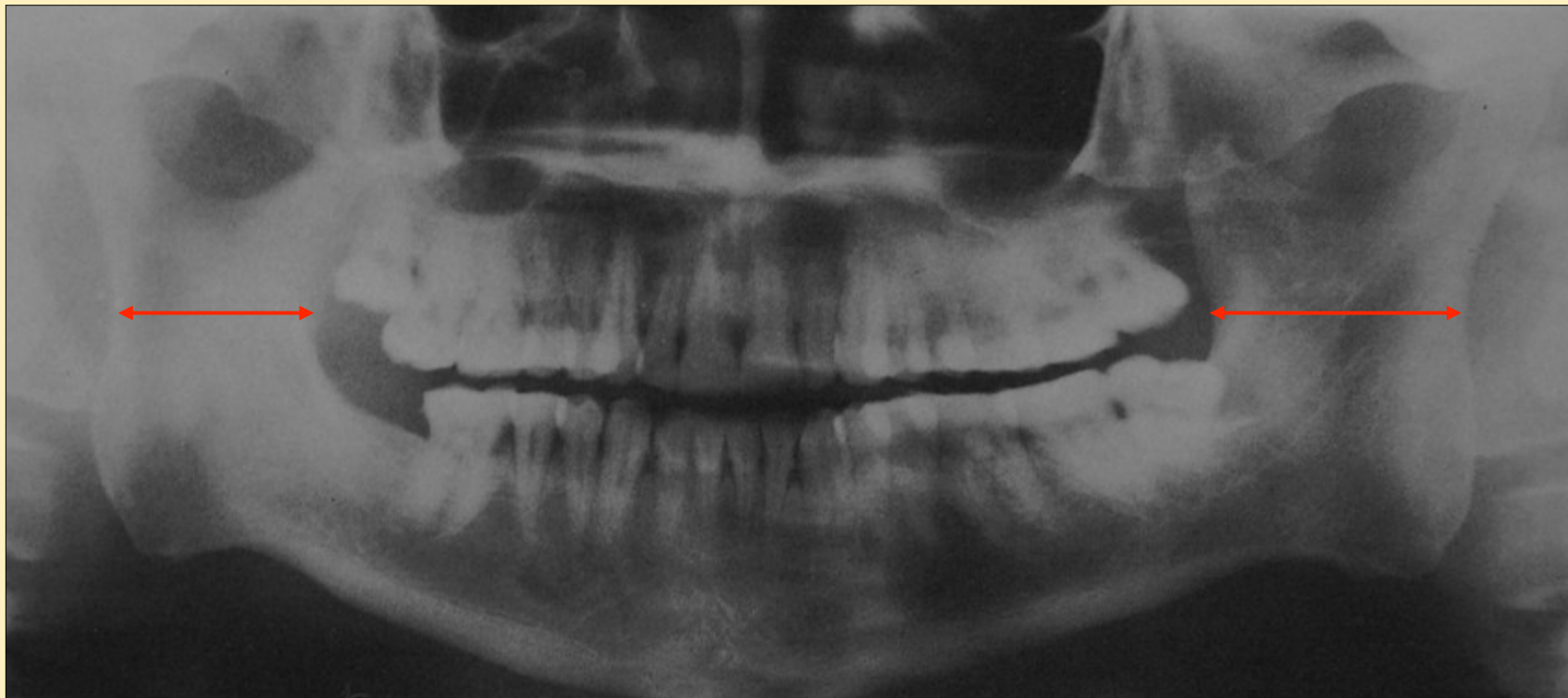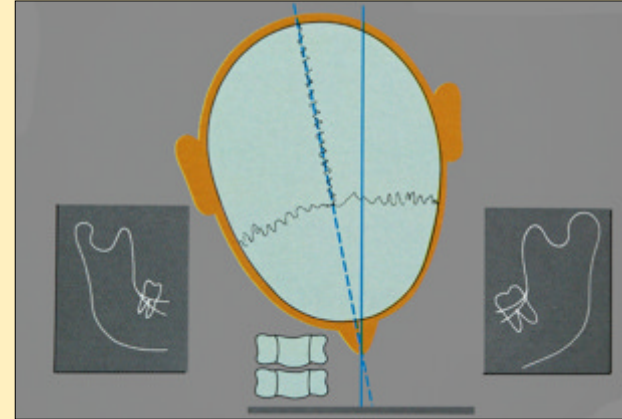
Surfaces approximatives dents latéro-maxillaires superposées

ATM souvent non visualisable totalement



Erreurs de position

- Centrage incorrect



Erreurs de position

- Auto-évaluation

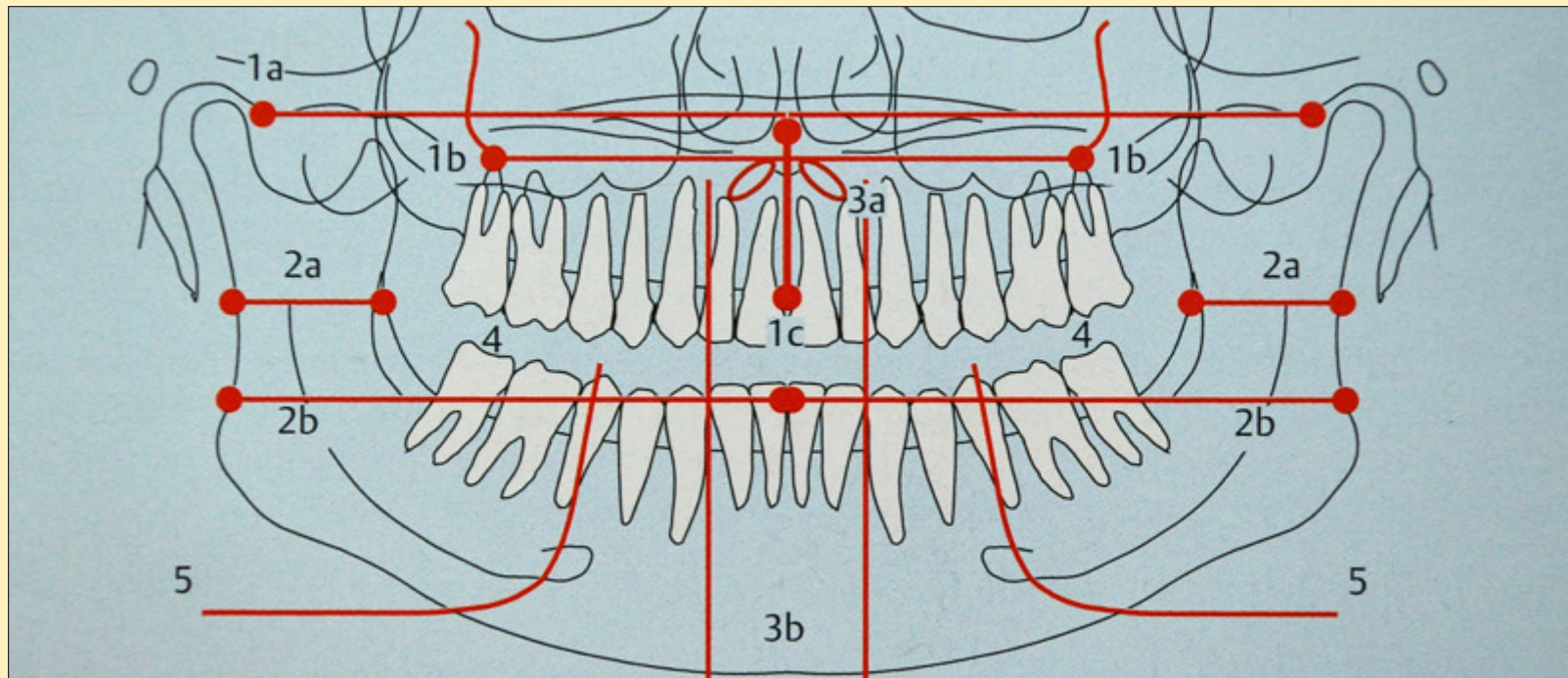
1a : condyle temporal (obliquité PSM)

1b : ligne innominée

1c : verticalité PSM

2a : déviation PSM

...



Effets de sommation

- Définition
 - Résultat de la rencontre par le faisceau RX des diverses structures situées sur son trajet
 - => sommation de la 3ème dimension sur l' image radiographique bidimensionnelle
- Types
 - Effet de soustraction
 - Effet d' addition

Effets de sommation

– *Effet de soustraction*

Zone aérique

=> Faisceau non atténué

=> Surprojection du contraste négatif aérique

=> Perte de netteté de la zone intéressée par surexposition (« burn-out effect »)

– *Effet d'addition*

Tissus mous, pièces squelettiques, objets radio-opaques

=> Faisceau atténué, moins pénétrant au niveau des structures concernées

=> Opacité \pm circonscrite

Effets de sommation

- Exemples d'effets de soustraction

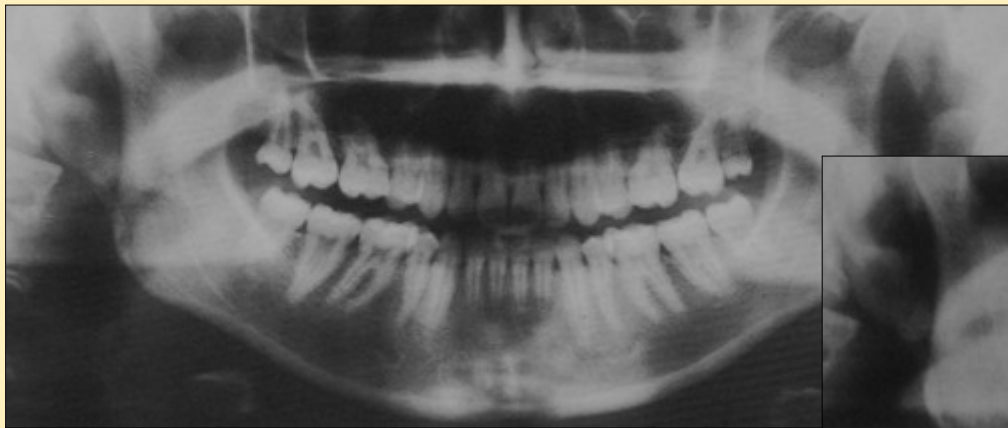
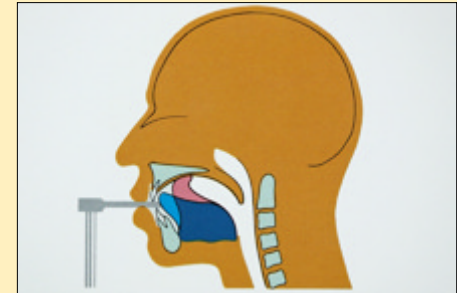
- Position *basse* de la langue

- => Perte de l'effet filtre de la langue

- => Moindre atténuation du rayonnement incident

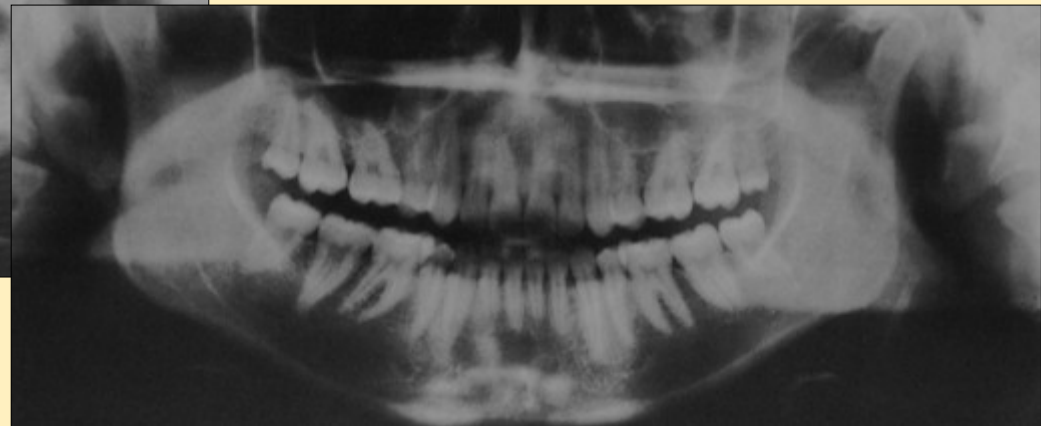
- => Surexposition

- => Effacement des structures maxillaires



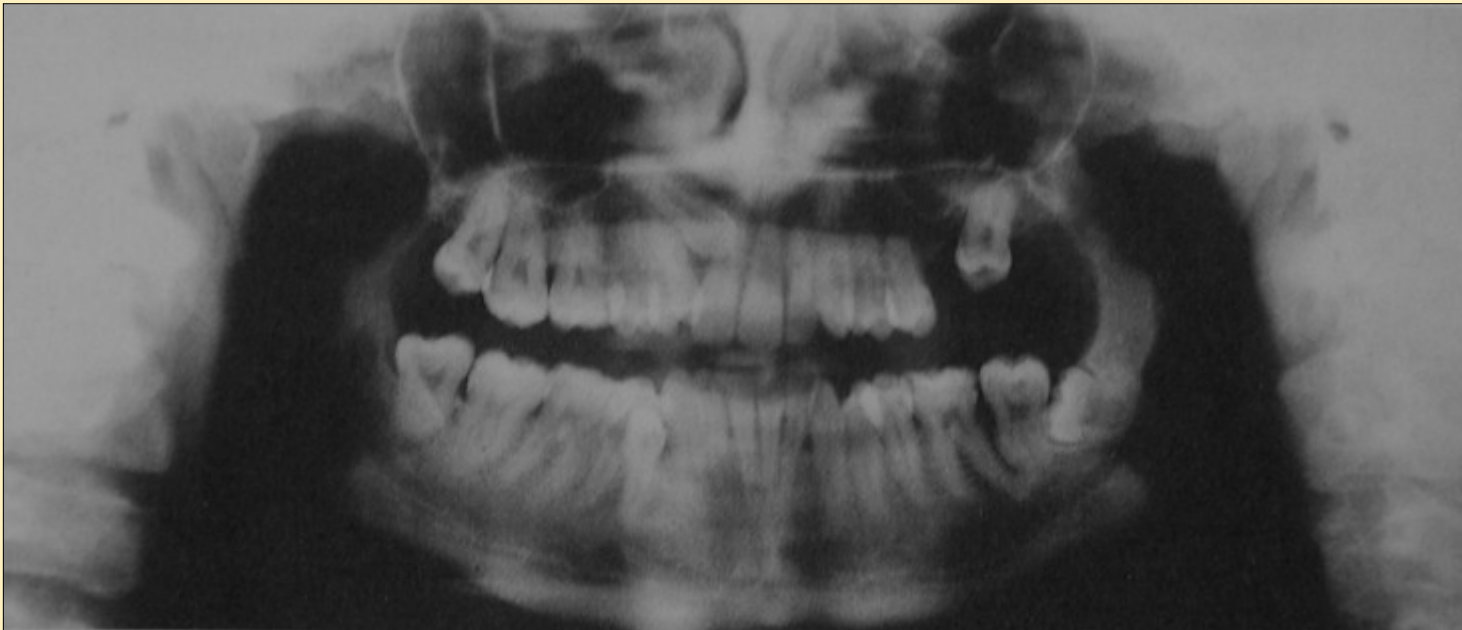Position linguale basse

Position linguale haute



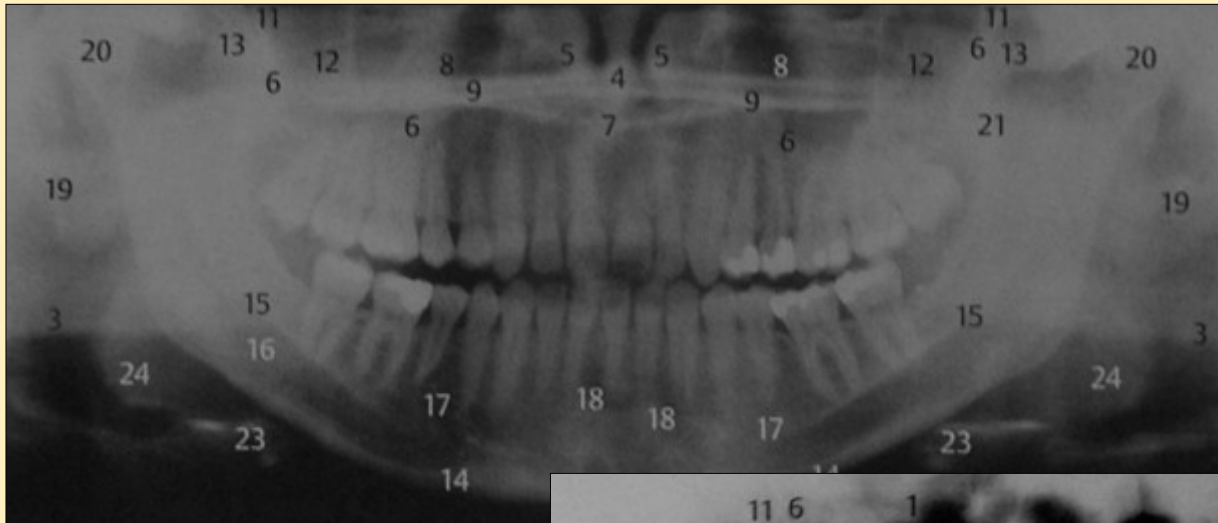
Effets de sommation

- Inspiration profonde + blocage respiratoire
 - => Pharynx gonflé d' air
 - => Surexposition bilatérale
 - => Invisibilité des angles et rami mandibulaires



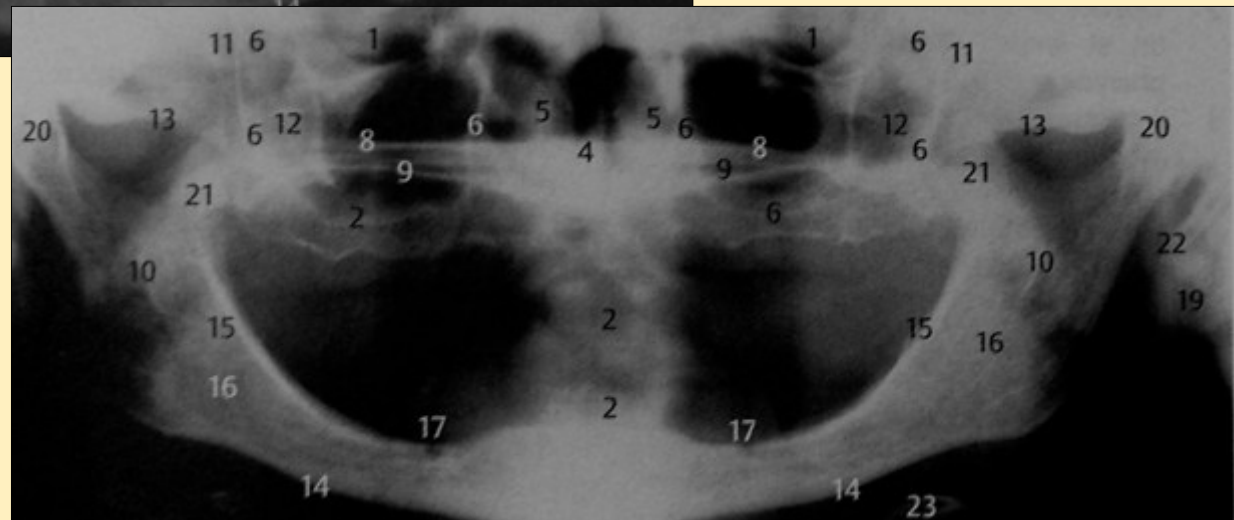
Effets de sommation

- Exemples d'effets d'addition



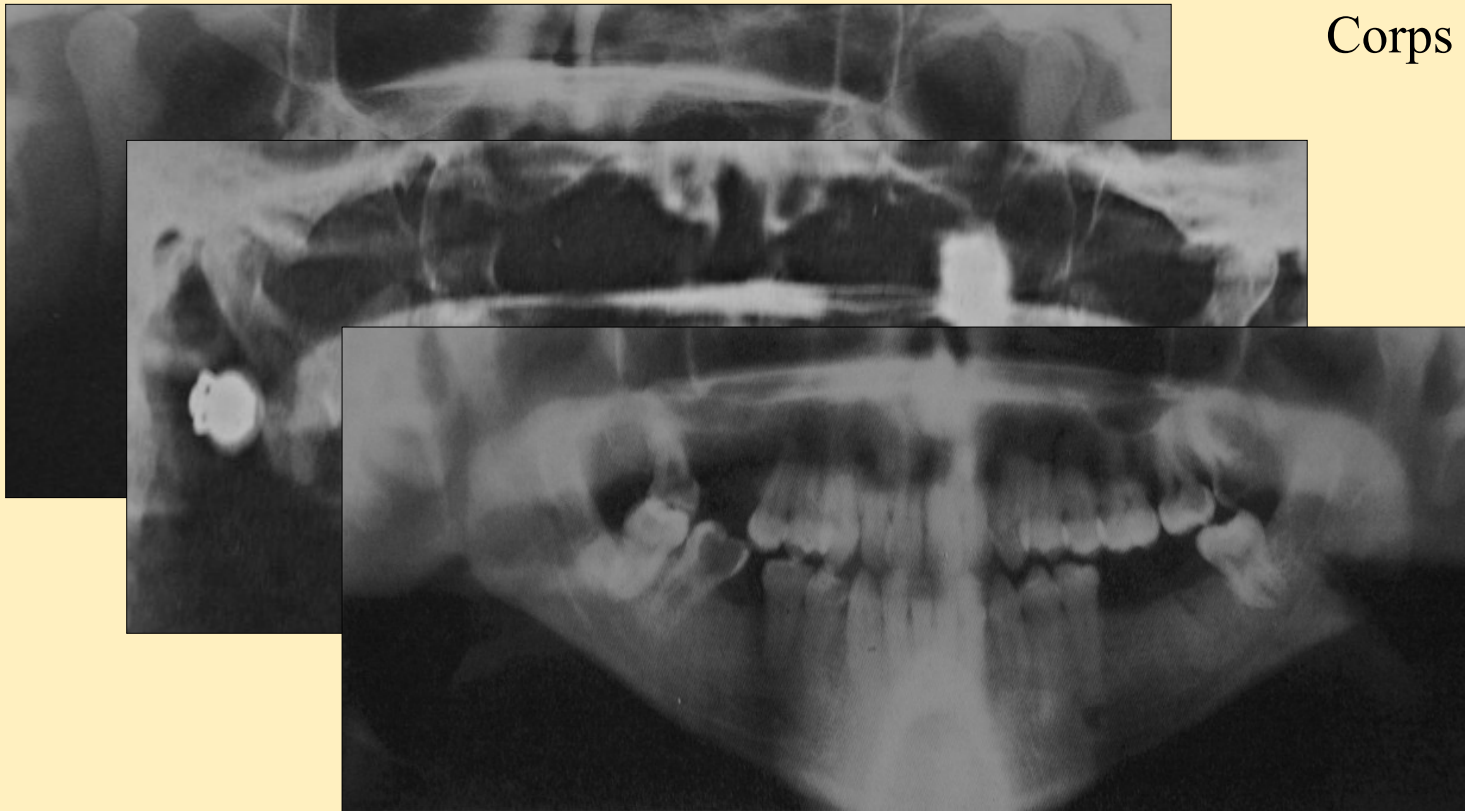
Hémi mandibule
controlatérale

Rachis cervical



Effets de sommation

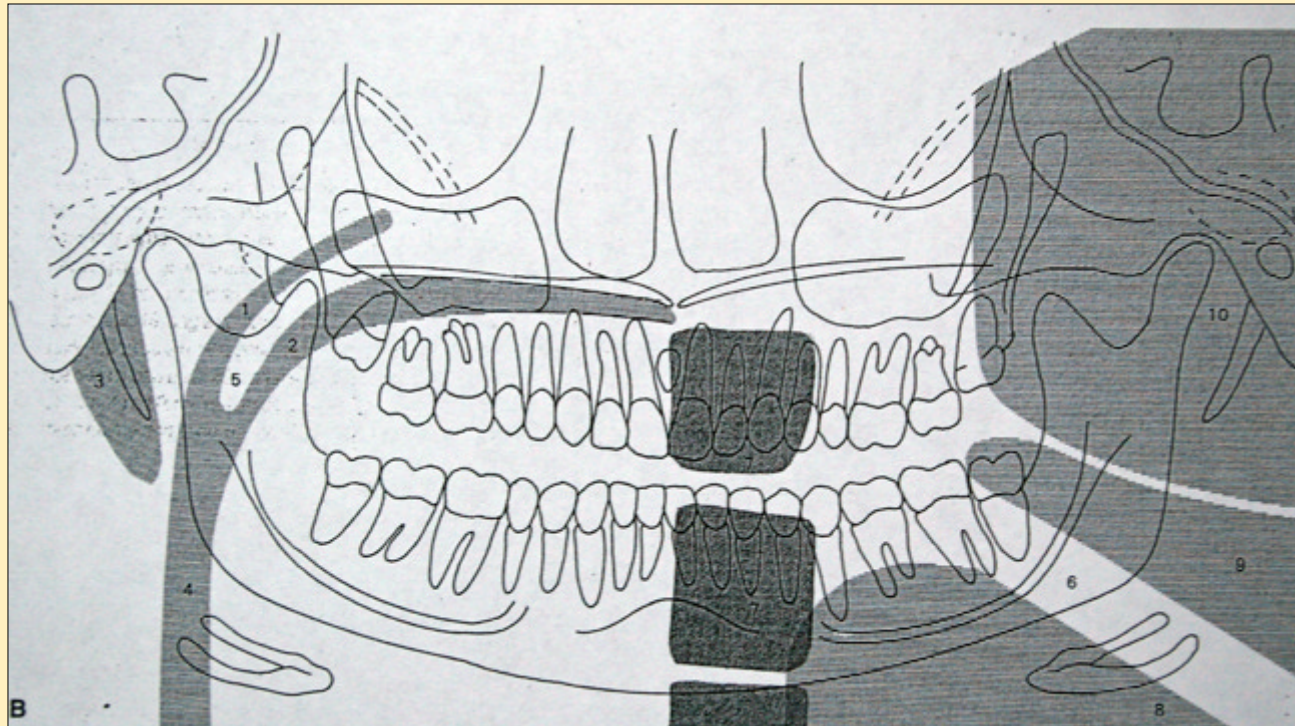
- Exemples d'effets d'addition



Corps étrangers

Radioanatomie

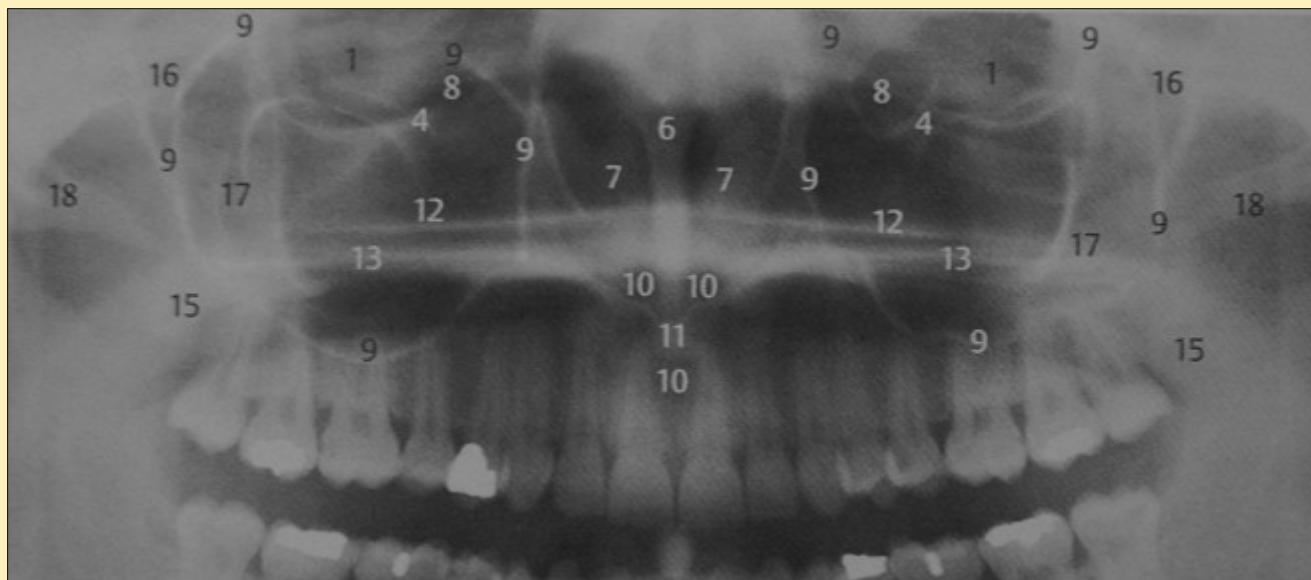
- Ombres projetées



- 1- Rhino-pharynx
- 2- Espace palato-glosse
- 3- Oreille
- 4- Espace glosso-pharyngé
- 5- Voile du palais
- 6- Menton
- 7- Colonne cervicale
- 8- Dispositif radio
- 9- Mandibule
- 10- Mandibule controlatérale

Radioanatomie

- Région maxillaire



1- Orbite

4- Canal infra-orbitaire

6- Septum nasal

7- Cornet nasal inférieur

8- Fosse du sac lacrymal

9- Sinus maxillaire (limites)

10- Canal naso-palatin (orifices nasaux et foramen incisif)

11- Epine nasale antérieure

12- Lame horizontale du palatin

13- Limite inféro-latérale du nasopharynx

15- Voile du palais

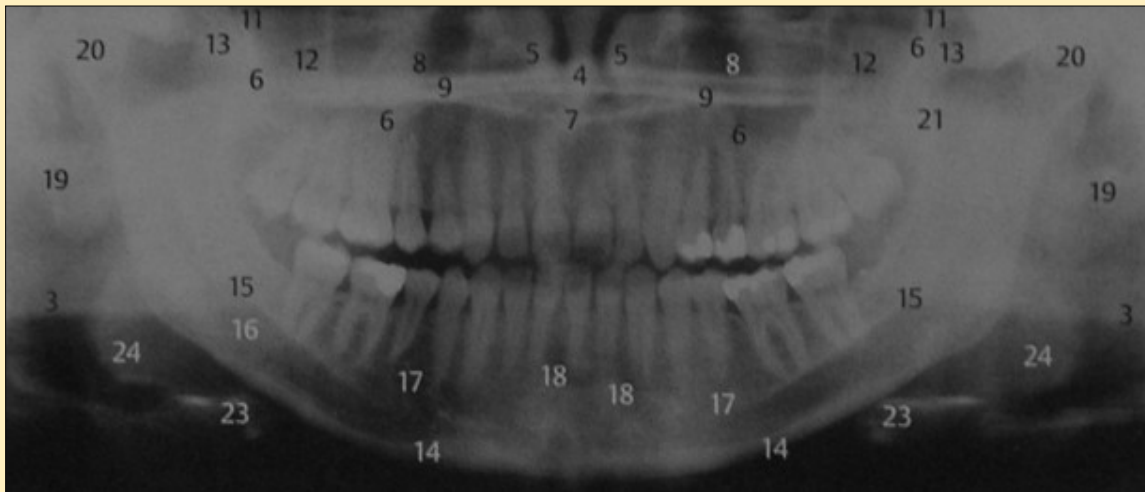
16- Fosse ptérygo-palatine

17- Corps de l'os zygomatique (ligne innominée)

18- Arcade zygomatique

Radioanatomie

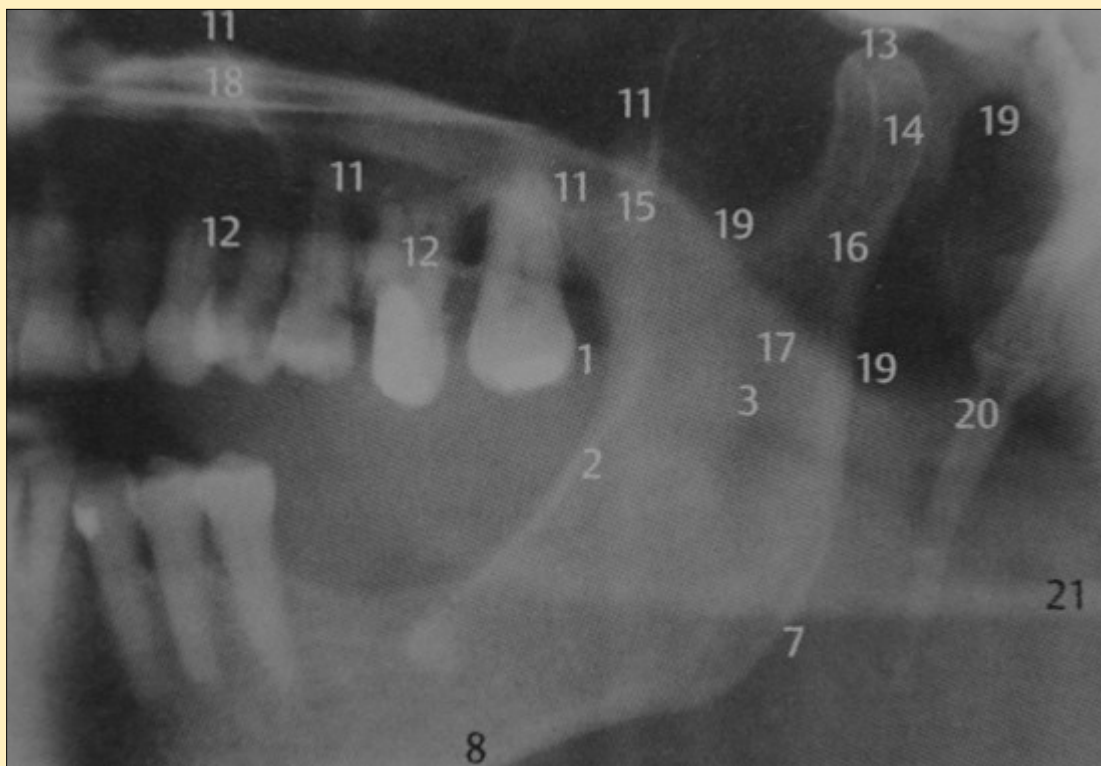
- Région mandibulaire



- 3- Bord basilaire (partie éloignée du film)
- 13- Arcade zygomatique
- 14- Bord basilaire
- 15- Ligne mylo-hyoïdienne
- 16- Canal mandibulaire
- 17- Foramen mentonnier
- 18- Fossette digastrique (ou mentonnière)
- 19- Oreille
- 20- Condyle mandibulaire
- 21- Processus coronoïde
- 23- Os hyoïde
- 24- Base de langue

Radioanatomie

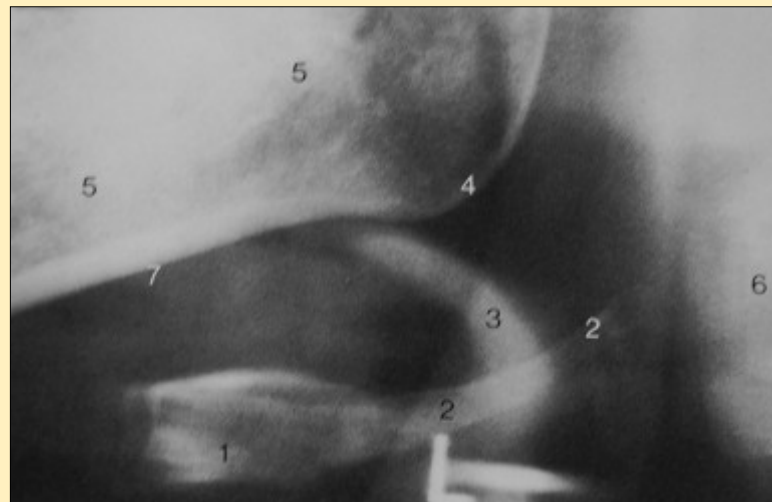
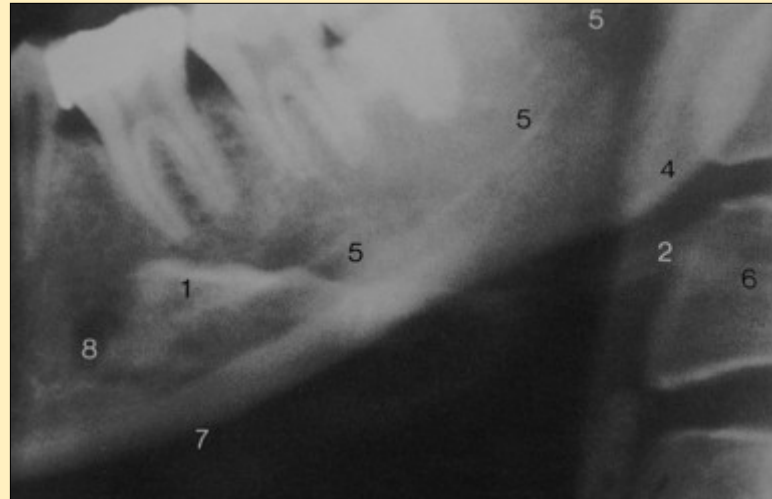
- Région rétro-maxillaire
ATM



- 1- Ligne oblique externe
- 2- Trigone rétro-molaire
- 3- Foramen mandibulaire
- 7- Angle mandibulaire
- 8- Bord basilaire
- 11- Sinus maxillaire
- 12- Dos de la langue
- 13- Espace articulaire
- 14- Condyle mandibulaire
- 15- Processus coronoïde, ptérygoïde, tubérosité max, voile du palais (superposition)
- 16- Col mandibulaire
- 17- Voile du palais
- 18- Voûte palatine + plancher cavités nasales
- 19- Naso-pharynx
- 20- Processus styloïde long et articulé
- 21- Bord basilaire mandibulaire controlatéral

Radioanatomie

- Région cervicale



- 1- Corps de l' os hyoïde
- 2- Grande corne de l' os hyoïde
- 3- Epiglotte
- 4- Angle mandibulaire
- 5- Canal mandibulaire
- 6- Colonne cervicale
- 7- Bord basilaire
- 8- Foramen mentonnier

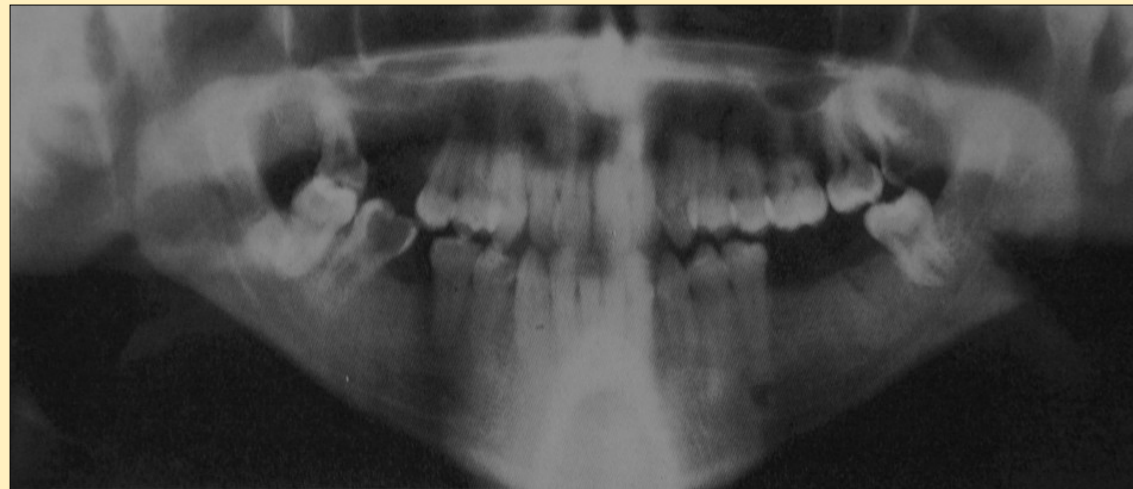Offre commerciale



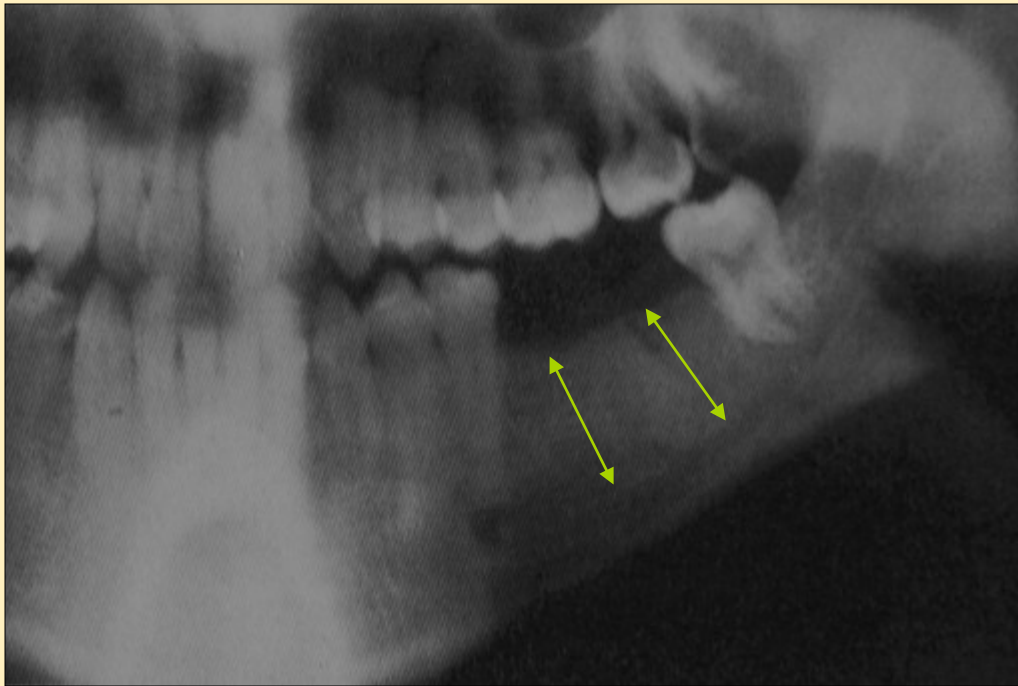
- ROTATION CIRCULAIRE
- NUMERIQUE
- CAPTEUR SOLIDE

PANO et IMPLANTOLOGIE

- Fiabilité des mesures
 - Cliché à l'échelle 1: numérique
 - Déformation des images

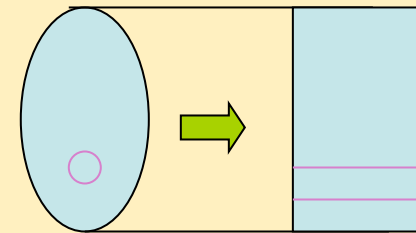
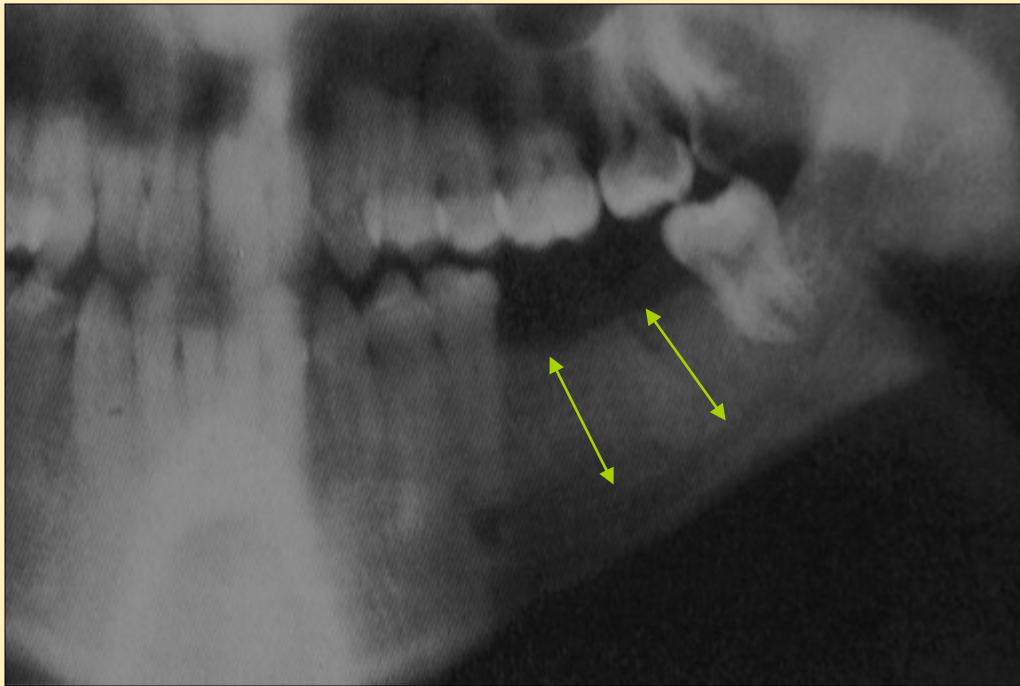


PANO et IMPLANTOLOGIE

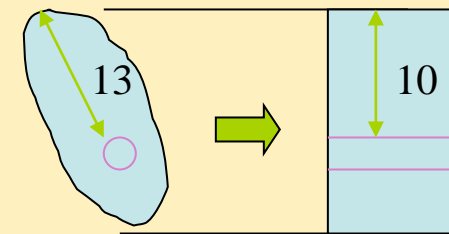
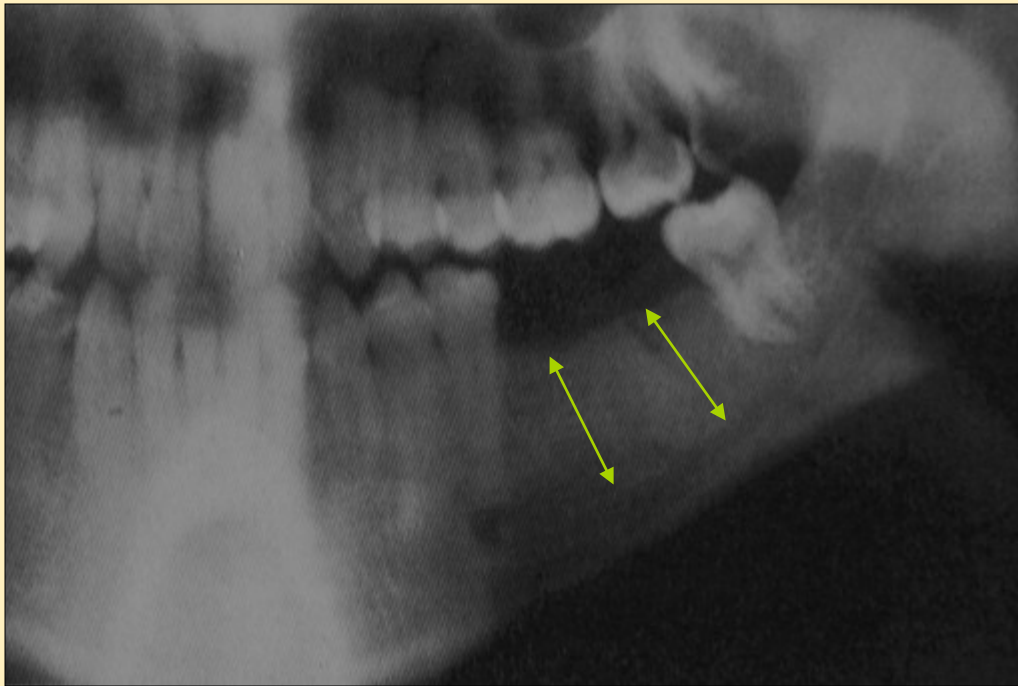


- Mesure directe sur le cliché

PANO et IMPLANTOLOGIE



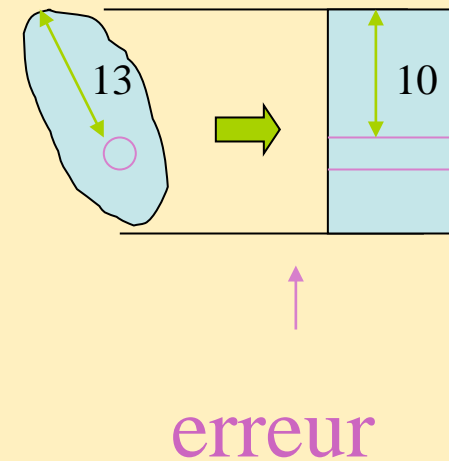
PANO et IMPLANTOLOGIE



erreur

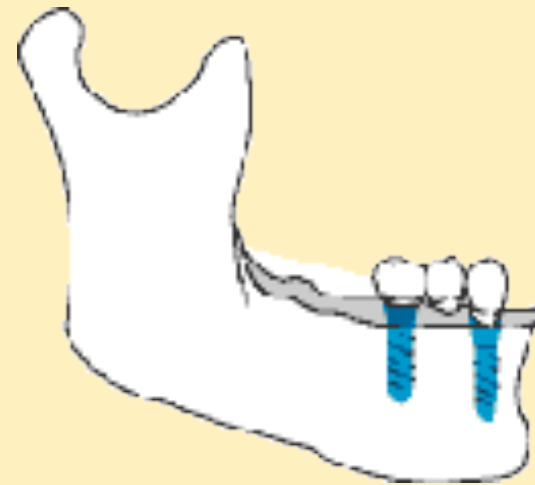
PANO et IMPLANTOLOGIE

- Erreur due à la morphologie maxillaire
- Erreur due à la position du patient



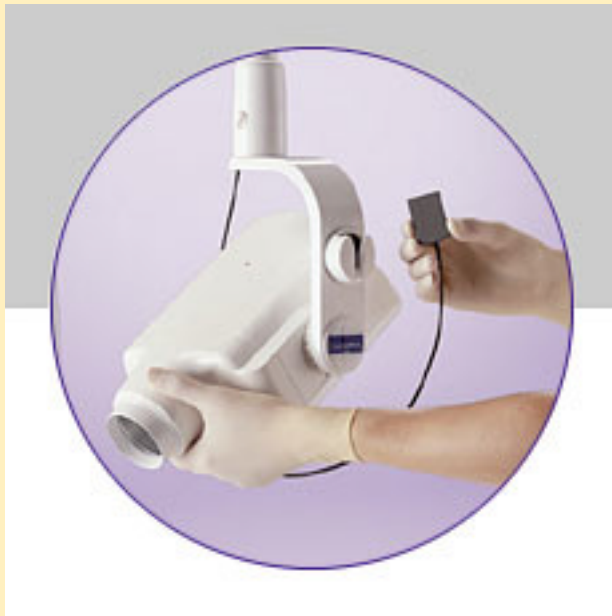
PANO et IMPLANTOLOGIE

- Etude dans un seul plan
- Nécessité d' un outil tri-dimensionnel



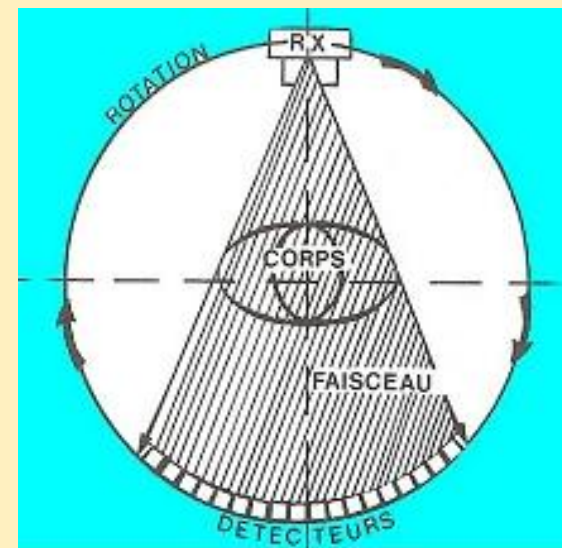
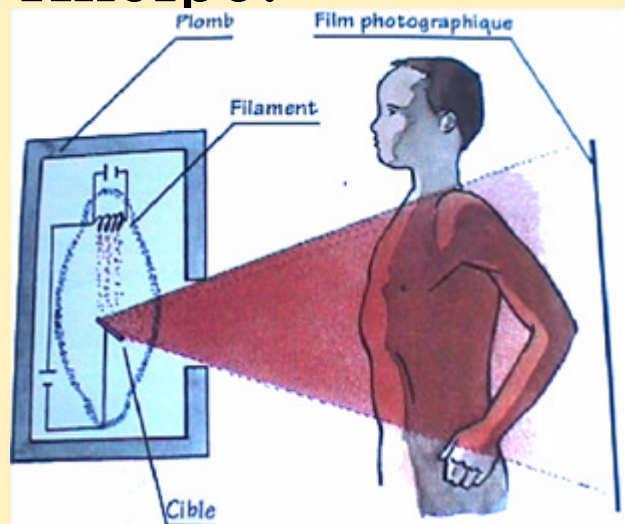
Autres modalités de radiologie conventionnelle

- Clichés endo-buccaux: numérisisation.
- Pas d'intérêt pratique en implantologie


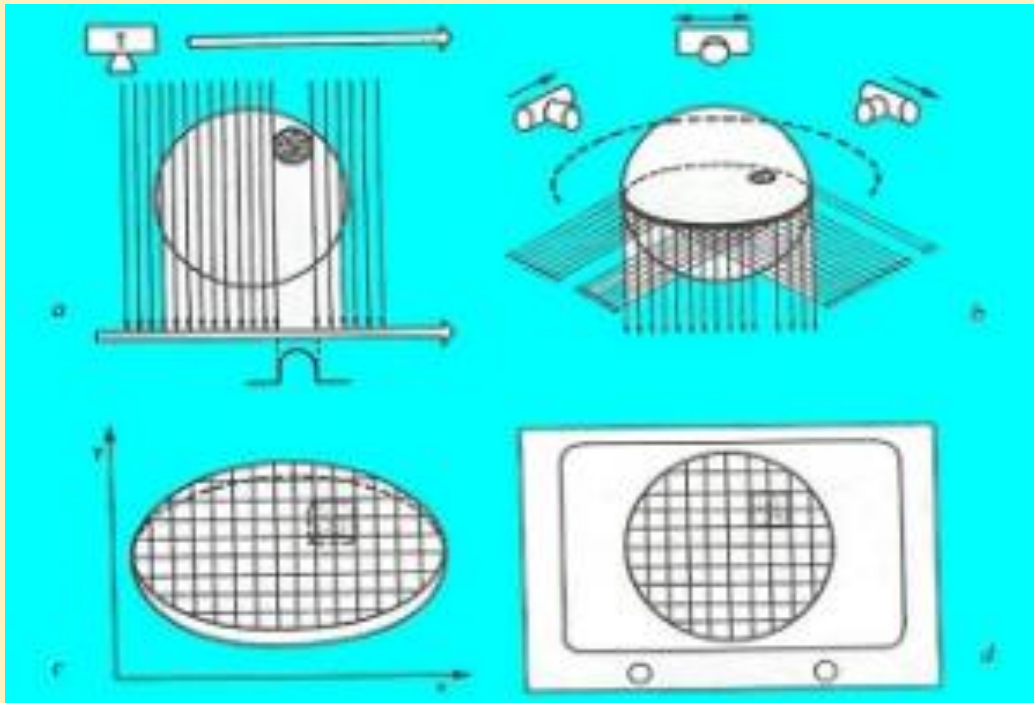


LE SCANNER

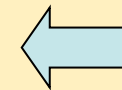

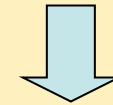
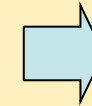
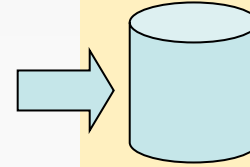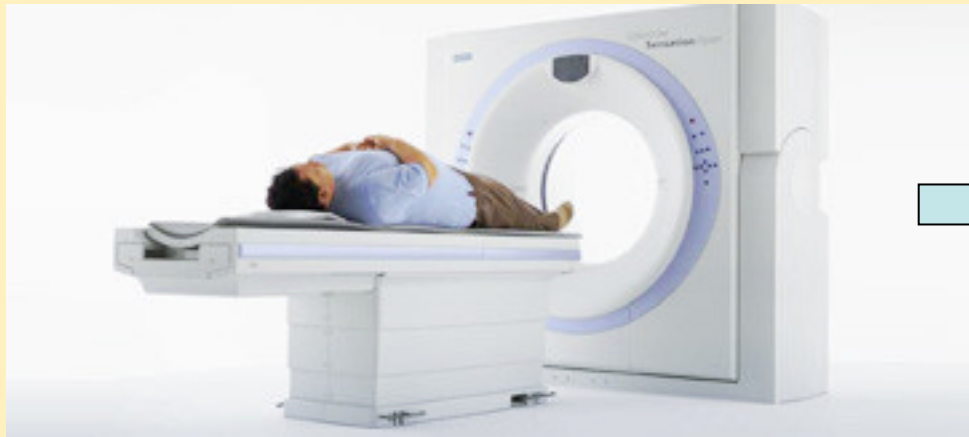
- Tomodensitométrie/ CT
- Principe:



LE SCANNER

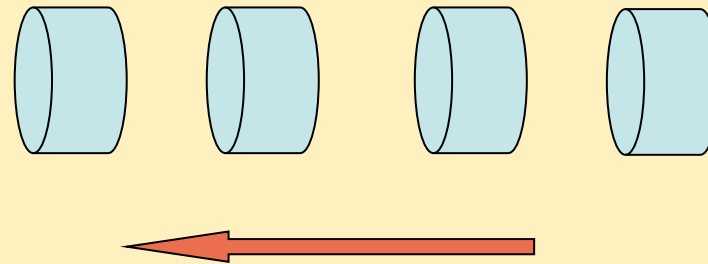
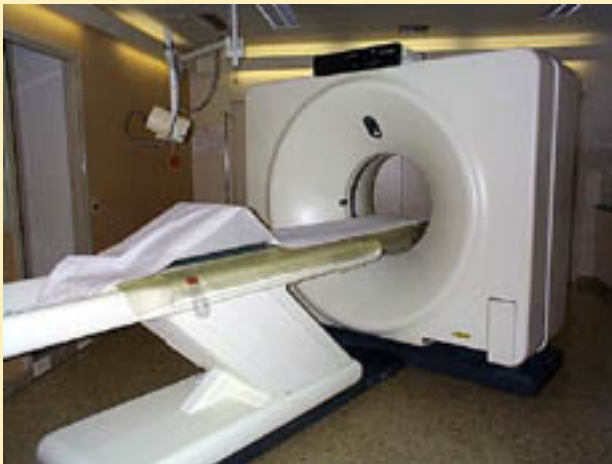

LE SCANNER



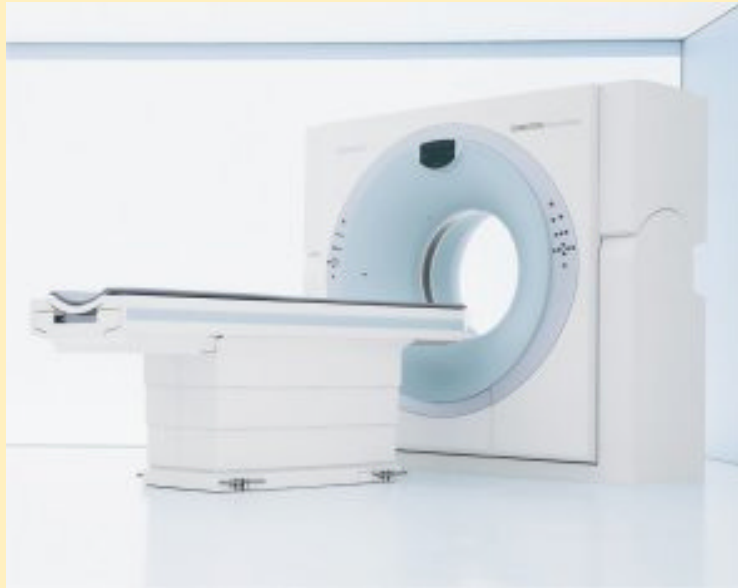
- Films
- CD
- réseau

LE SCANNER



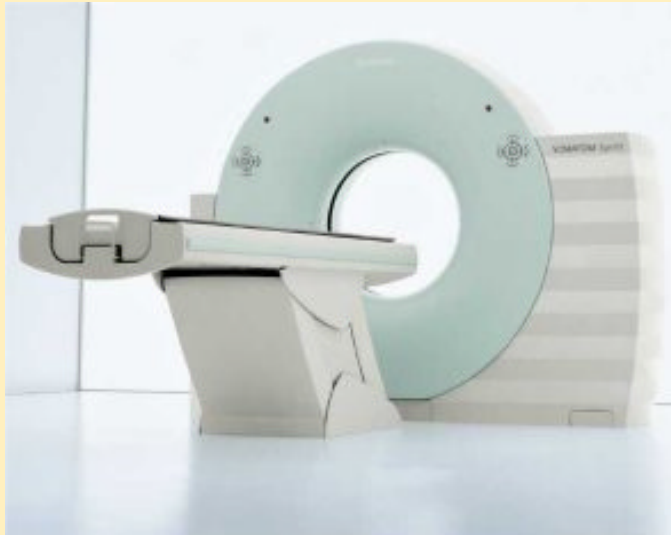
SCANNER SEQUENTIEL
(1980_1990)

LE SCANNER



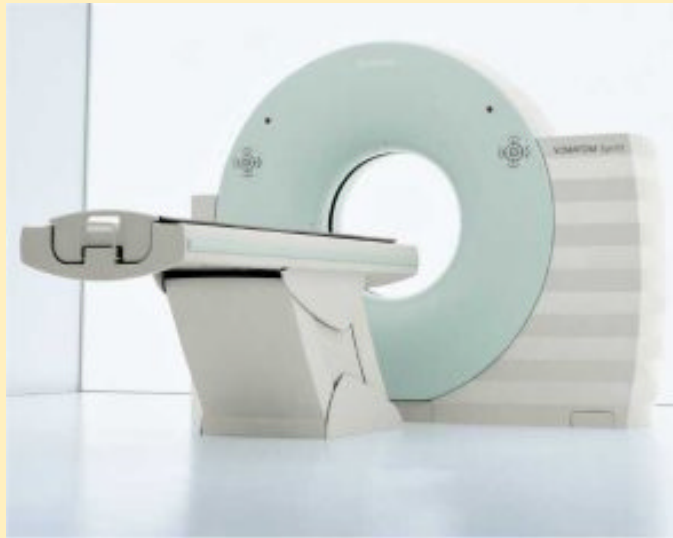

SCANNER SPIRALE
(1990-2000)

LE SCANNER



SCANNER MULTICOUPES
(2000-2007)

LE SCANNER MULTICOUPES



DETECTEURS MULTIPLES

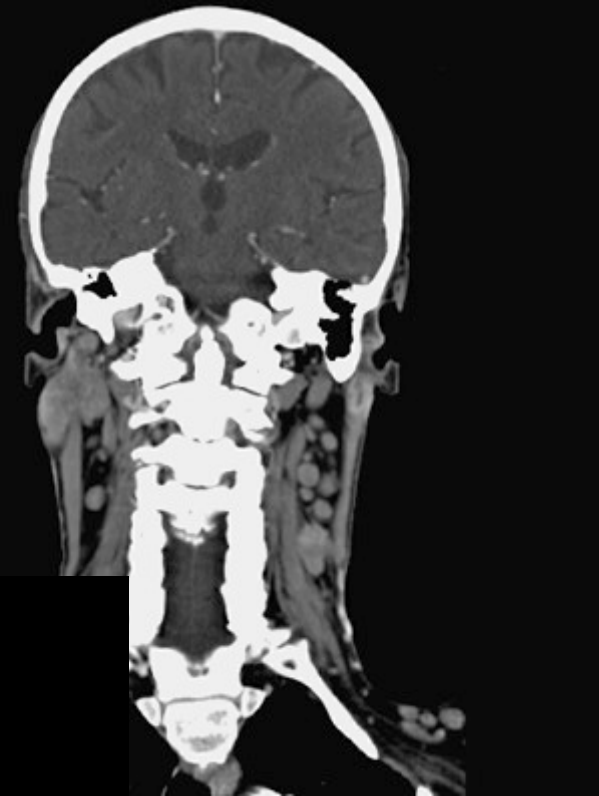
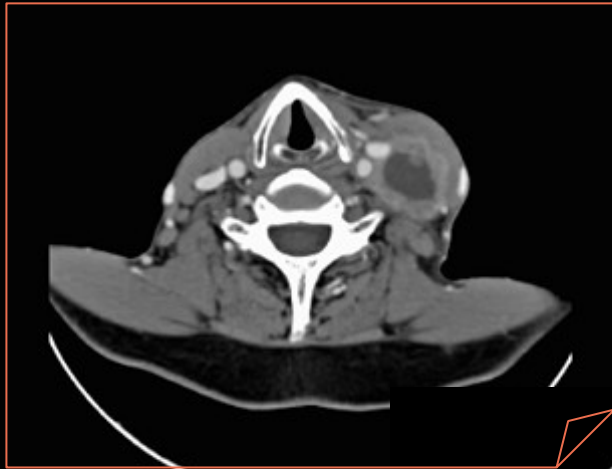
(2 à 64... 256 ?)

LE SCANNER MULTICOUPES

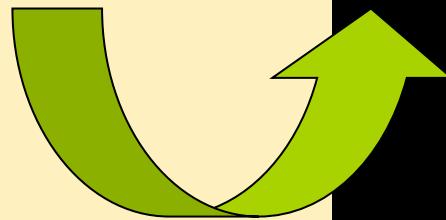


- ACQUISITION VOLUMIQUE
- LOGICIELS DE RECONSTRUCTION

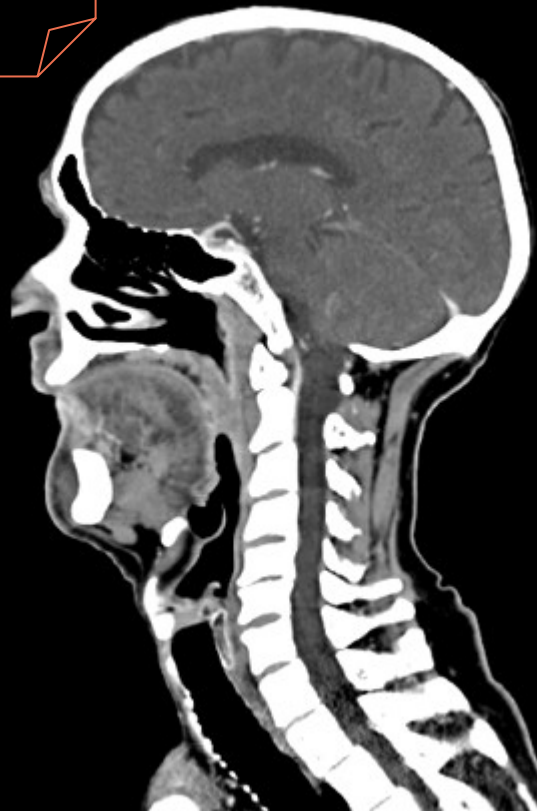Rec. axiale



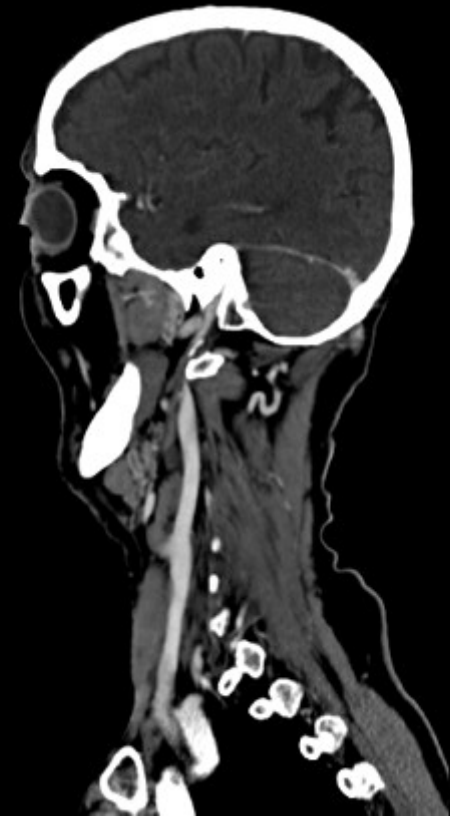
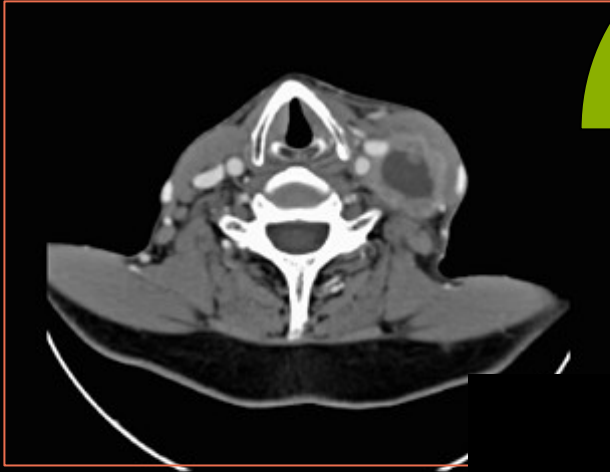Rec. Coronale



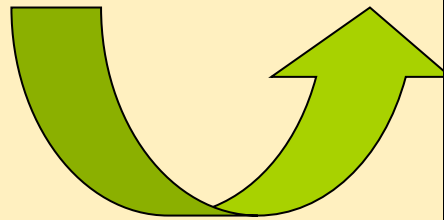
Rec. sagittale



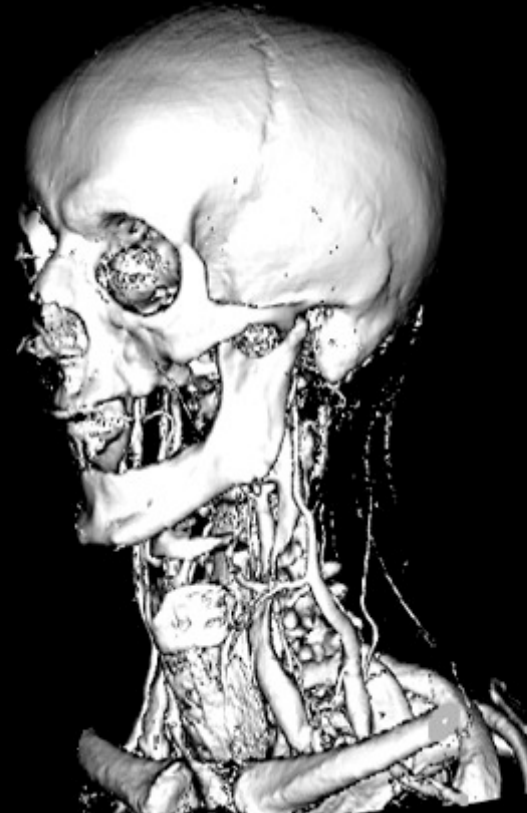
Coupe axiale



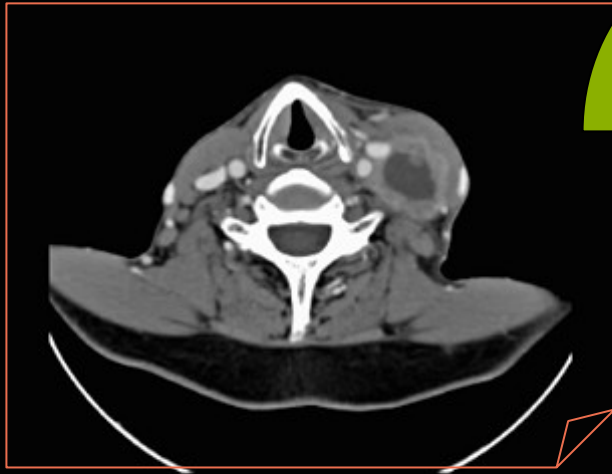Rec. MIP



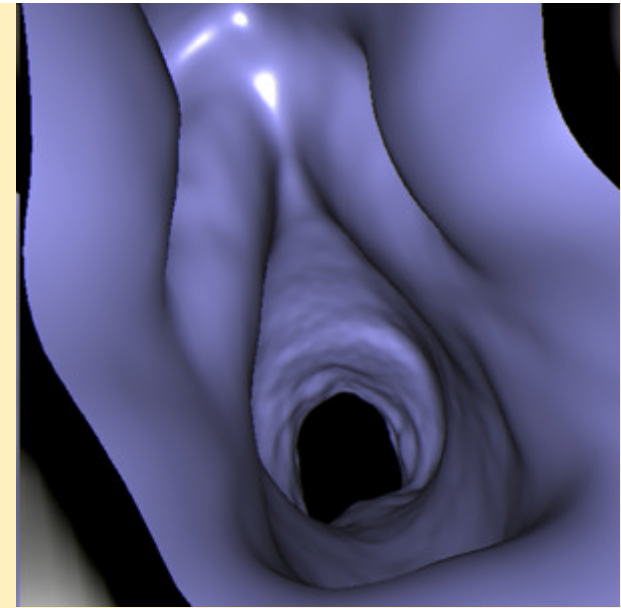
Rec. 3D



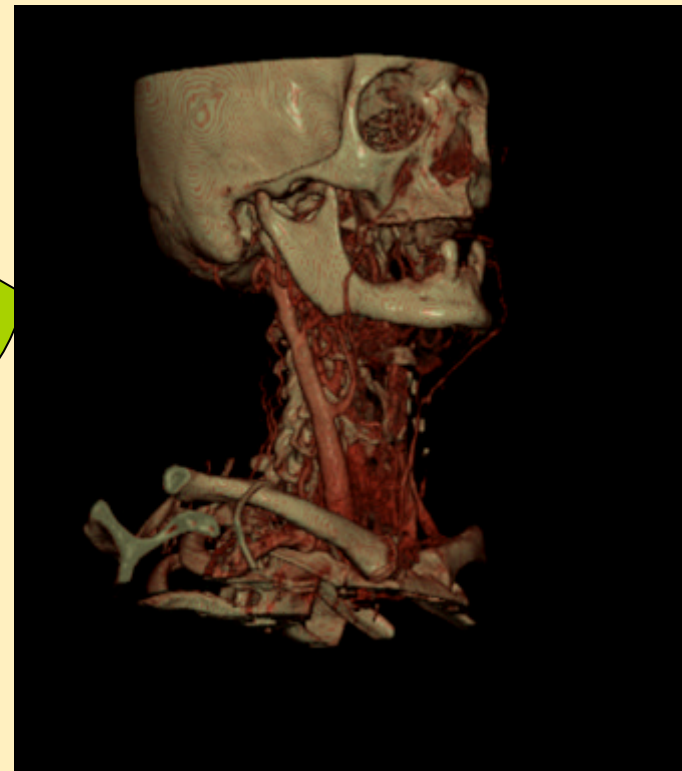
Coupe axiale




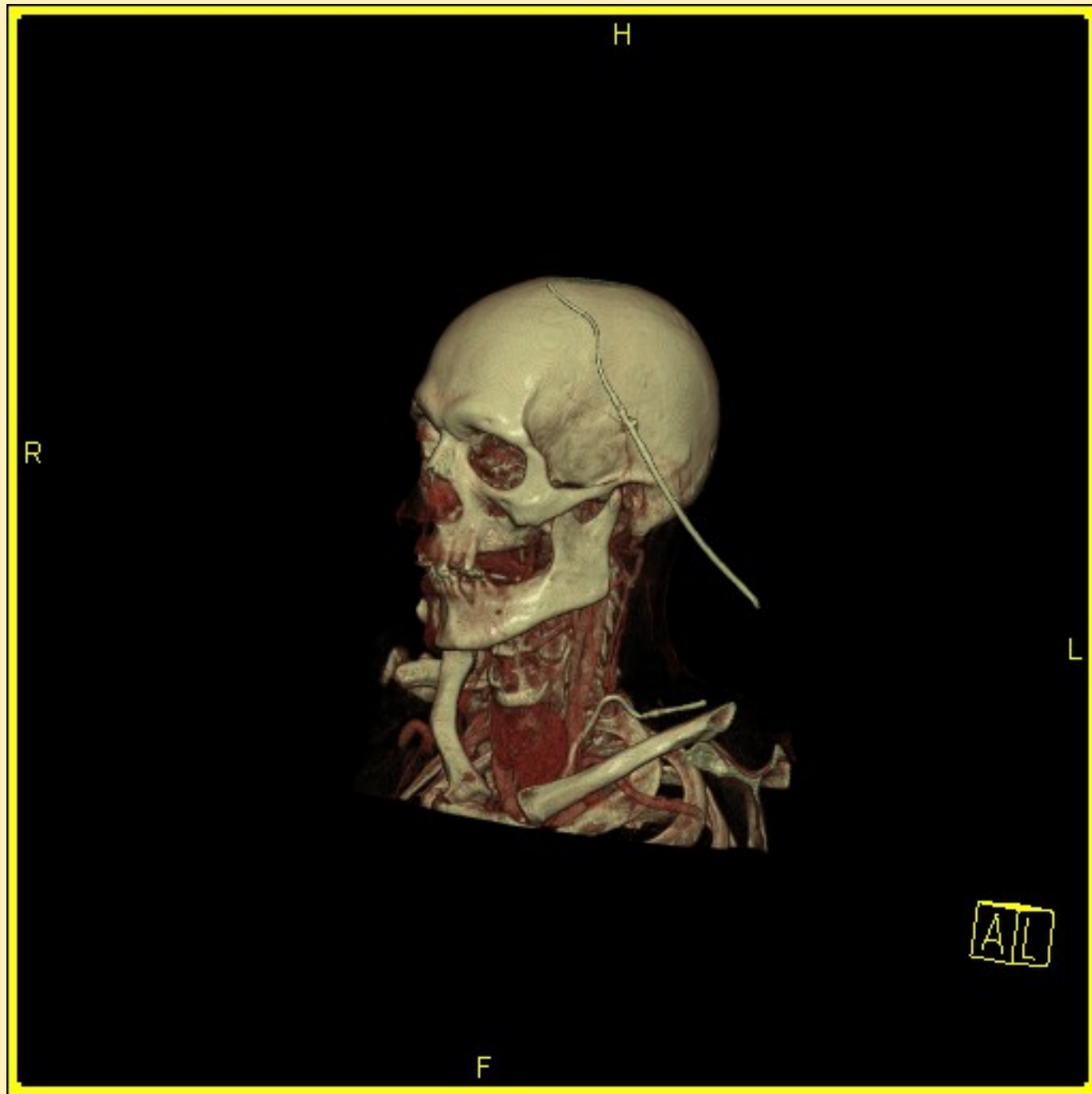
E.V.

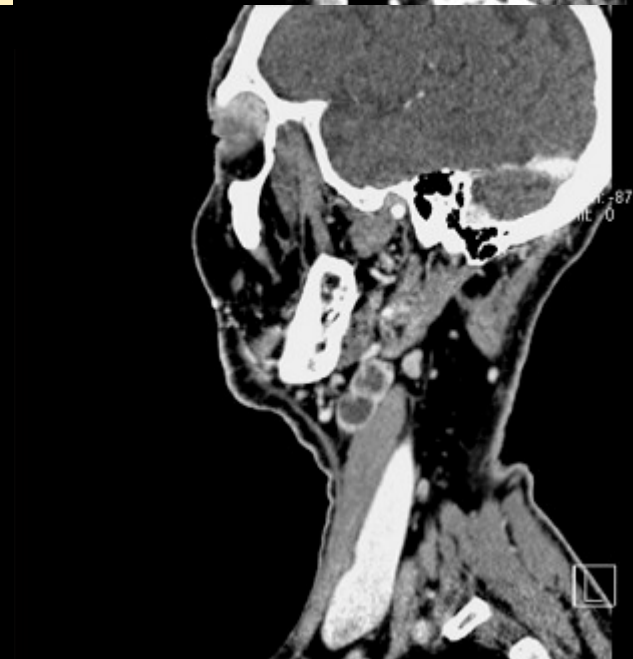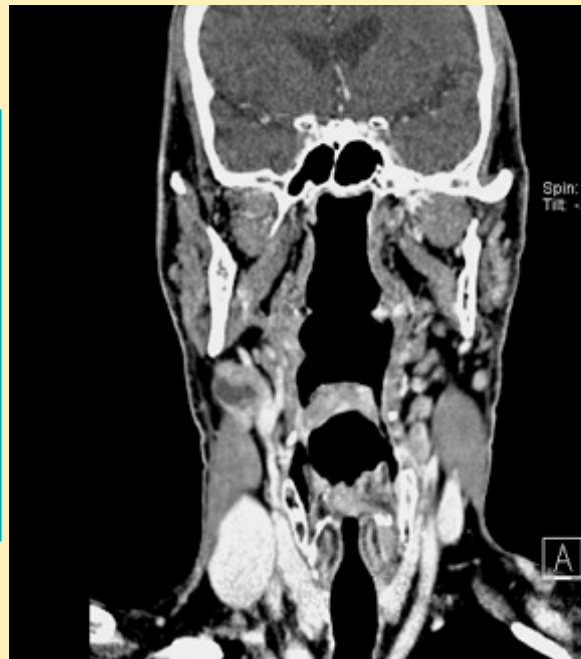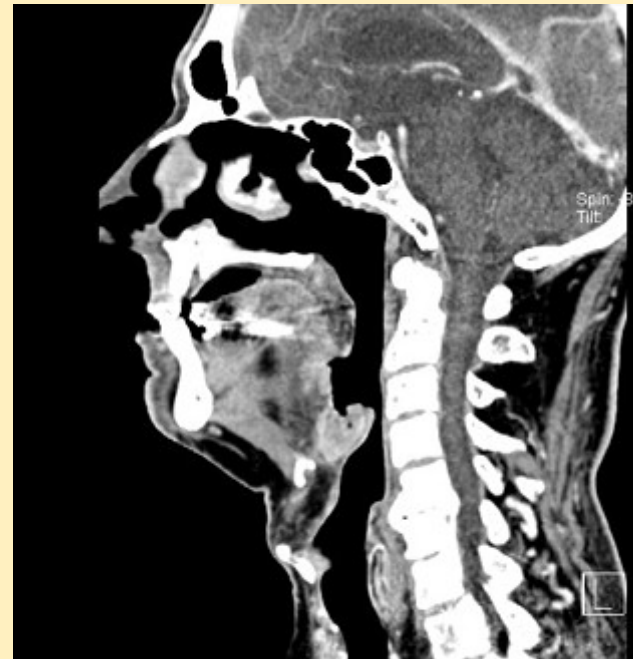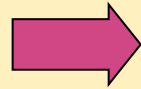
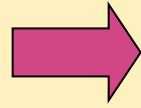
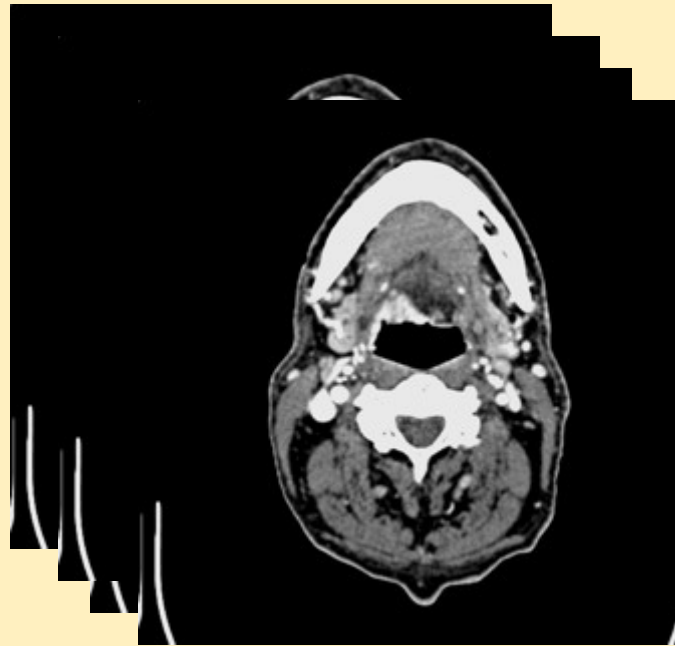


Reconstructions 3D
Multi-tissus.





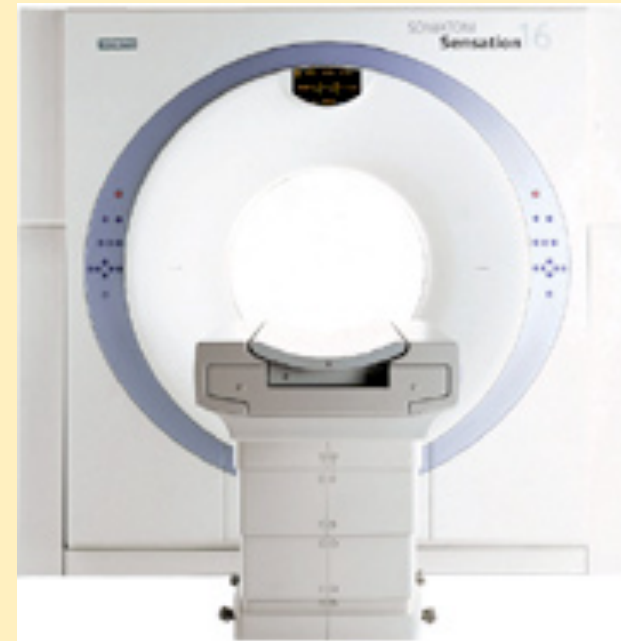



**SCANNER
=
MULTIPLAN**

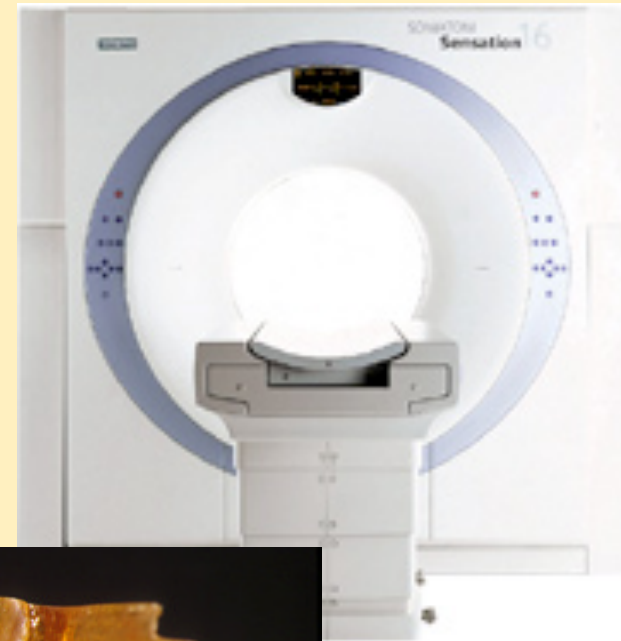
SUPPORT

- FILMS RADIO
- BANDES VIDEO
- PAPIER
- RESEAUX
- CD +++



SUPPORT

- FILMS RADIO
- BANDES VIDEO
- PAPIER
- RESEAUX
- CD +++
- **PROTOTYPAGE**



Intérêt du SCANNER en pathologie DENTAIRE

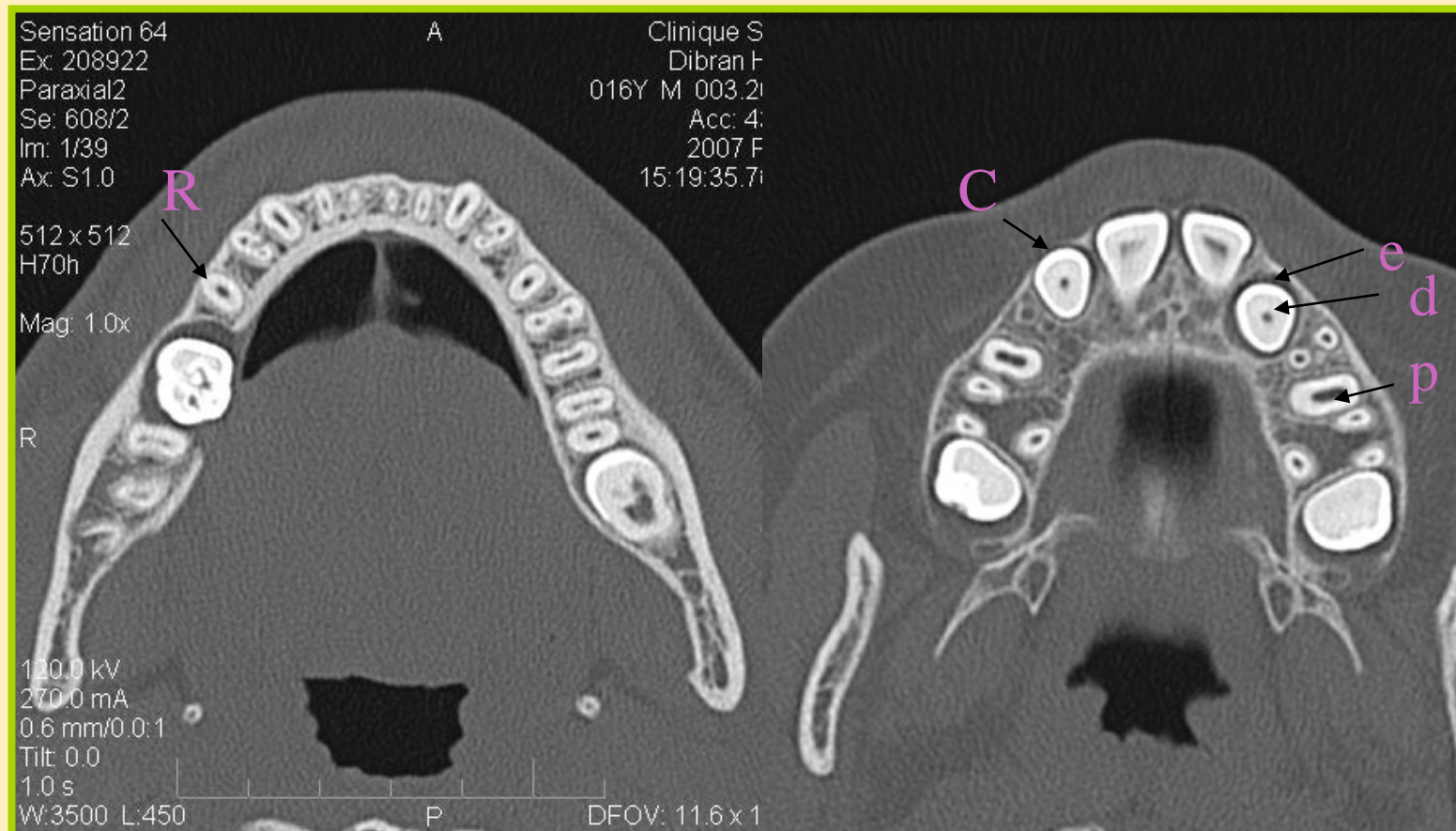- CONTRAINTES:**

- Coupes fines car structures de petite taille
- Bonne résolution spatiale
- Examen rapide (mouvements)
- Limiter l' irradiation (pathologie bénigne).

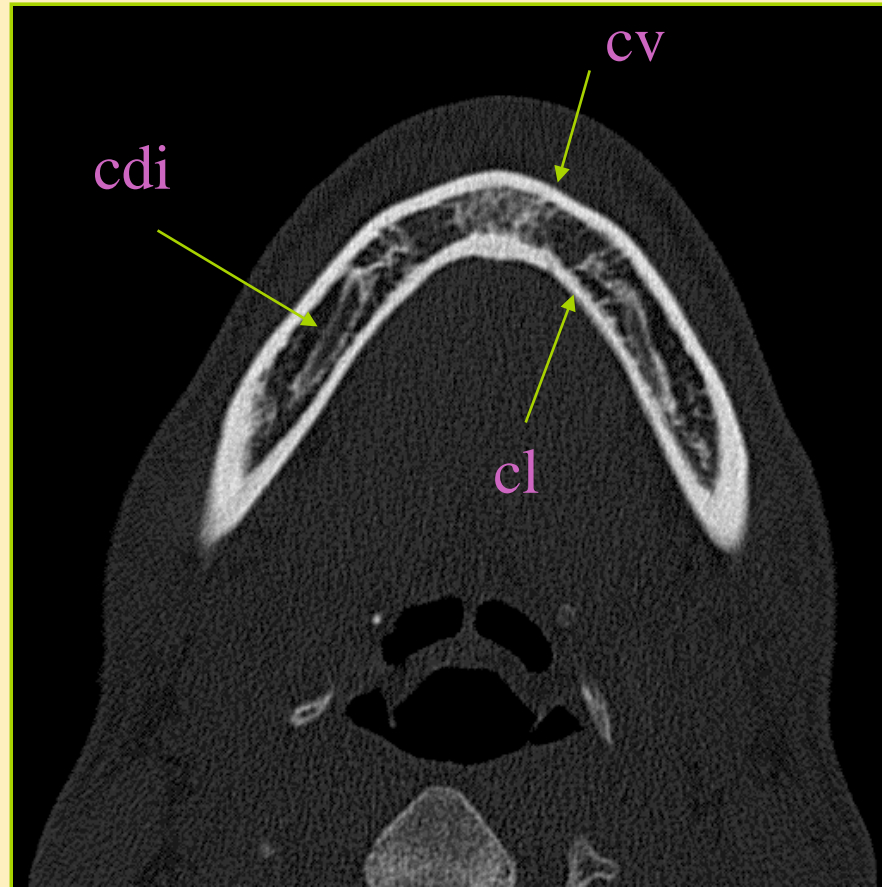
Intéret du SCANNER en pathologie DENTAIRE

- **RESULTATS (exemple scanner Siemens 128 coupes)**
 - Coupes de 0,3 mm
 - Reconstructions axiales/0,2mm
 - Petit champ (100 mm)
 - Rapide: 7,6 sec (env.120 coupes).

Intéret du SCANNER en pathologie DENTAIRE



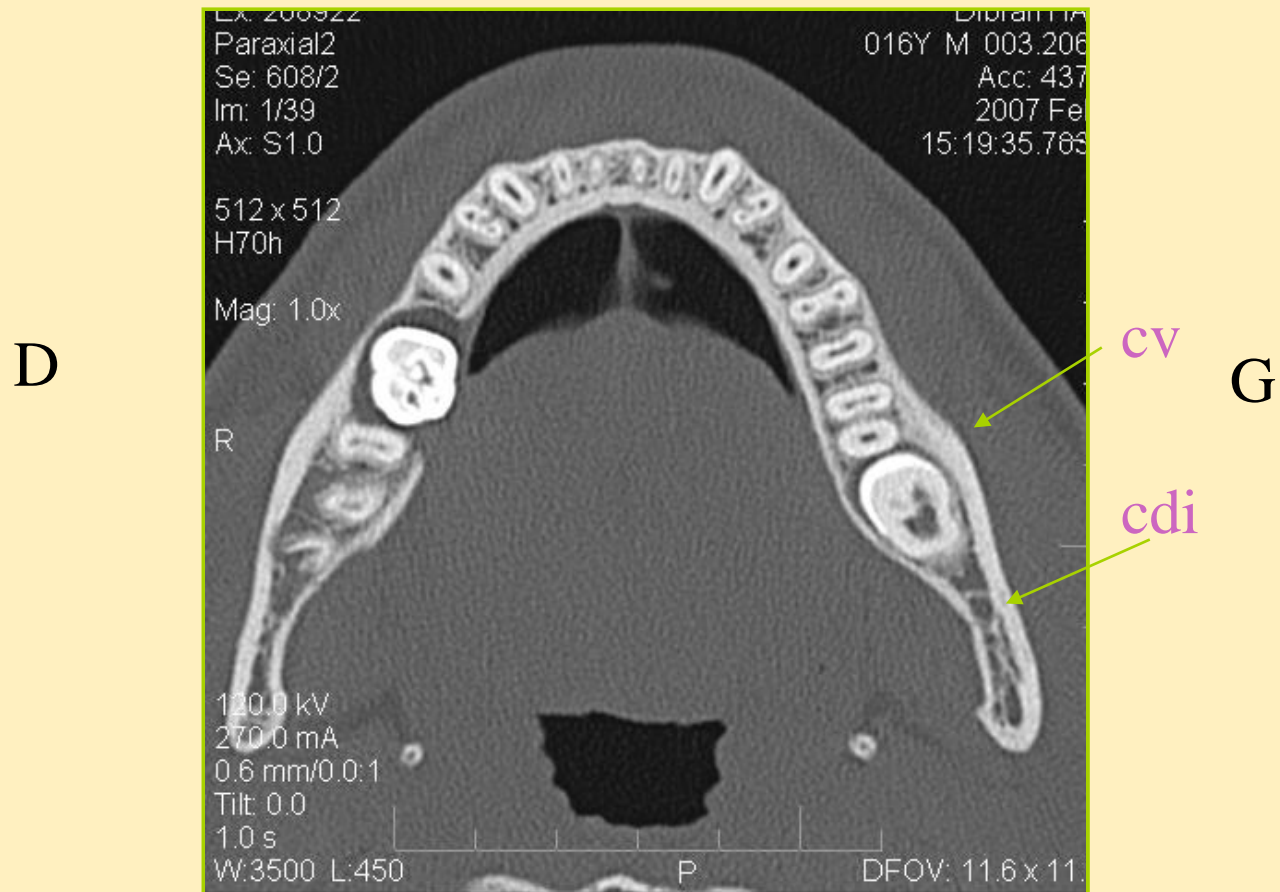
Intérêt du SCANNER en pathologie DENTAIRE



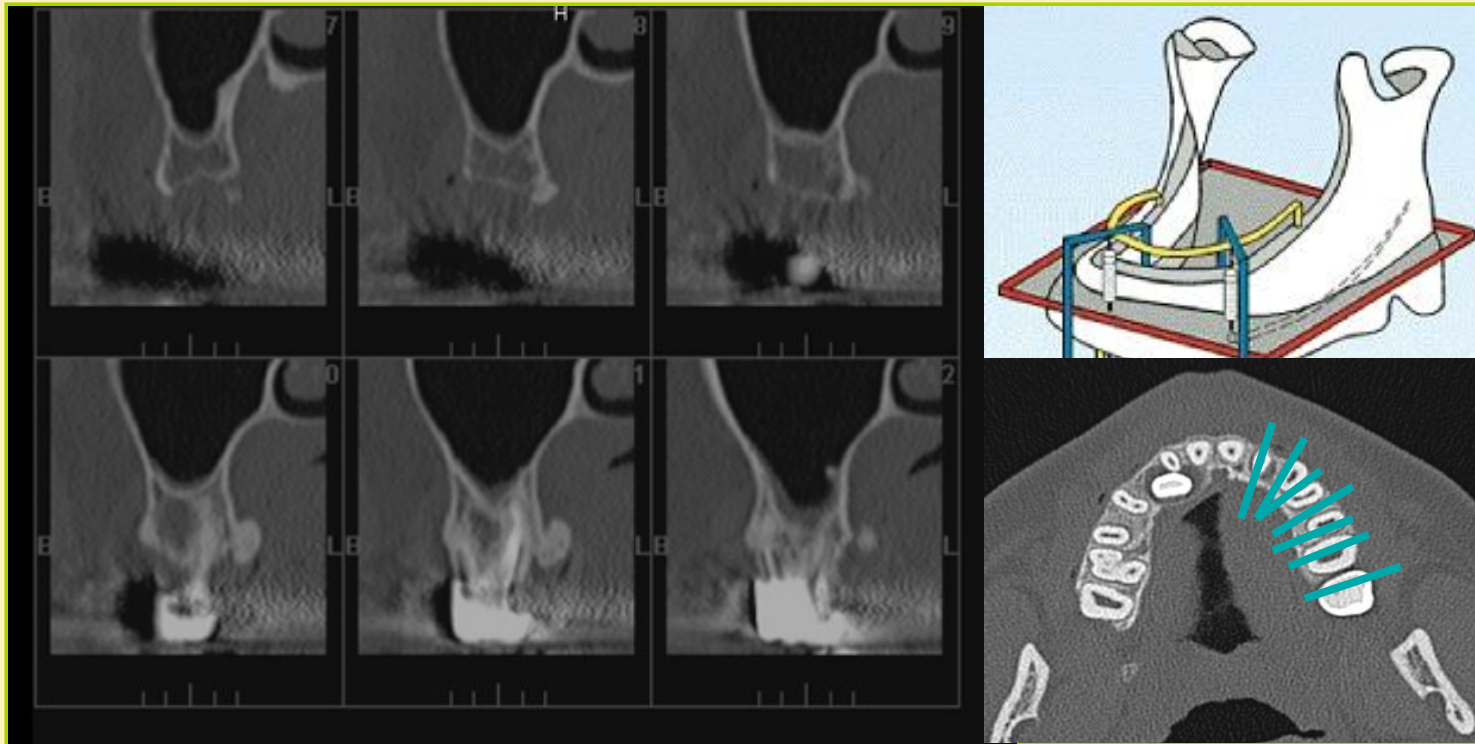
D

G

Intérêt du SCANNER en pathologie DENTAIRE

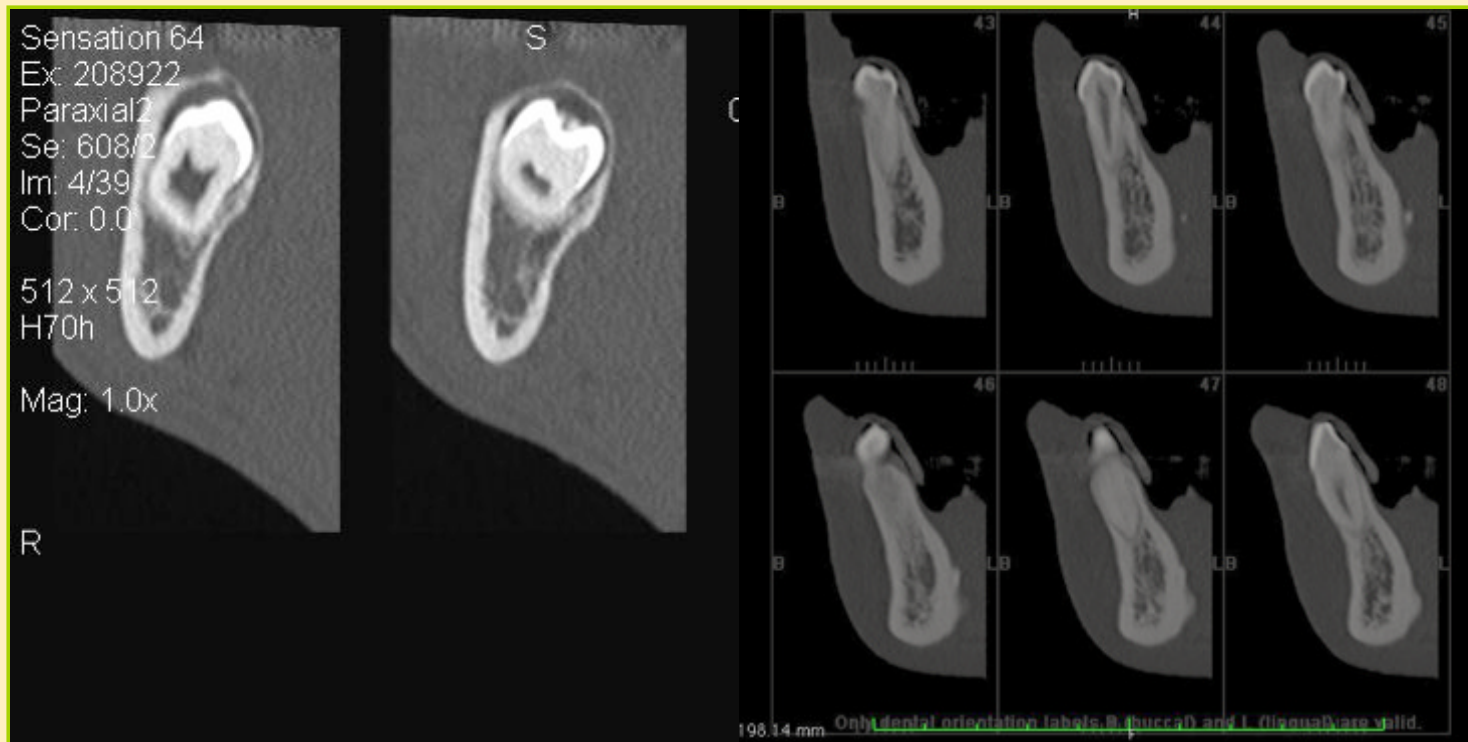


TRAITEMENT D' IMAGE



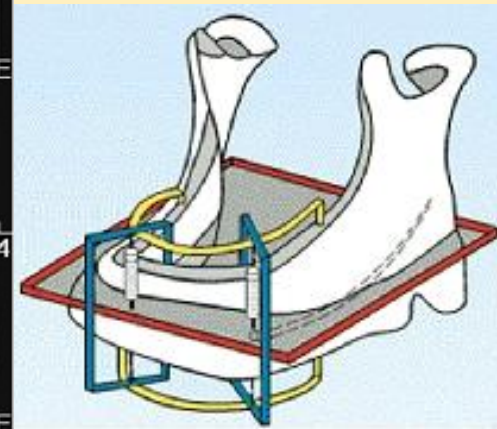
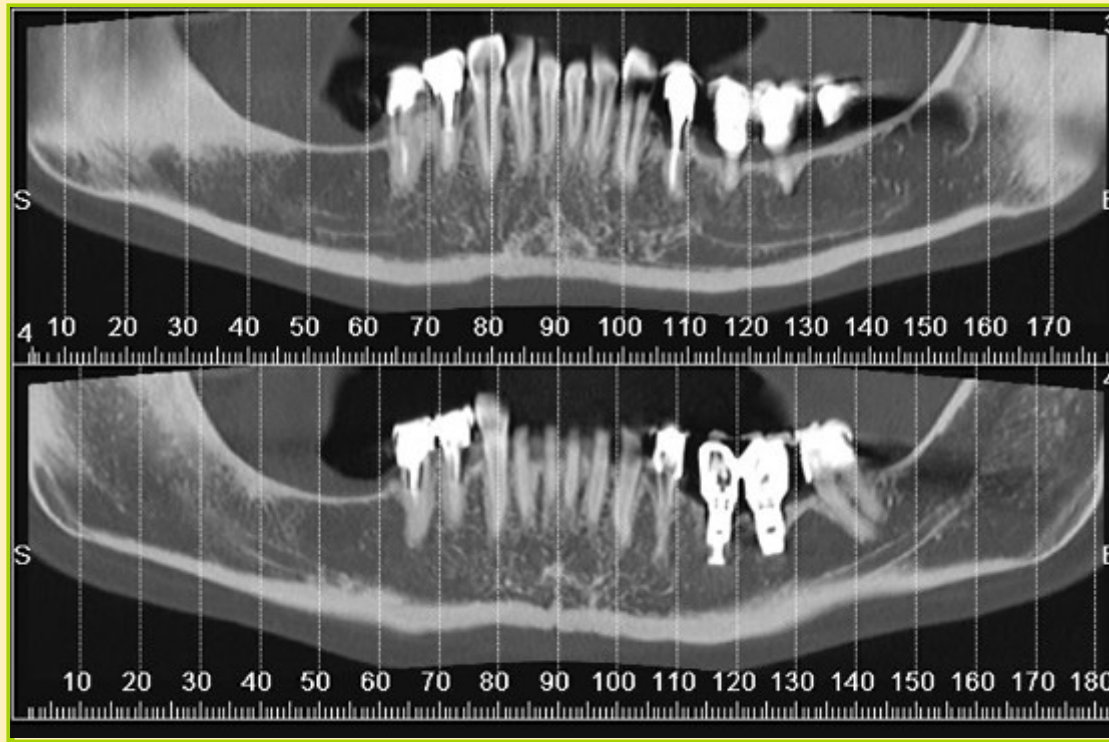
1°) Reconstructions para-axiales

TRAITEMENT D' IMAGE



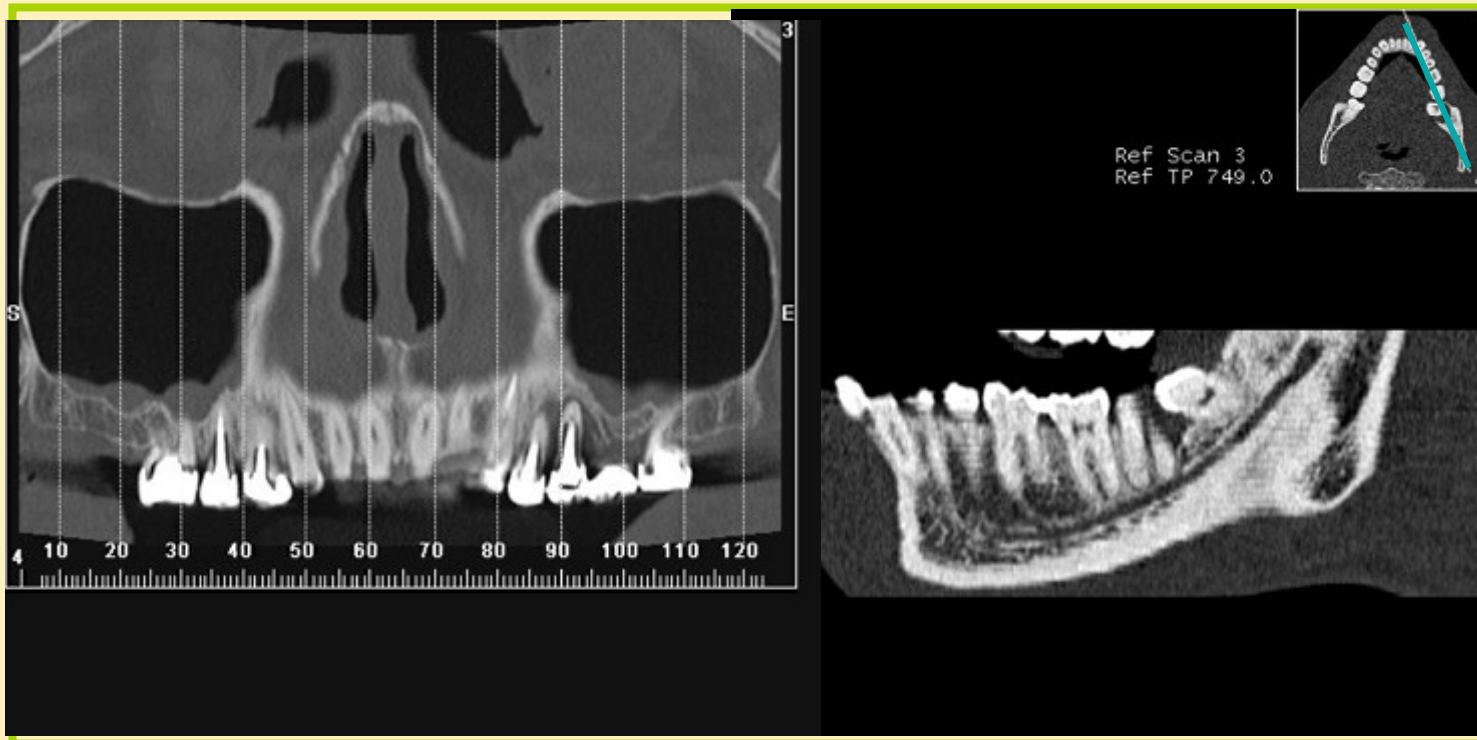
1°) Reconstructions para-axiales

TRAITEMENT D' IMAGE



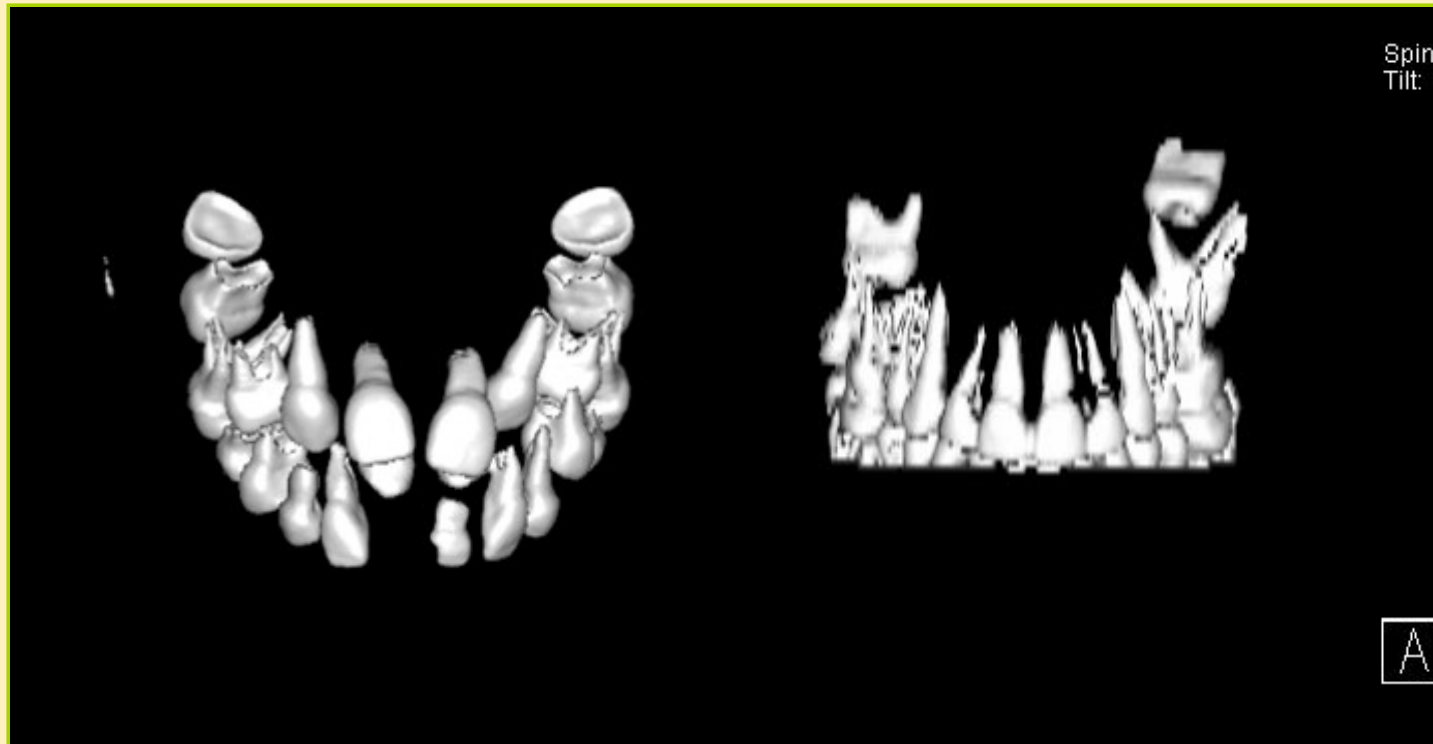
2°) Reconstructions PANORAMIQUES

TRAITEMENT D' IMAGE



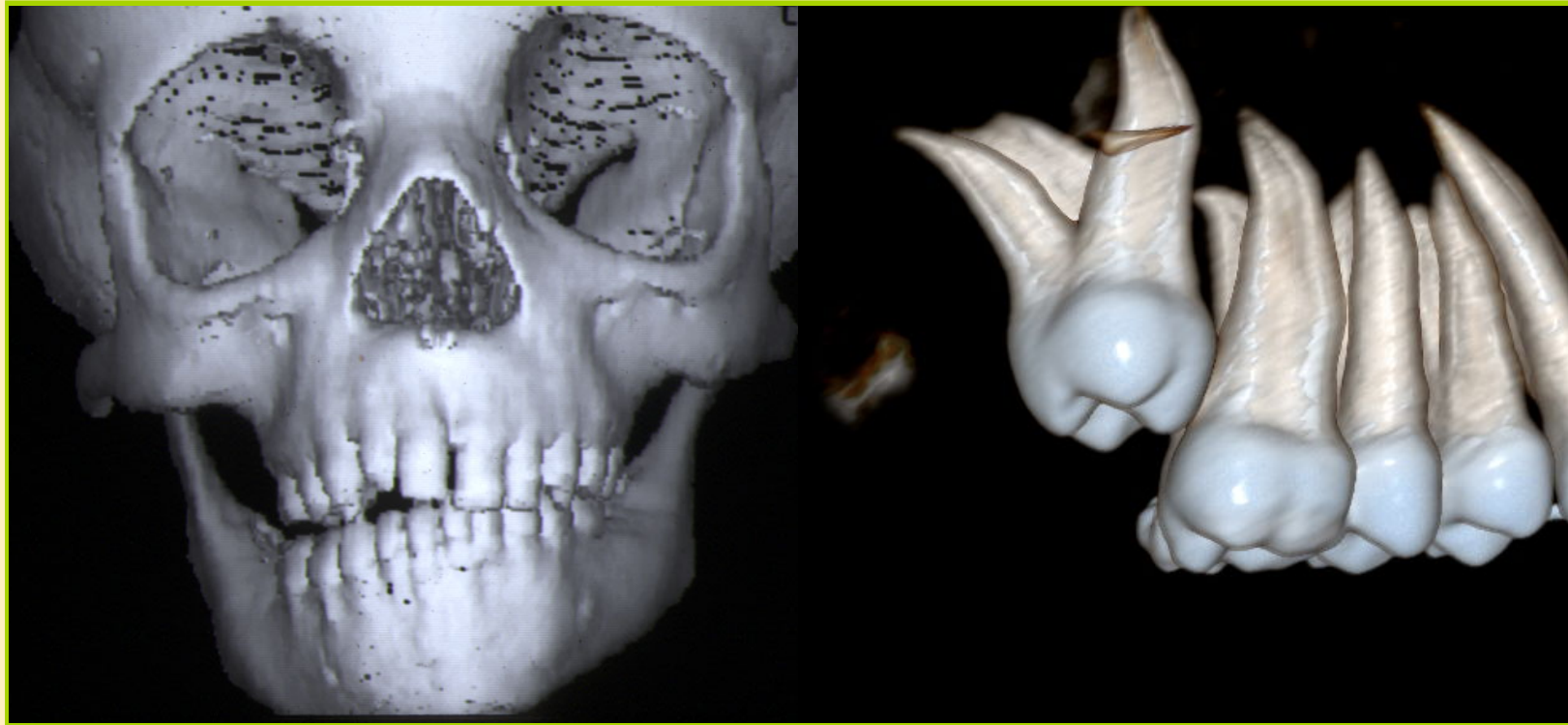
3°) Reconstructions OBLIQUES/COURBES

TRAITEMENT D' IMAGE



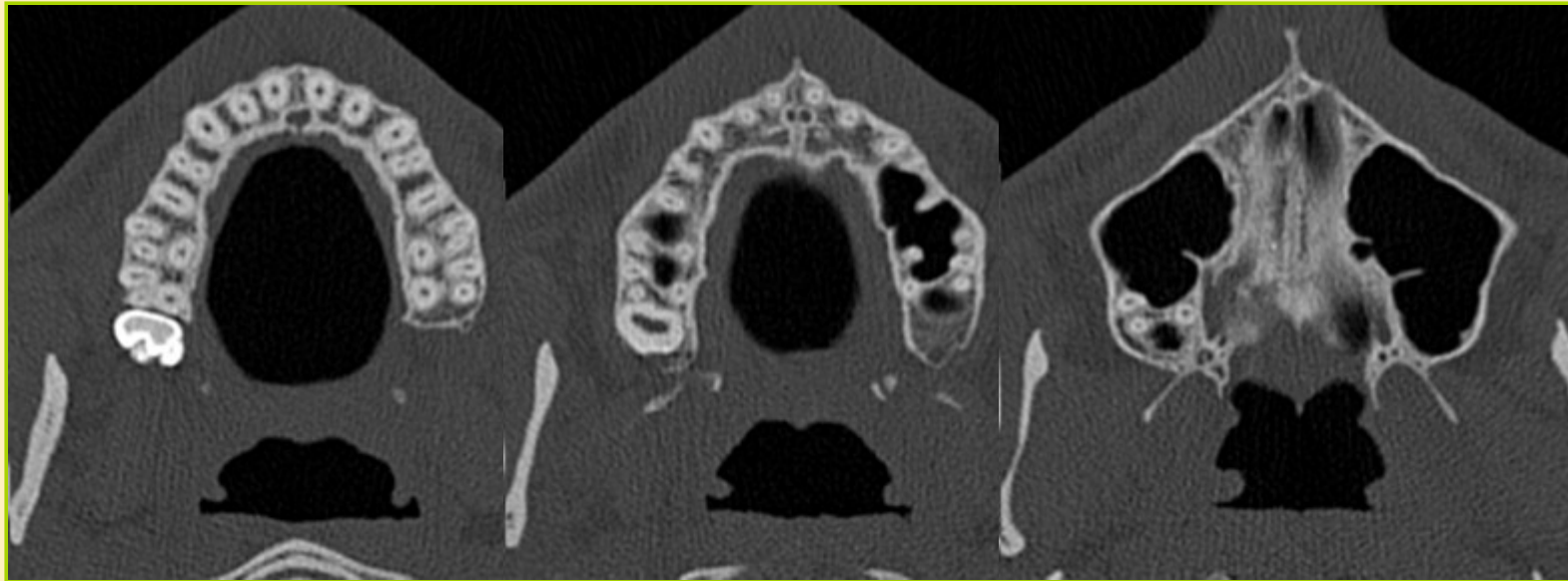
4°) Reconstructions 3D

TRAITEMENT D' IMAGE



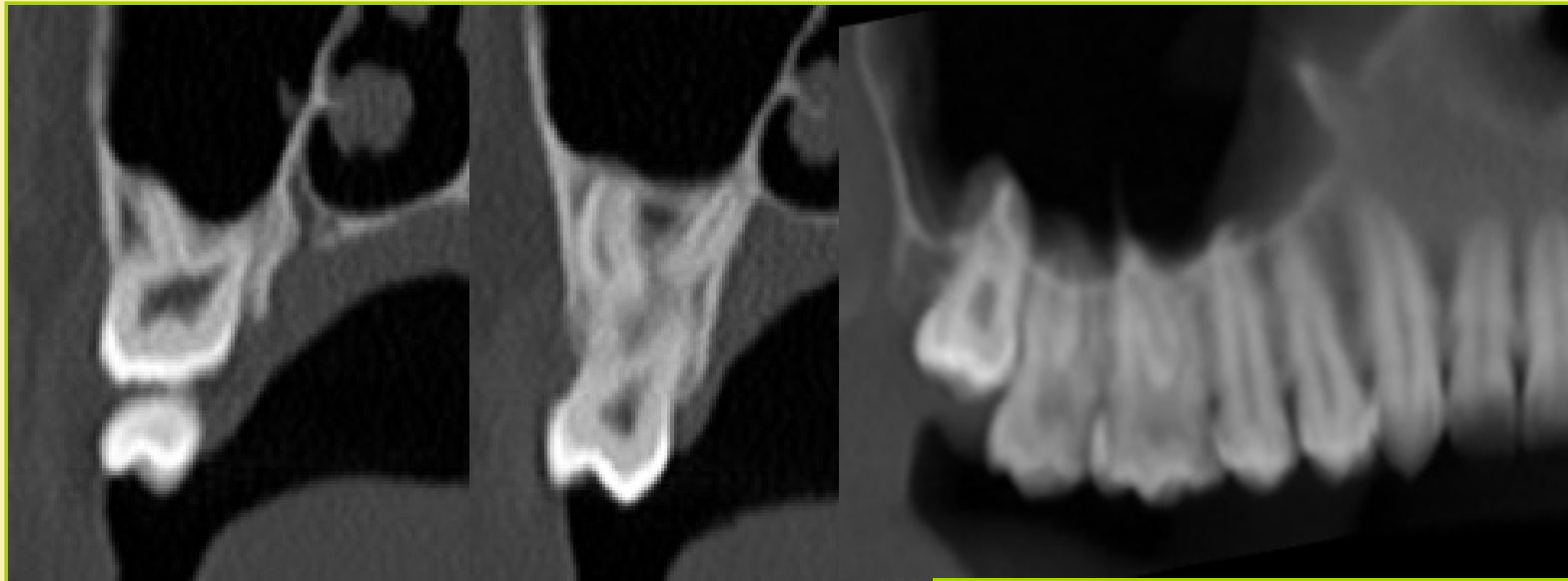
4°) Reconstructions 3D

DENTS INCLUSES



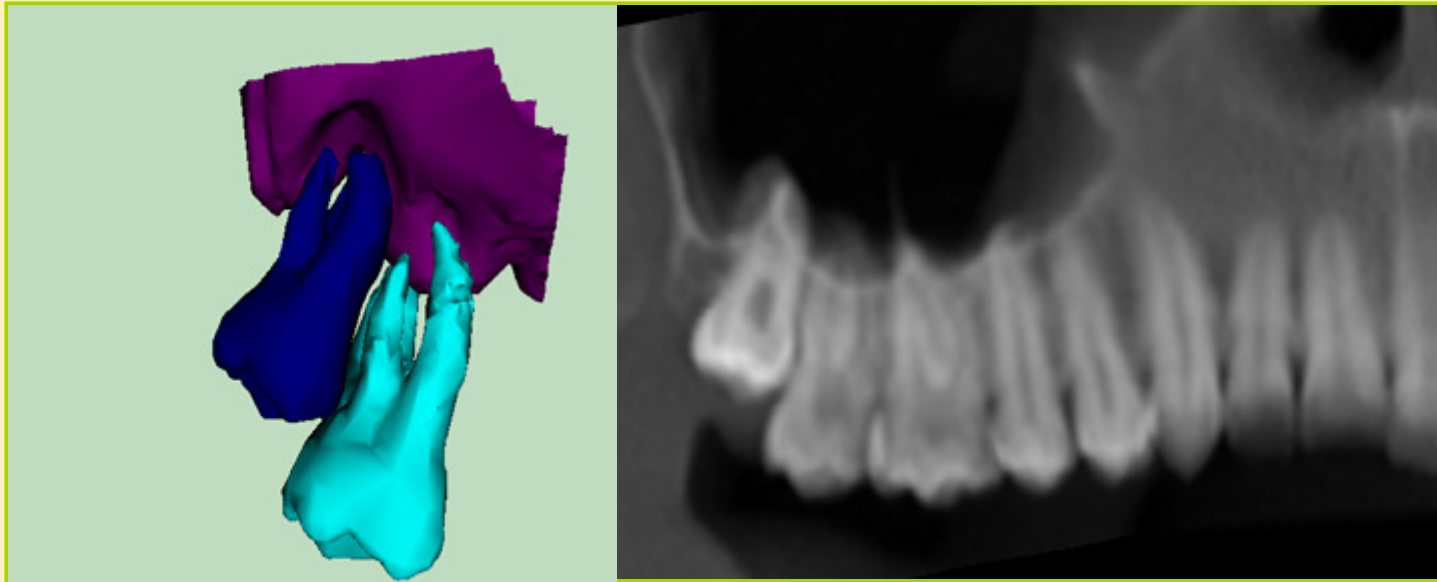
MOLAIRES et SINUS ?

DENTS INCLUSES



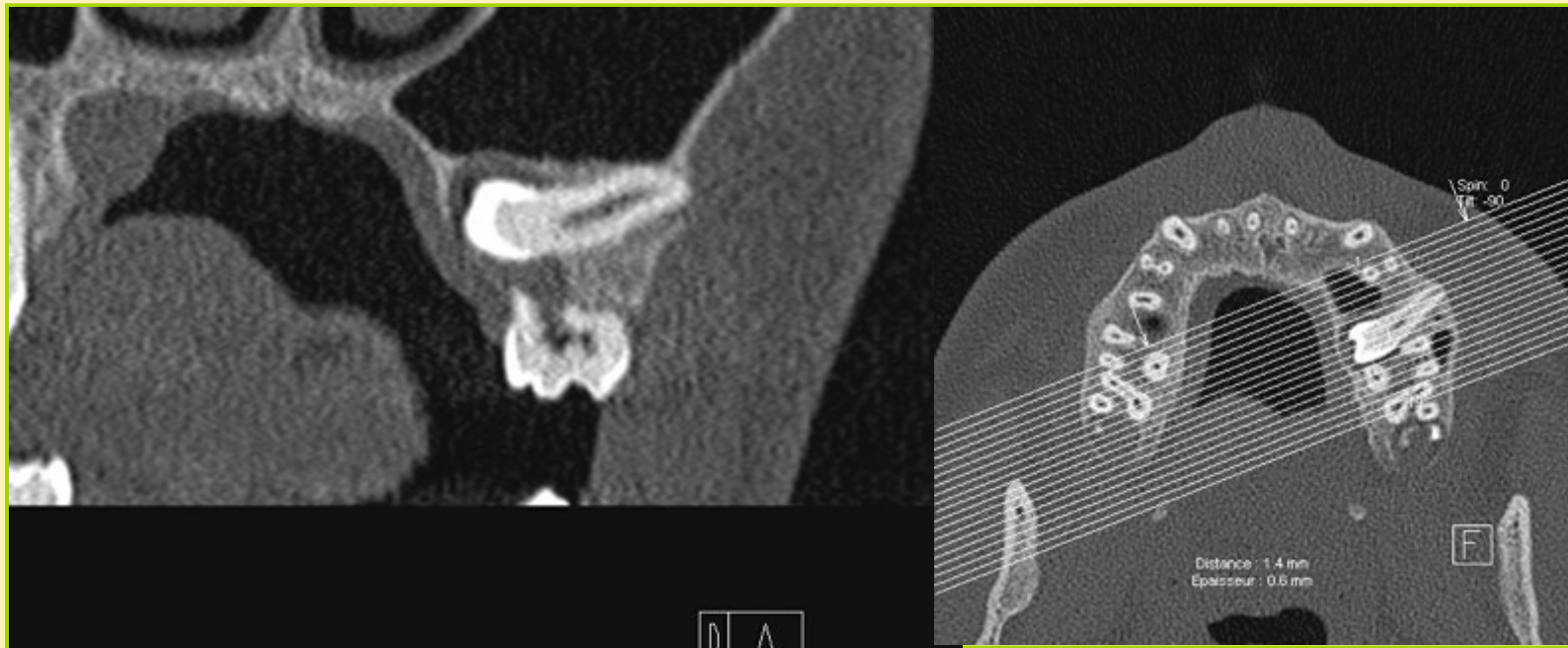
MOLAIRES et SINUS ?

DENTS INCLUSES

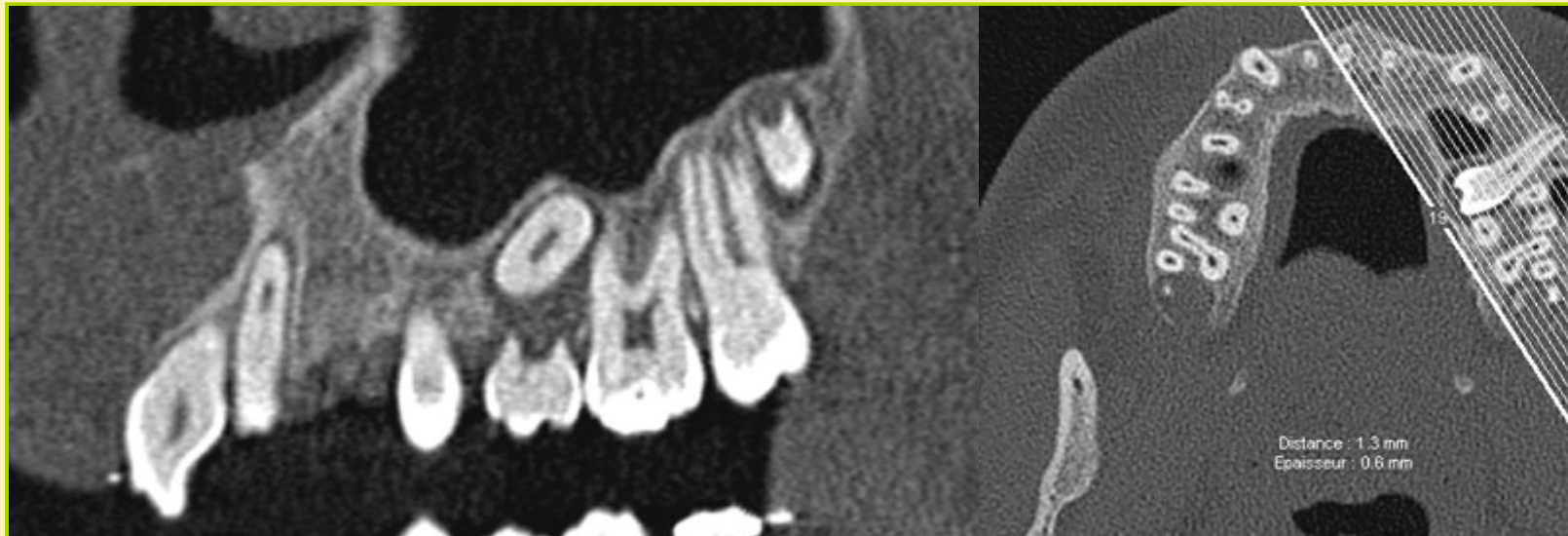

MOLAIRES et SINUS ?

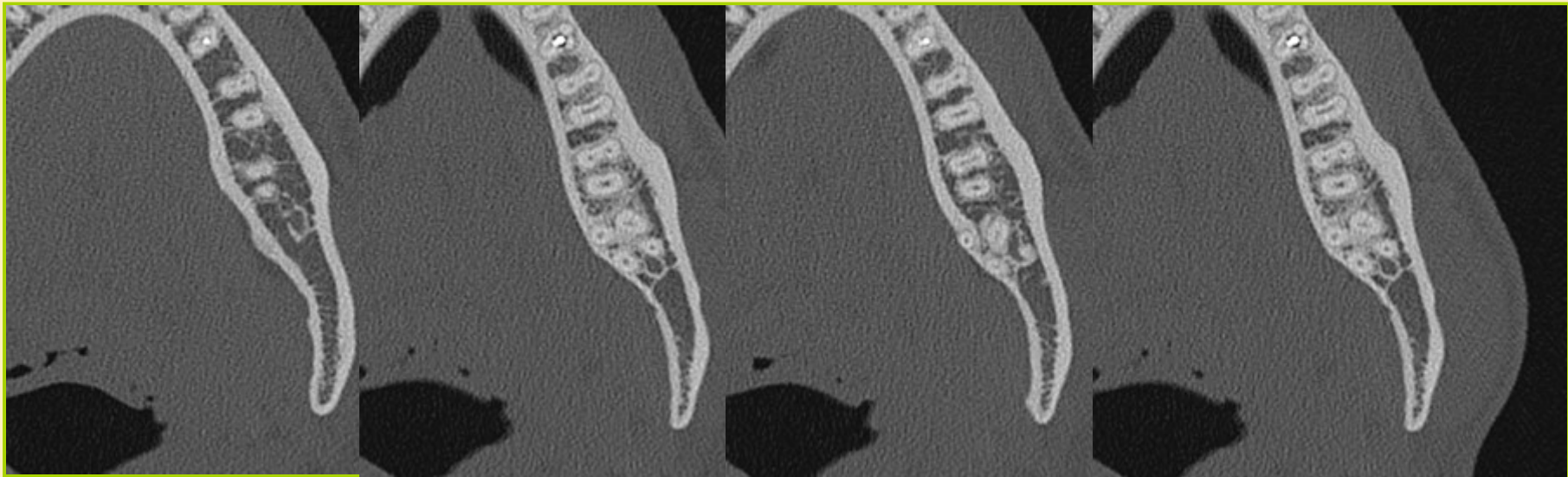
DENT INCLUSE ET SINUS



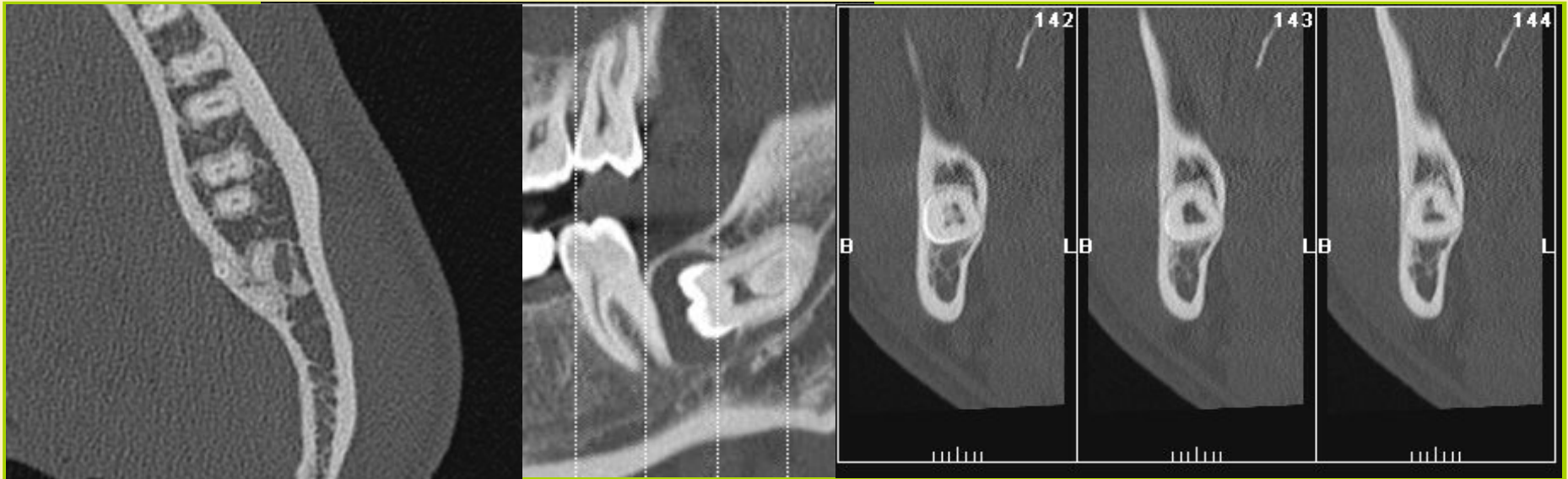
DENT INCLUSE ET SINUS



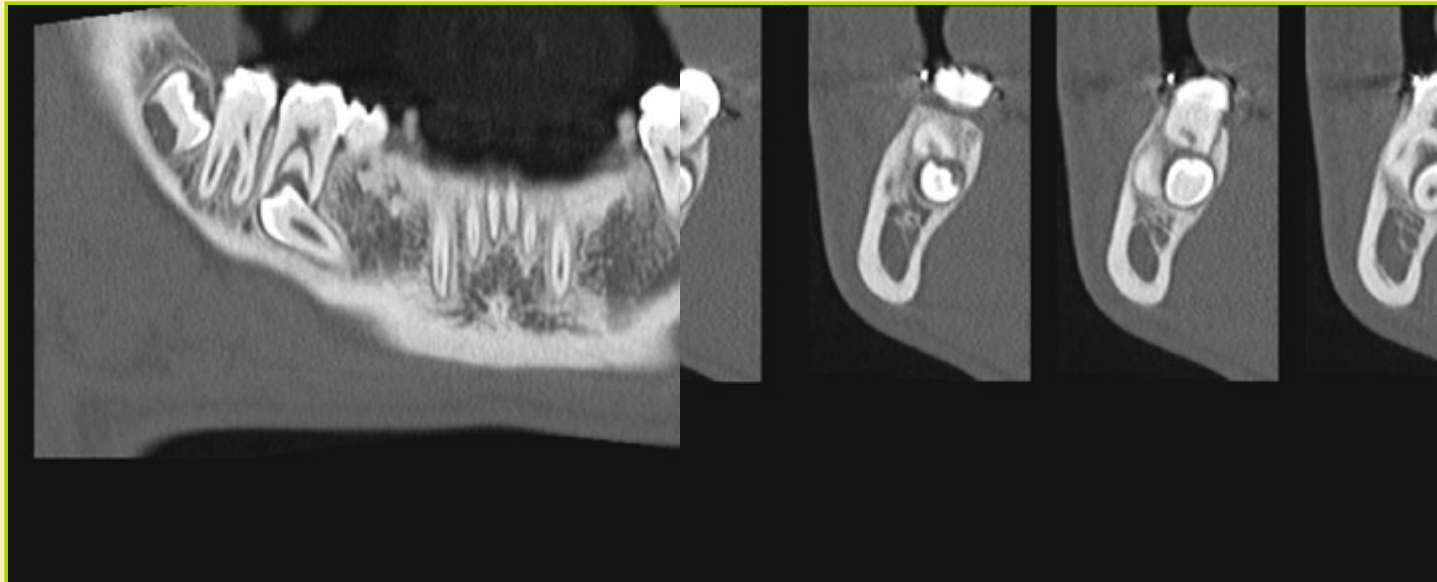
DENT INCLUSE ET CDI



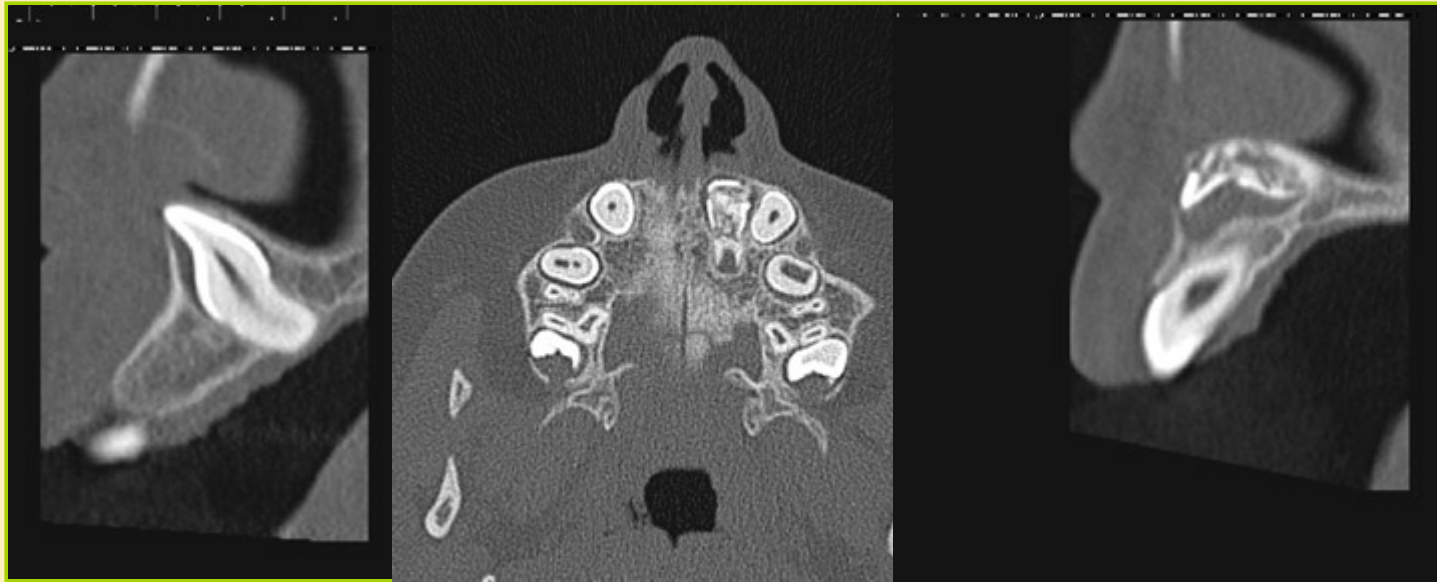DENT INCLUSE ET CDI



ORTHODONTIE

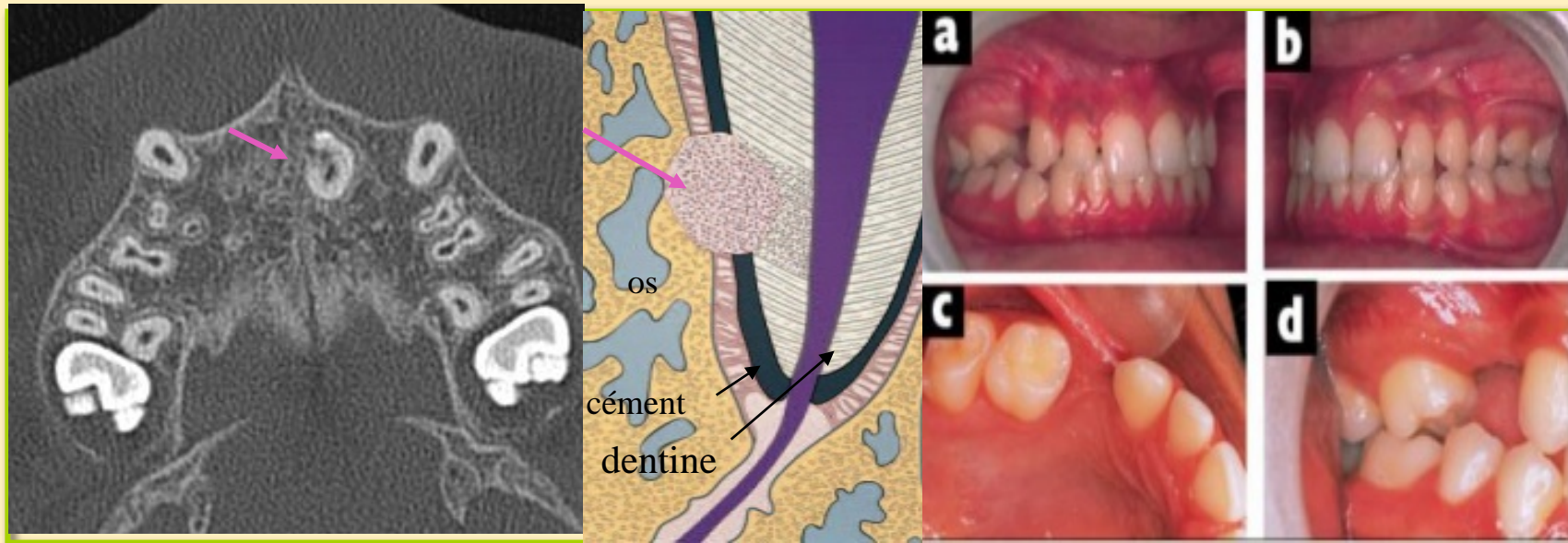


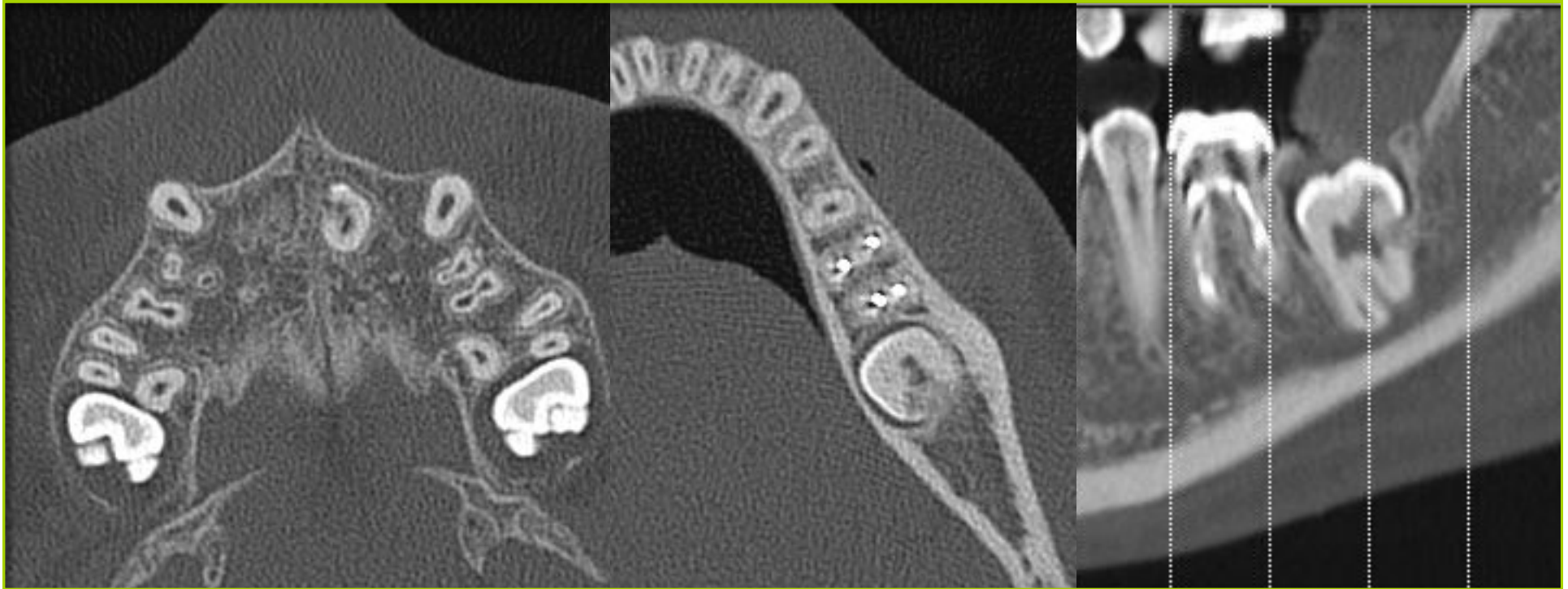ORTHODONTIE



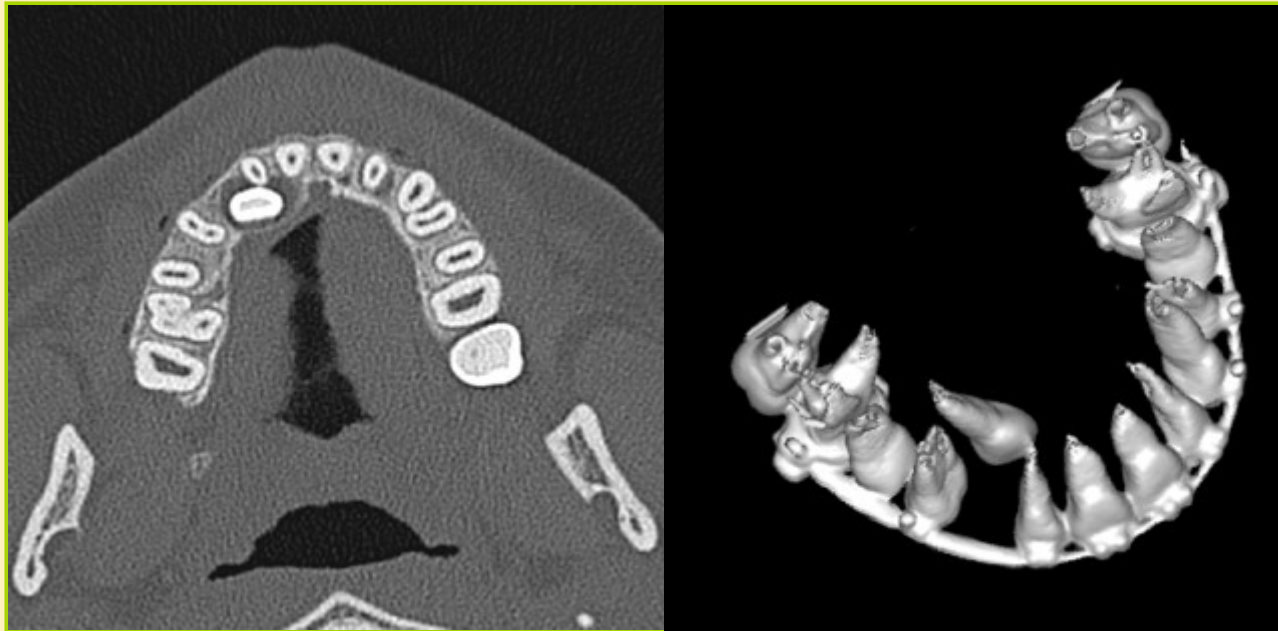
ANKYLOSE DENTAIRE

- Envahissement progressif de l'espace parodontal, du cément voire de la dentine par le tissu osseux.

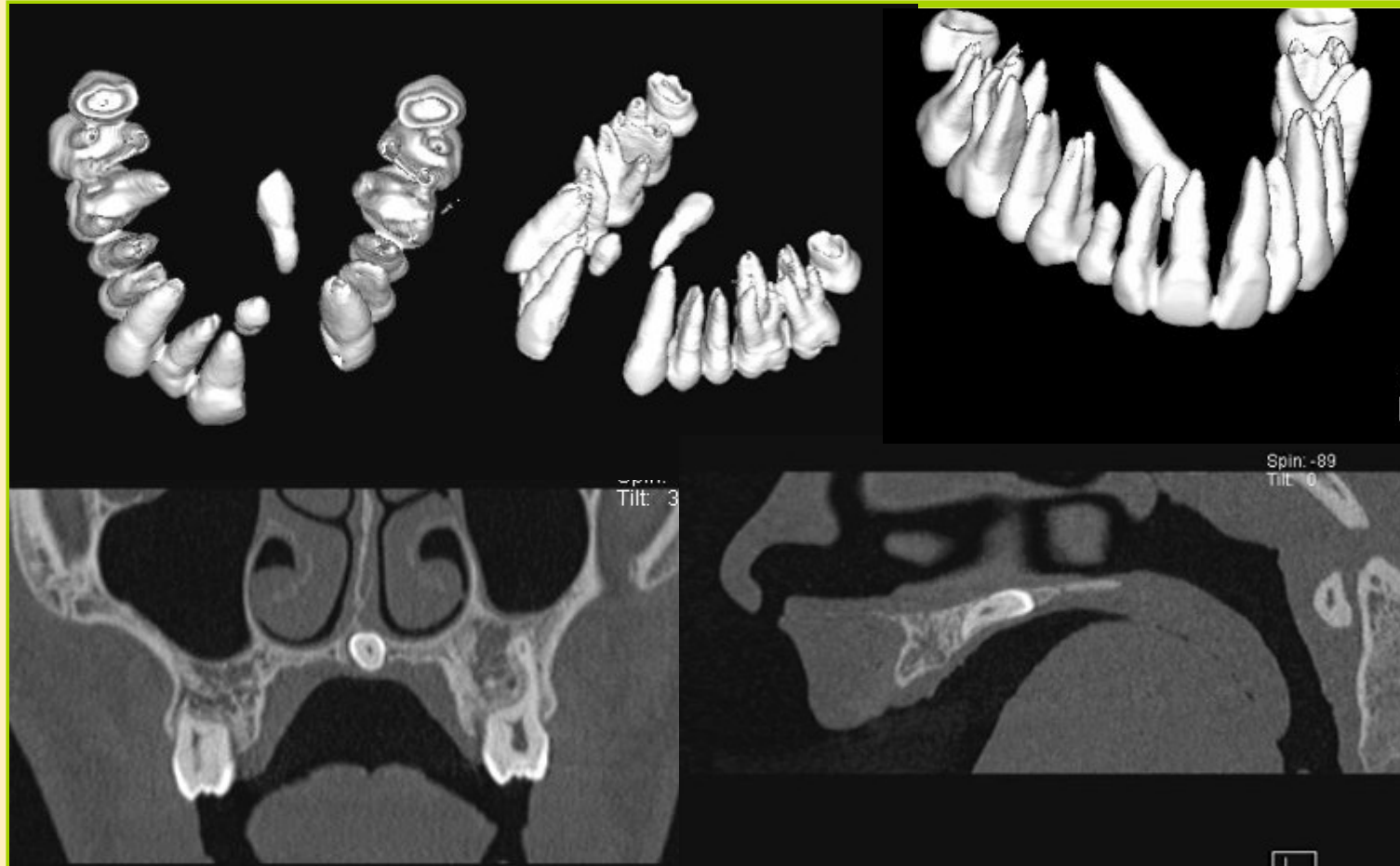




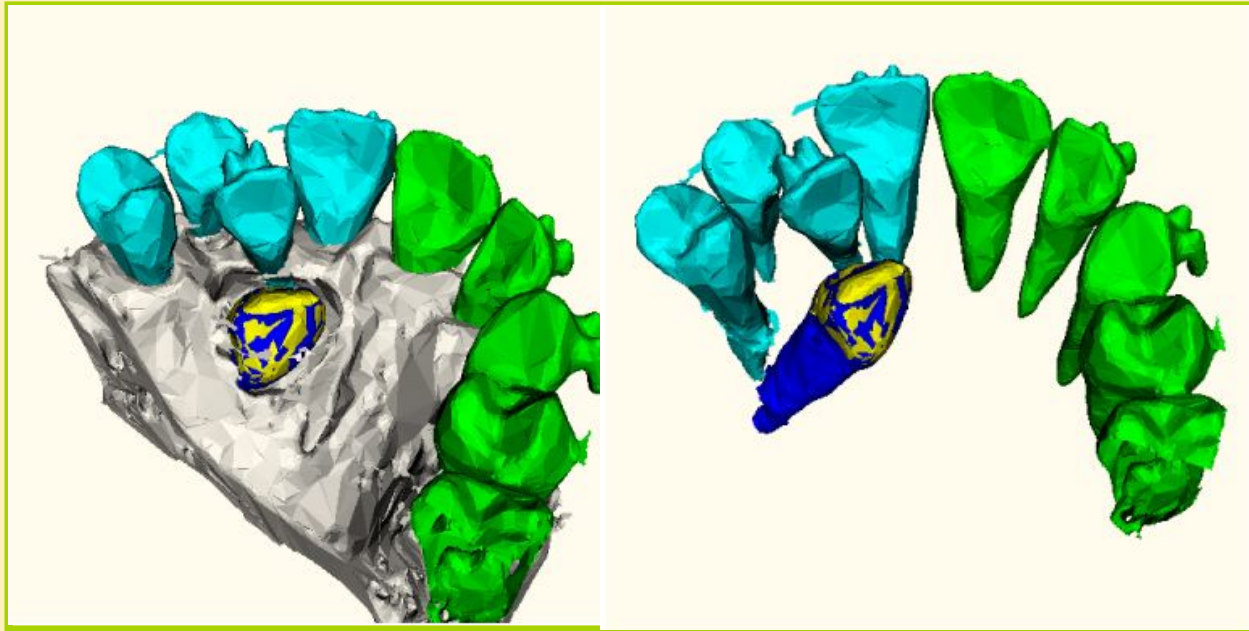
ORTHODONTIE



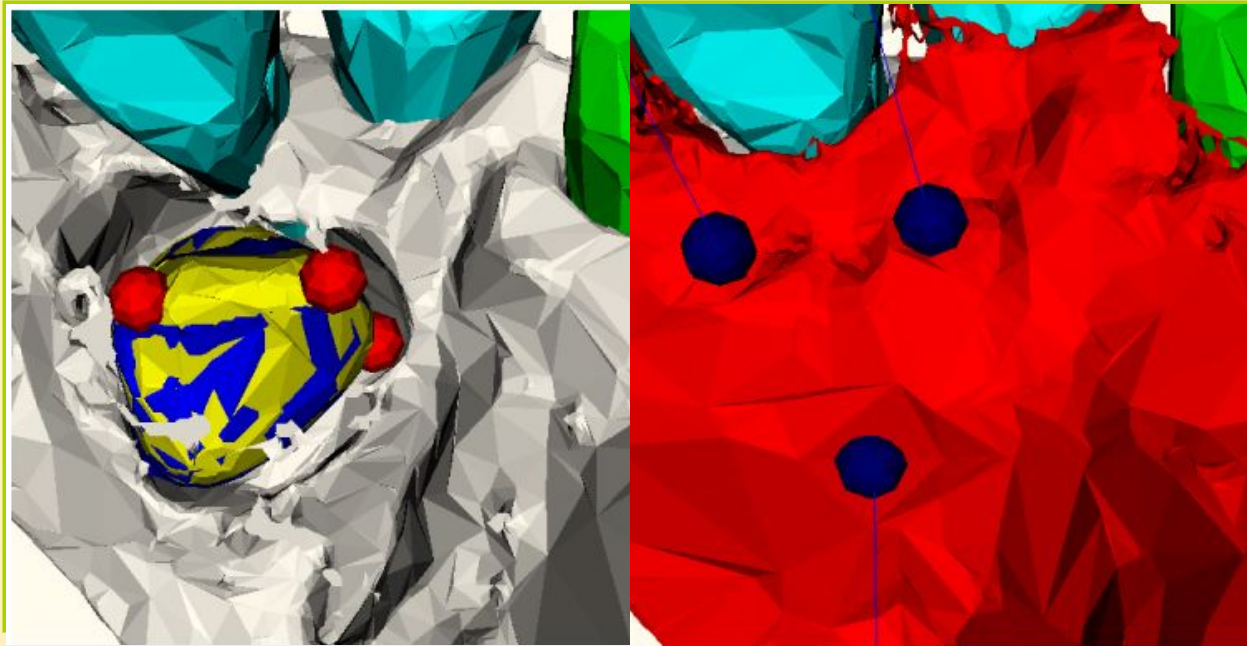
ORTHODONTIE



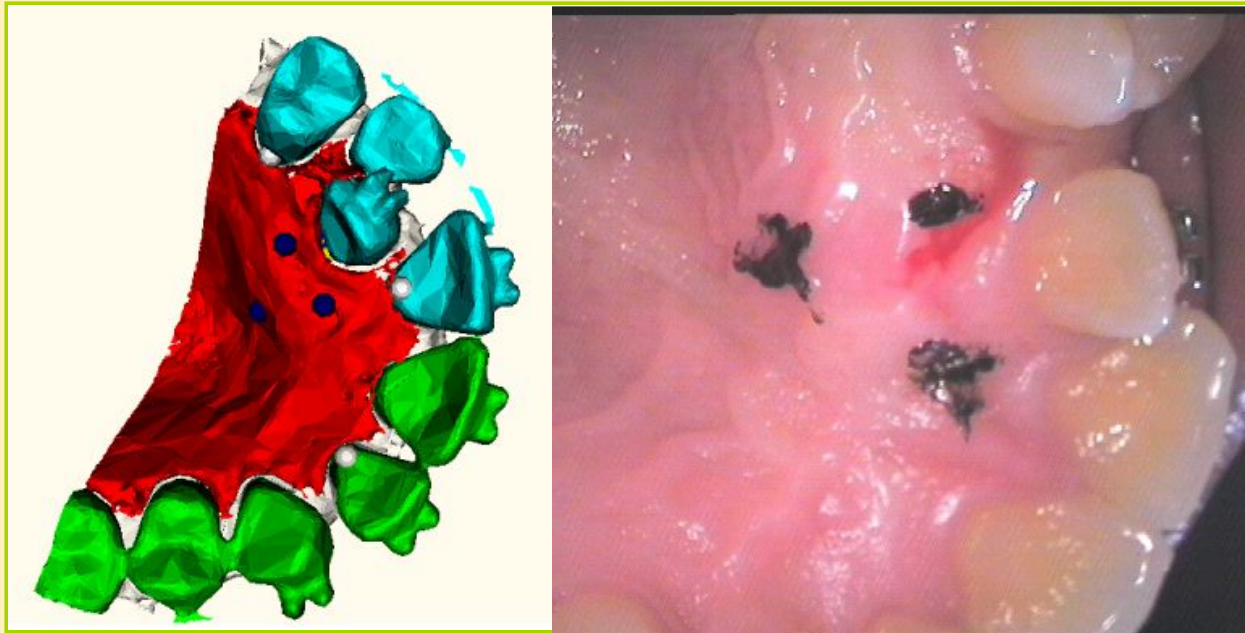
ORTHODONTIE



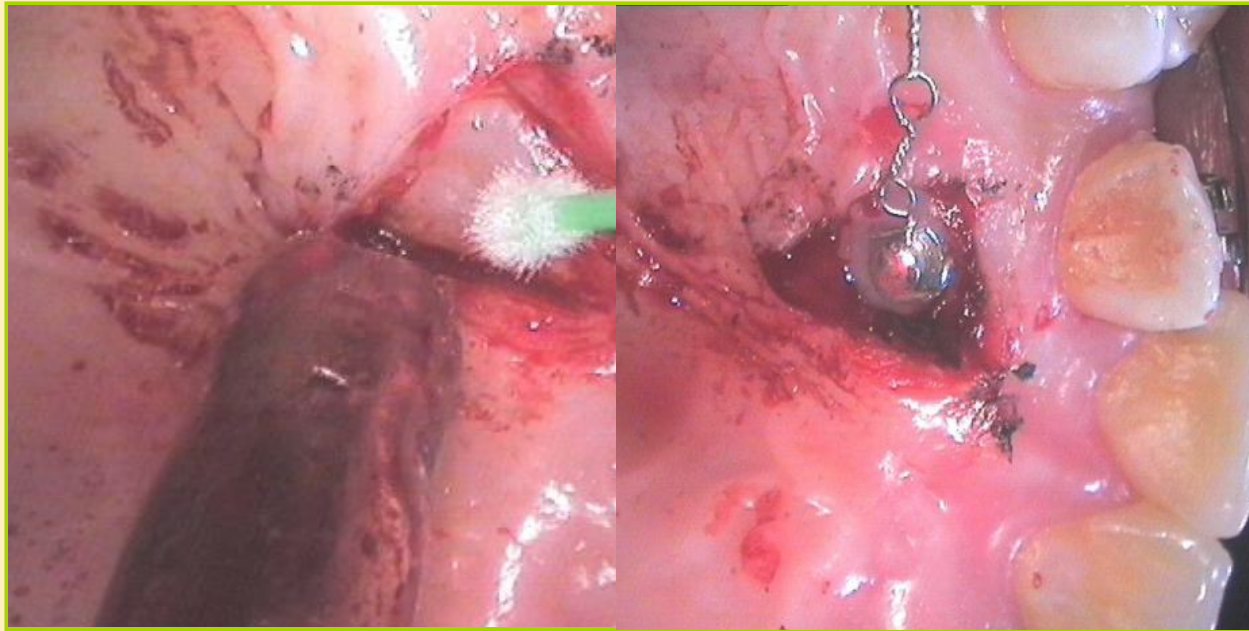
ORTHODONTIE



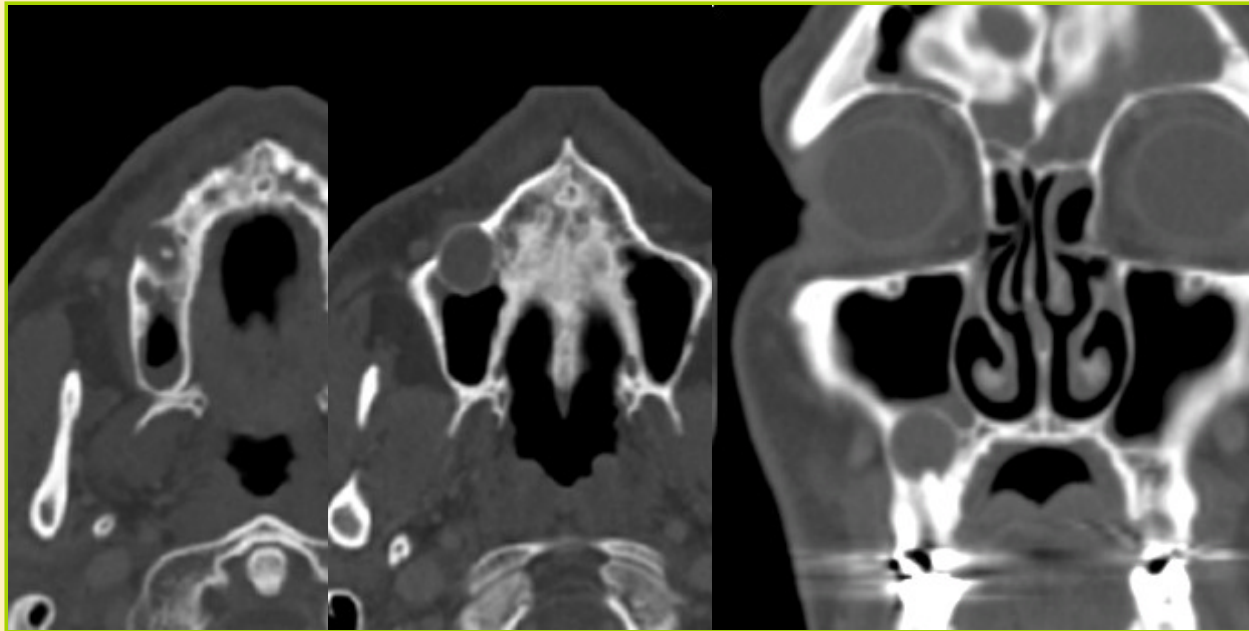
ORTHODONTIE



ORTHODONTIE

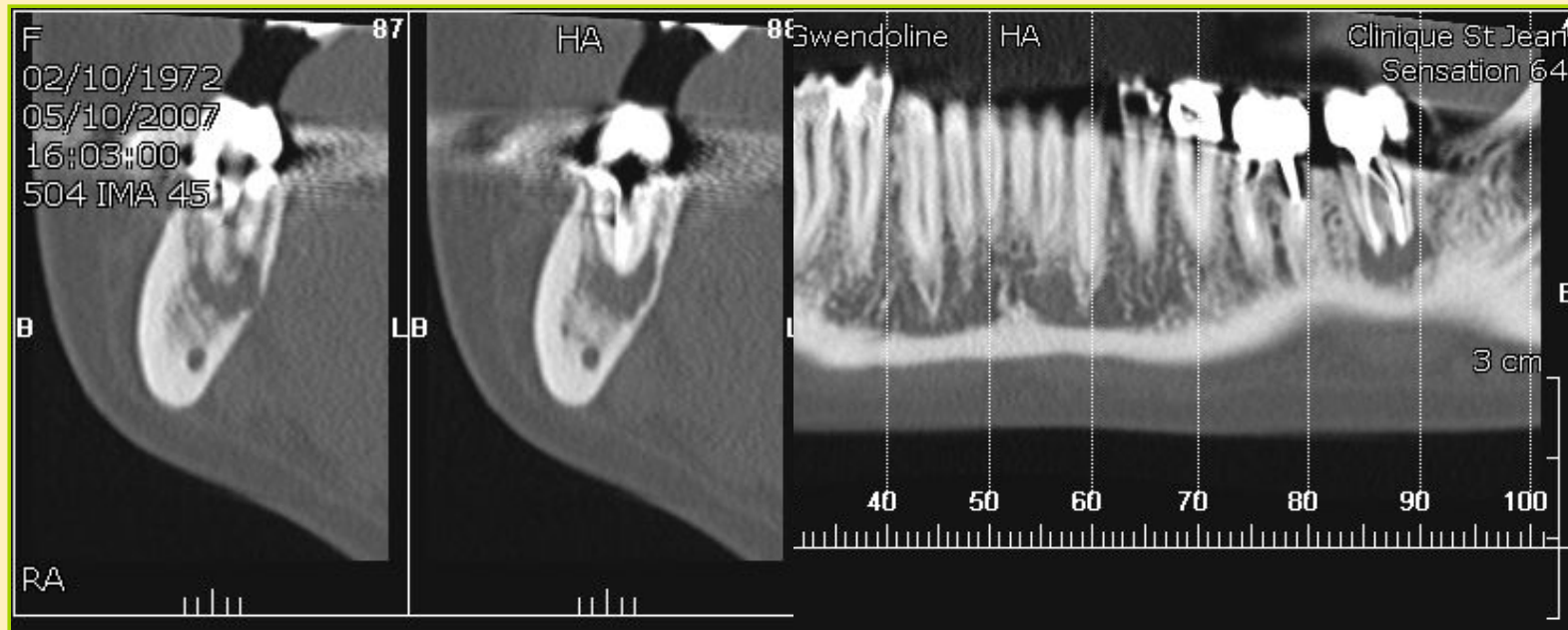


PATHOLOGIE DENTAIRE



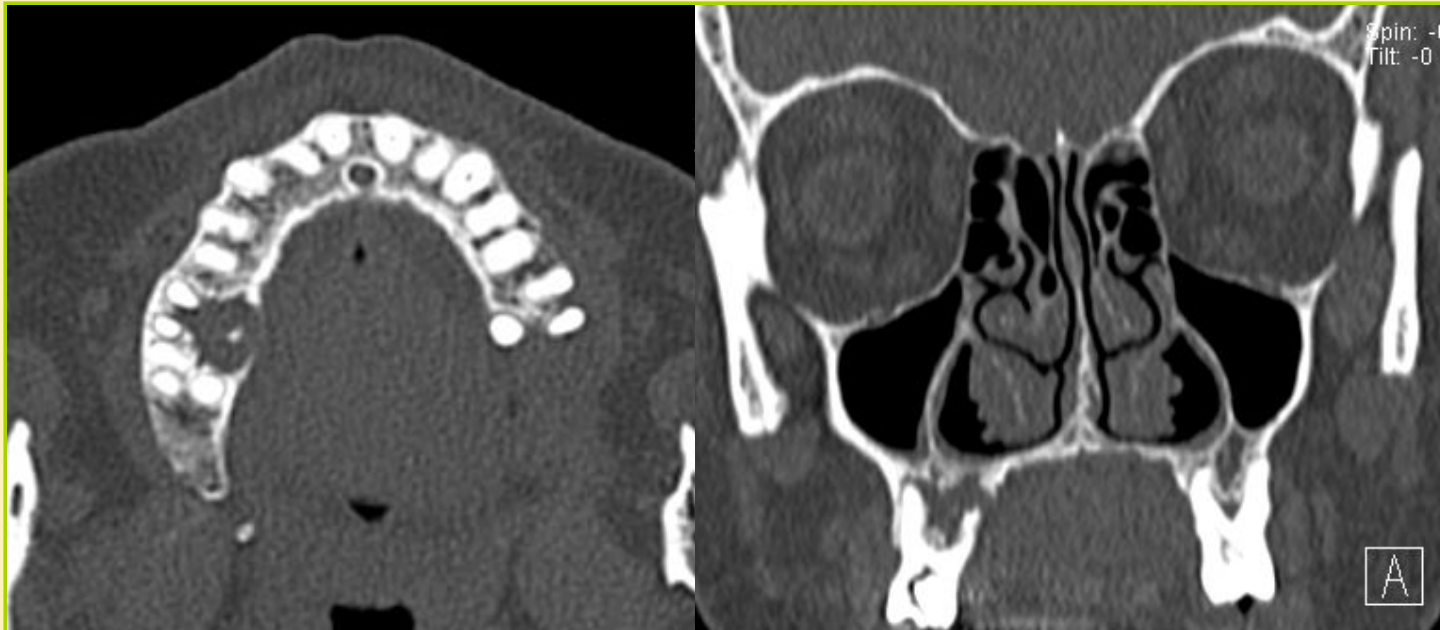KYSTE APICAL

PATHOLOGIE DENTAIRE



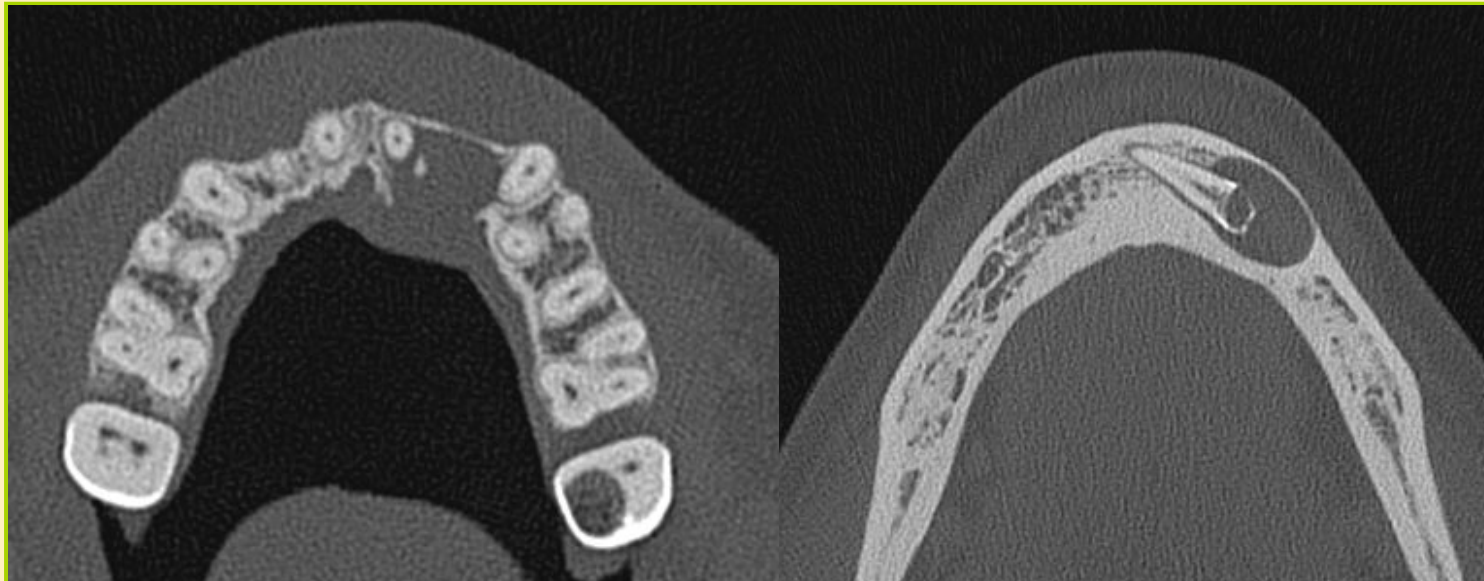
KYSTE APICAL

PATHOLOGIE DENTAIRE



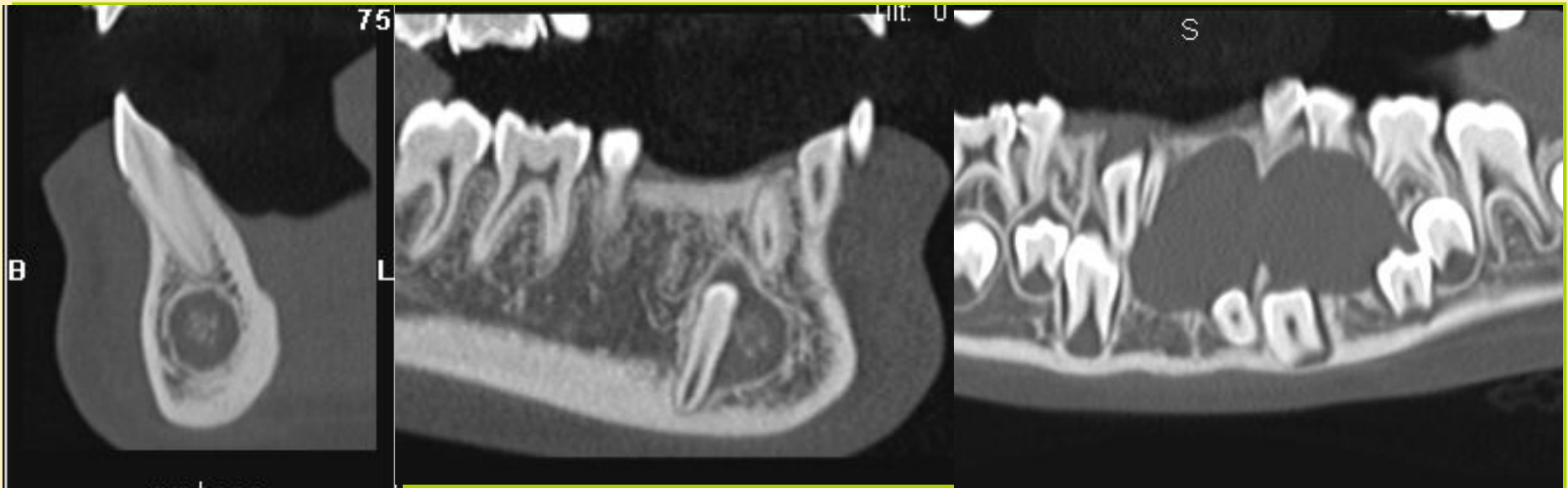
KYSTE APICAL

PATHOLOGIE DENTAIRE



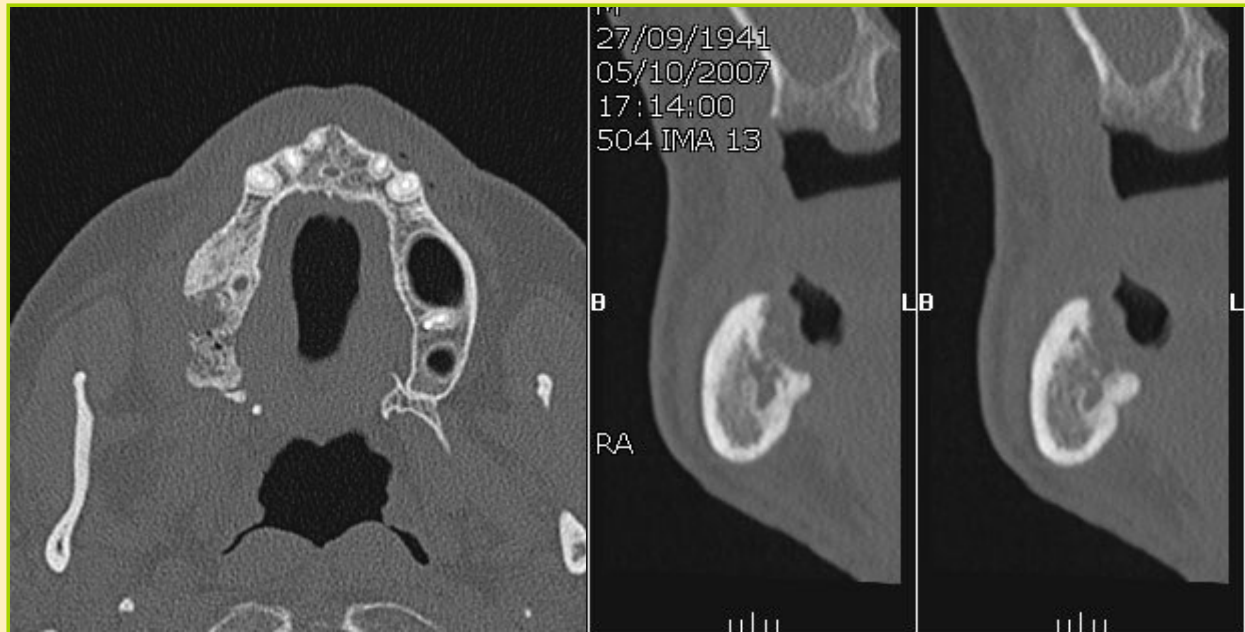
KYSTE APICAL

PATHOLOGIE DENTAIRE



AUTRES KYSTES

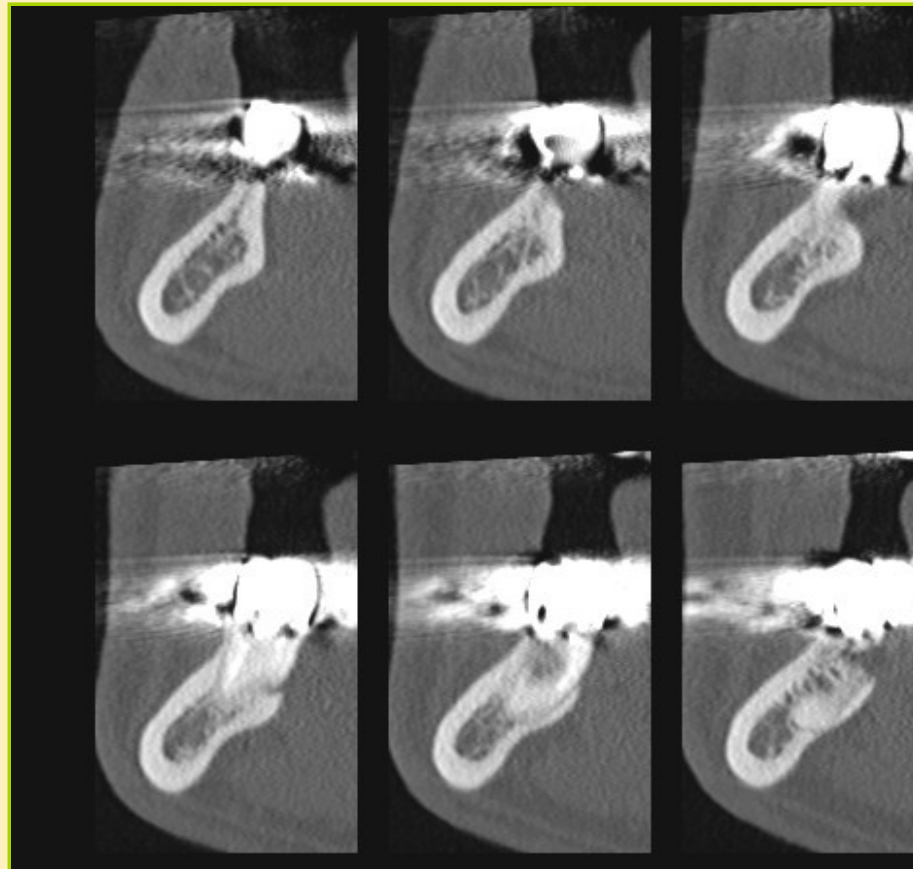
PATHOLOGIE OSSEUSE



OsteoNécrose
aux Diphosphonates

Ostéoradionécrose

ARTEFACTS METALLIQUES



LESIONS TRAUMATIQUES

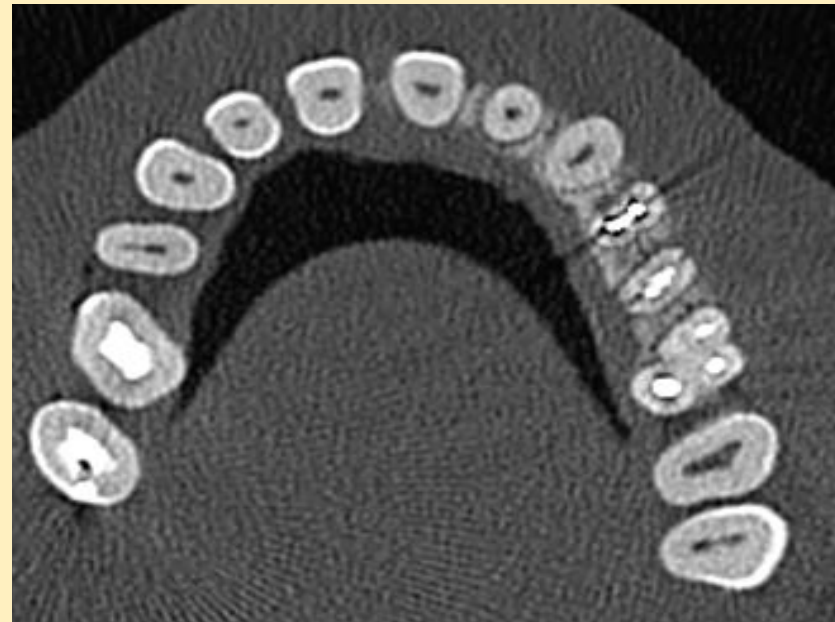
Fractures dentaires

- Fissure avec ou sans exposition de la pulpe
- Séparation dentaire

Déplacements dentaires

- Le + souvent avec fracture de l'os alvéolaire

Luxations dentaires



LESIONS TRAUMATIQUES

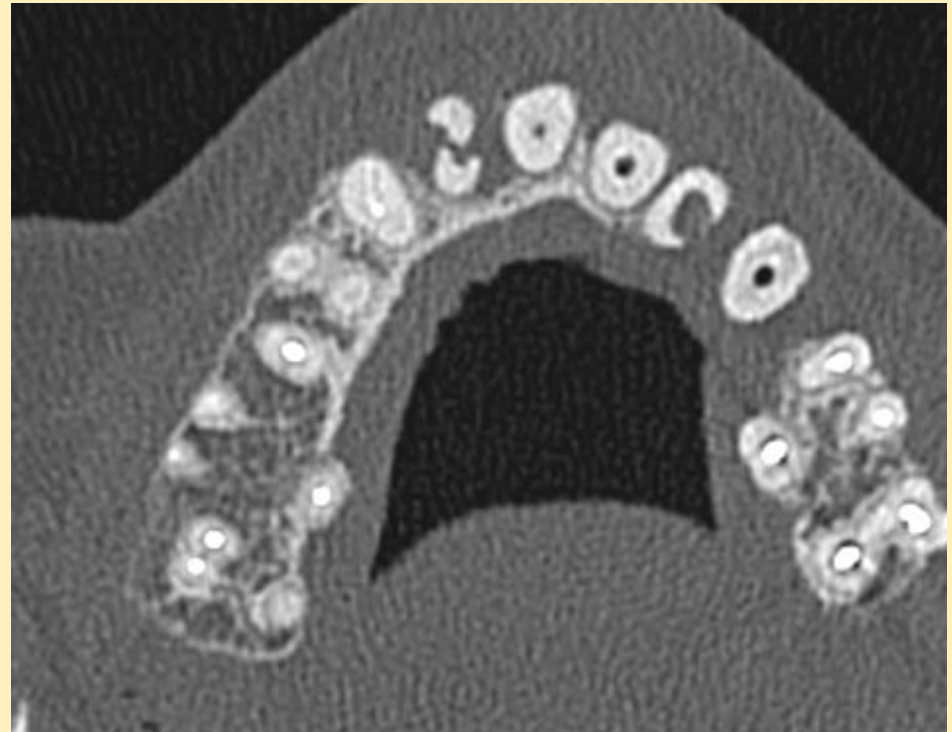
Fractures dentaires

- Fissure avec ou sans exposition de la pulpe
- Séparation dentaire

Déplacements dentaires

- Le + souvent avec fracture de l'os alvéolaire

Luxations dentaires



LESIONS TRAUMATIQUES

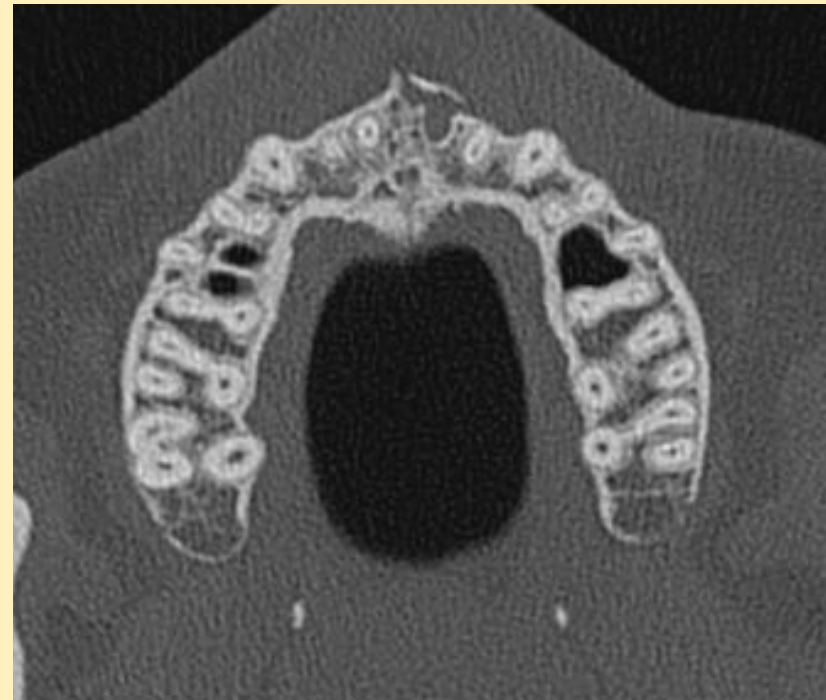Fractures dentaires

- Fissure avec ou sans exposition de la pulpe
- Séparation dentaire

Déplacements dentaires

- Le + souvent avec fracture de l'os alvéolaire

Luxations dentaires



LESIONS TRAUMATIQUES

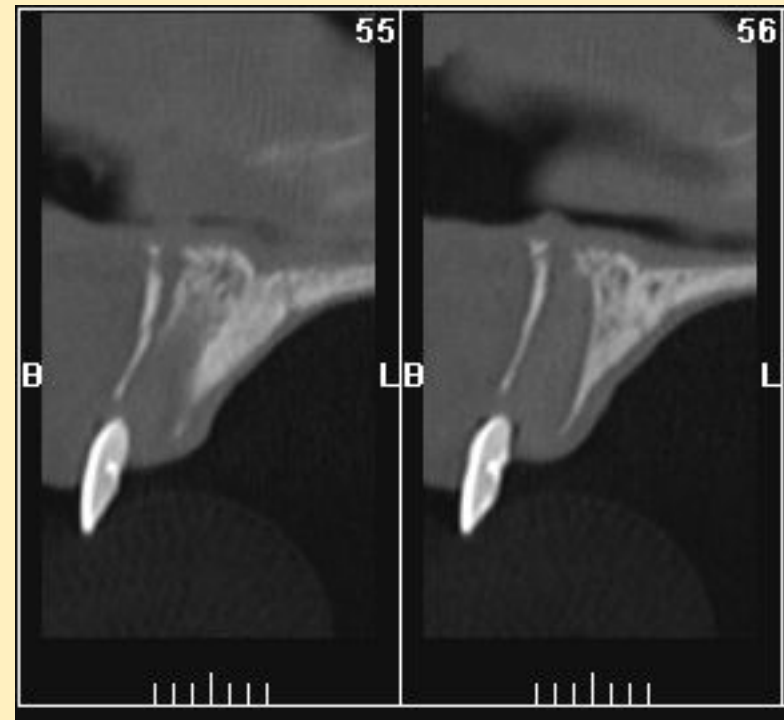
Fractures dentaires

- Fissure avec ou sans exposition de la pulpe
- Séparation dentaire

Déplacements dentaires

- Le + souvent avec fracture de l'os alvéolaire

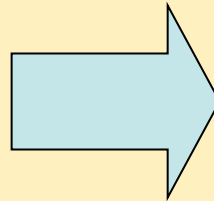
Luxations dentaires



SCANNER EN IMPLANTOLOGIE

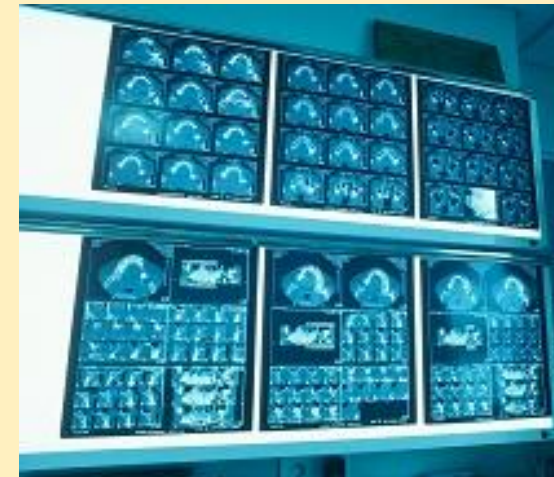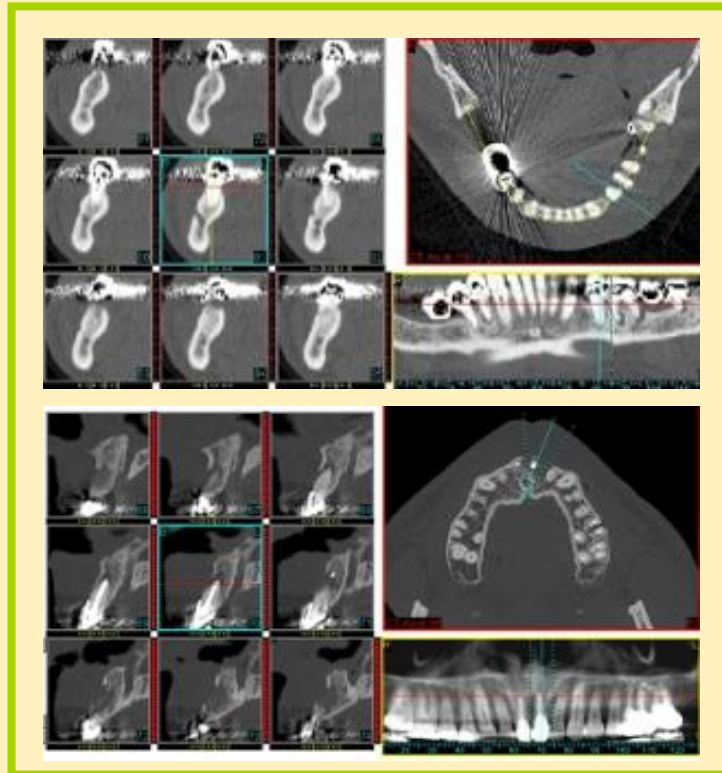
Contraintes

- Echelle 1 (Films)
- CD ++
- Qualité
- Lisibilité

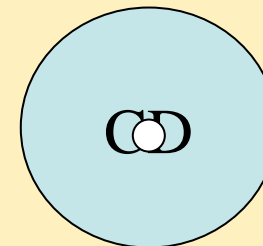


Logiciels
ADAPTES
(Dentascanner...)

SCANNER EN IMPLANTOLOGIE



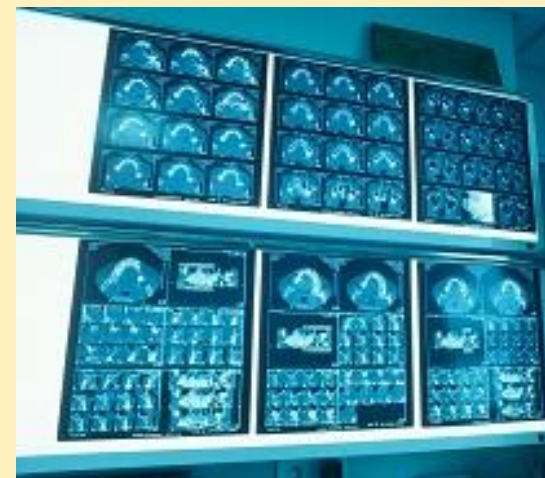+




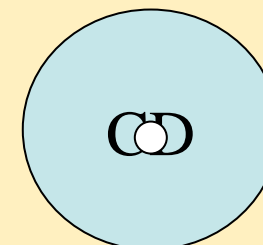
SCANNER EN IMPLANTOLOGIE

Le CD contient:

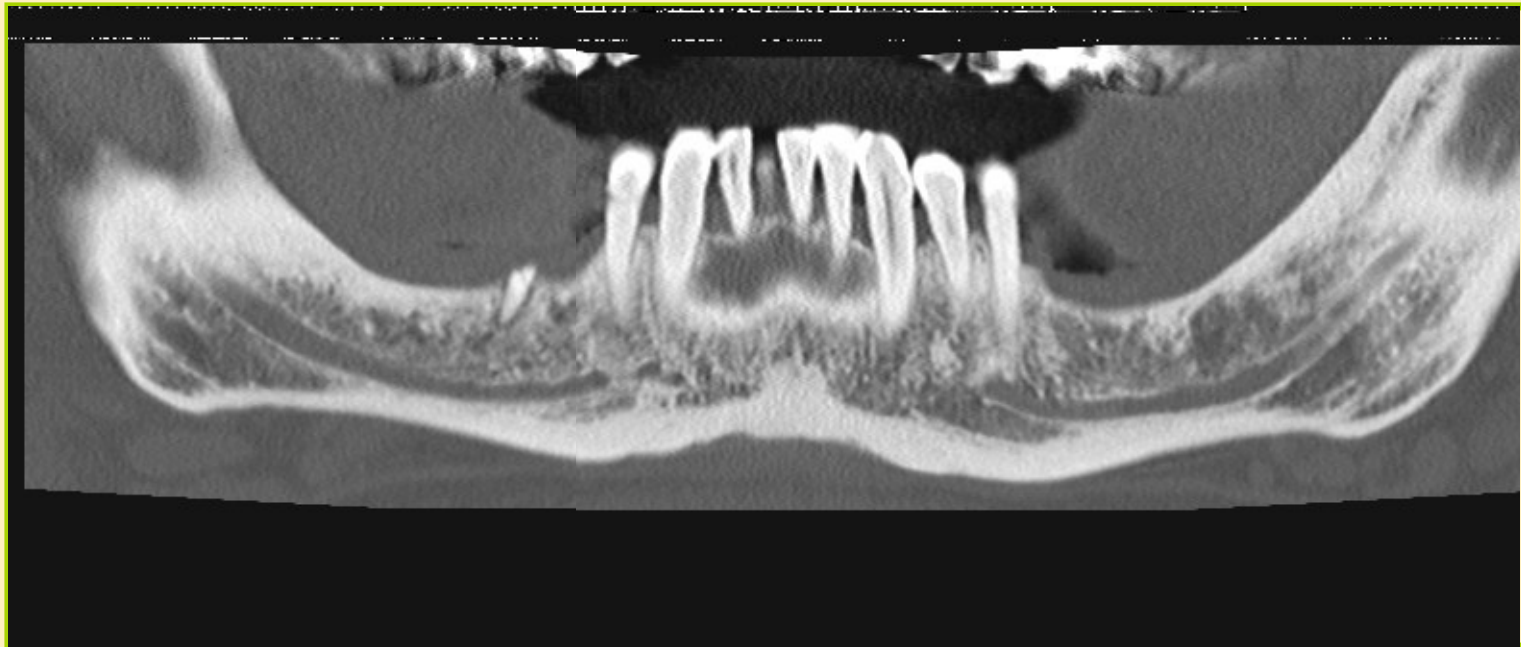- toutes les images (Dicom)
- Les reconstructions (pano, para-axiales...)
- Le logiciel de lecture (PC voir Mac...)



+

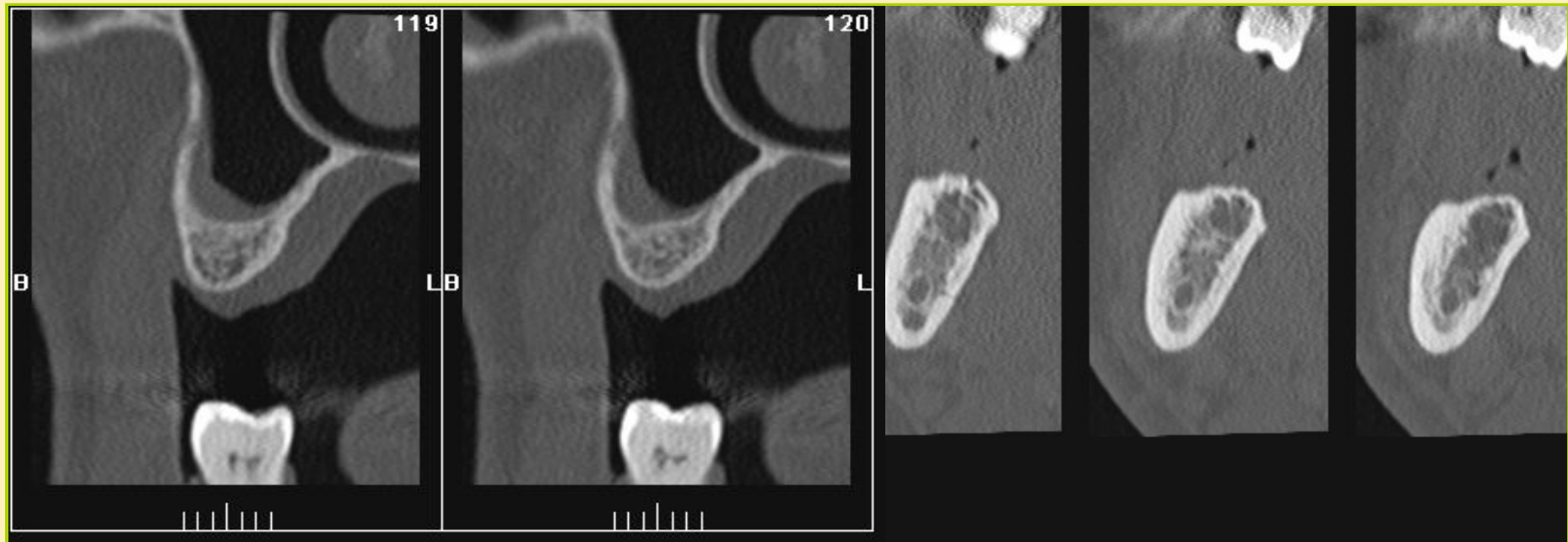


SCANNER EN IMPLANTOLOGIE



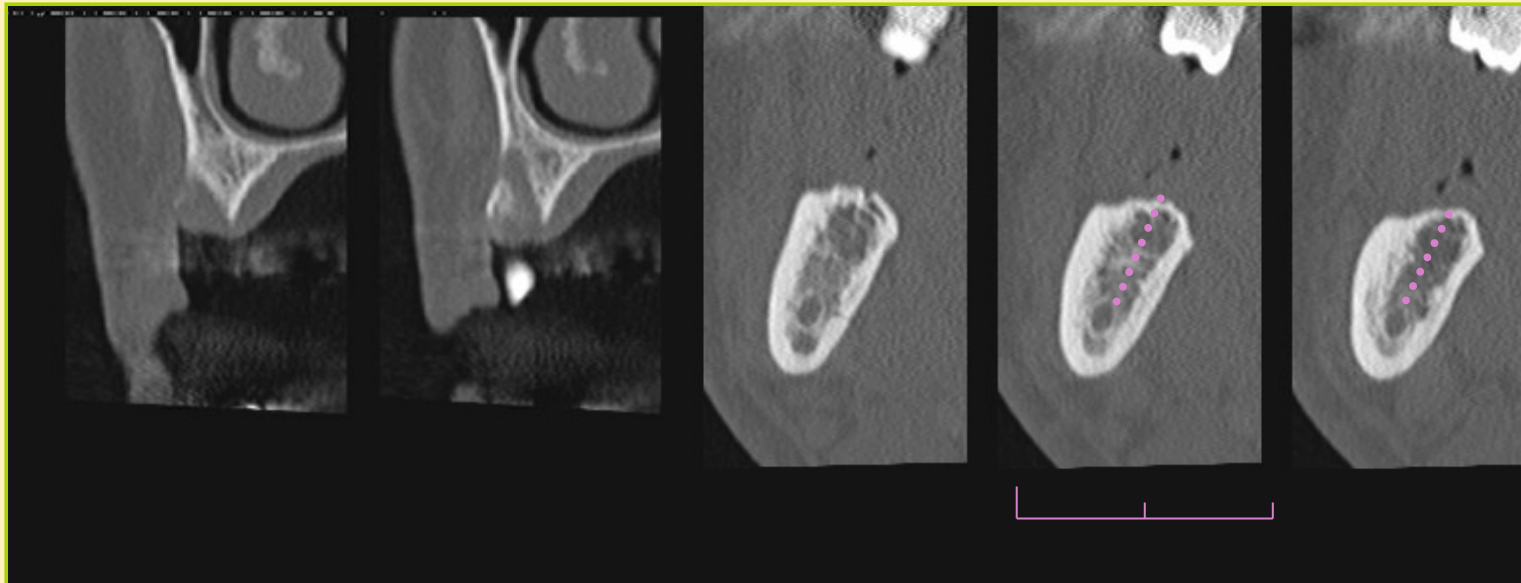
1°) Reconstruction PANORAMIQUE

SCANNER EN IMPLANTOLOGIE



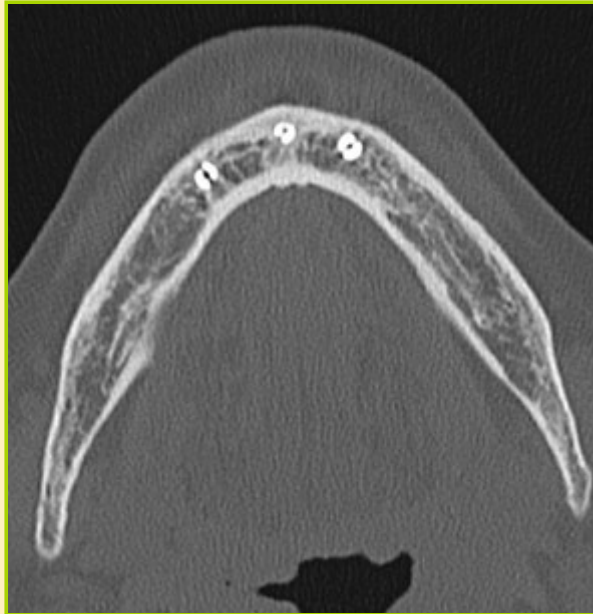2°) Reconstructions PARA-AXIALES

SCANNER EN IMPLANTOLOGIE



2°) Reconstructions PARA-AXIALES

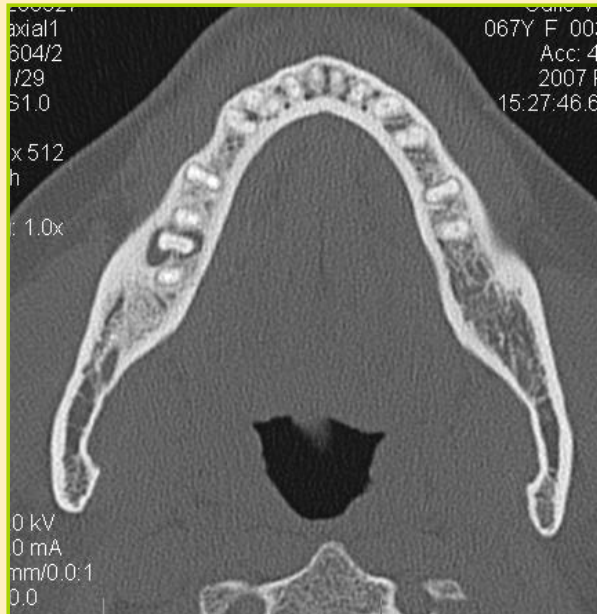SCANNER EN IMPLANTOLOGIE



Qualité de l' OS CORTICAL
Qualité de l' OS TRABECULAIRE
Granulome, Parodontopathies...

3°) Coupes AXIALES

SCANNER EN IMPLANTOLOGIE

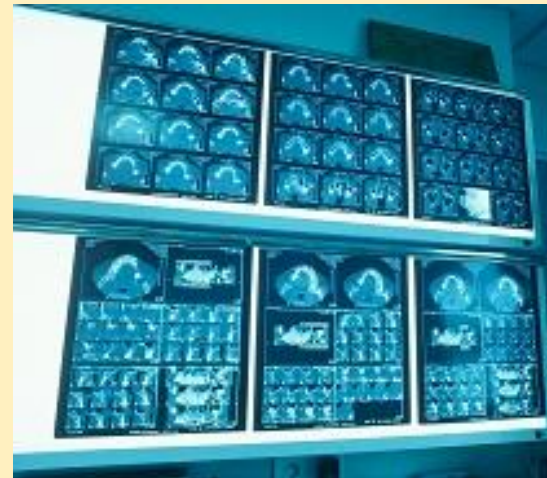

Qualité de l' OS CORTICAL
Qualité de l' OS TRABECULAIRE
Granulome, Parodontopathies...

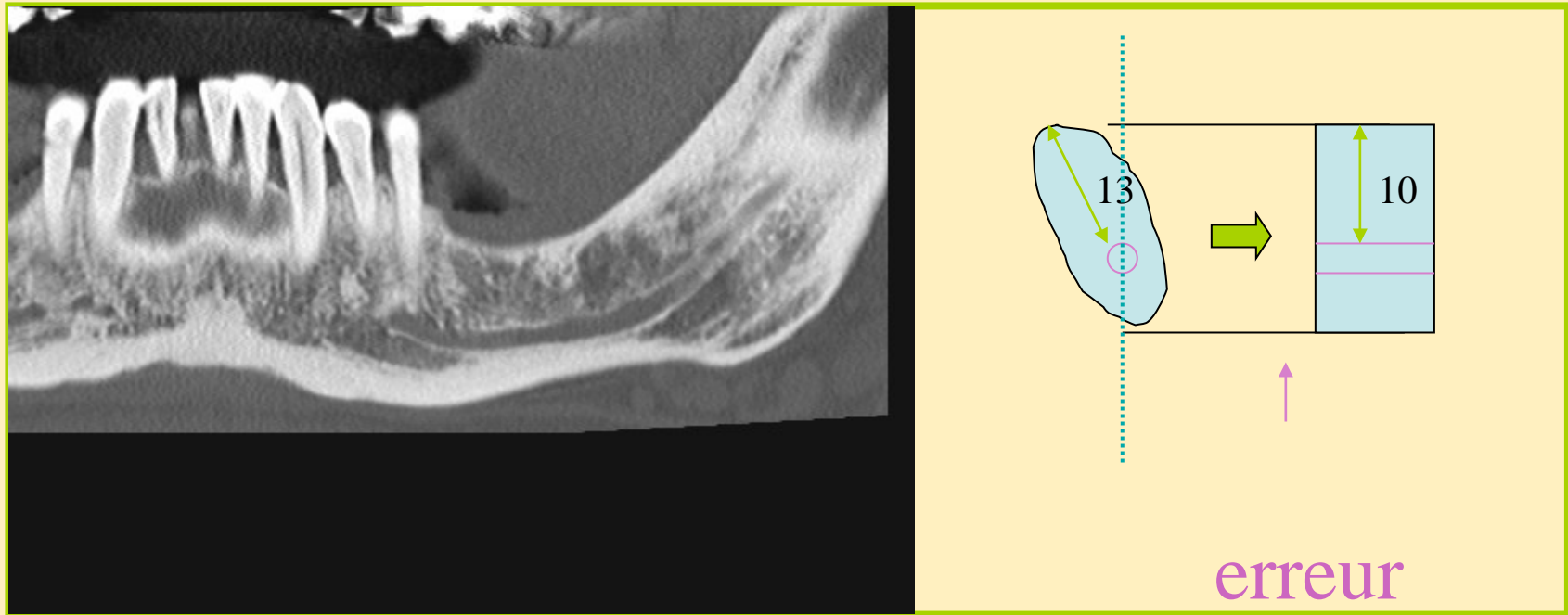
4°) Coupes AXIALES

SCANNER EN IMPLANTOLOGIE

- FILMS échelle 1:
 - Rec.panoramiques
 - Rec.para-axiales
 - Coupe repère annotée
- CD

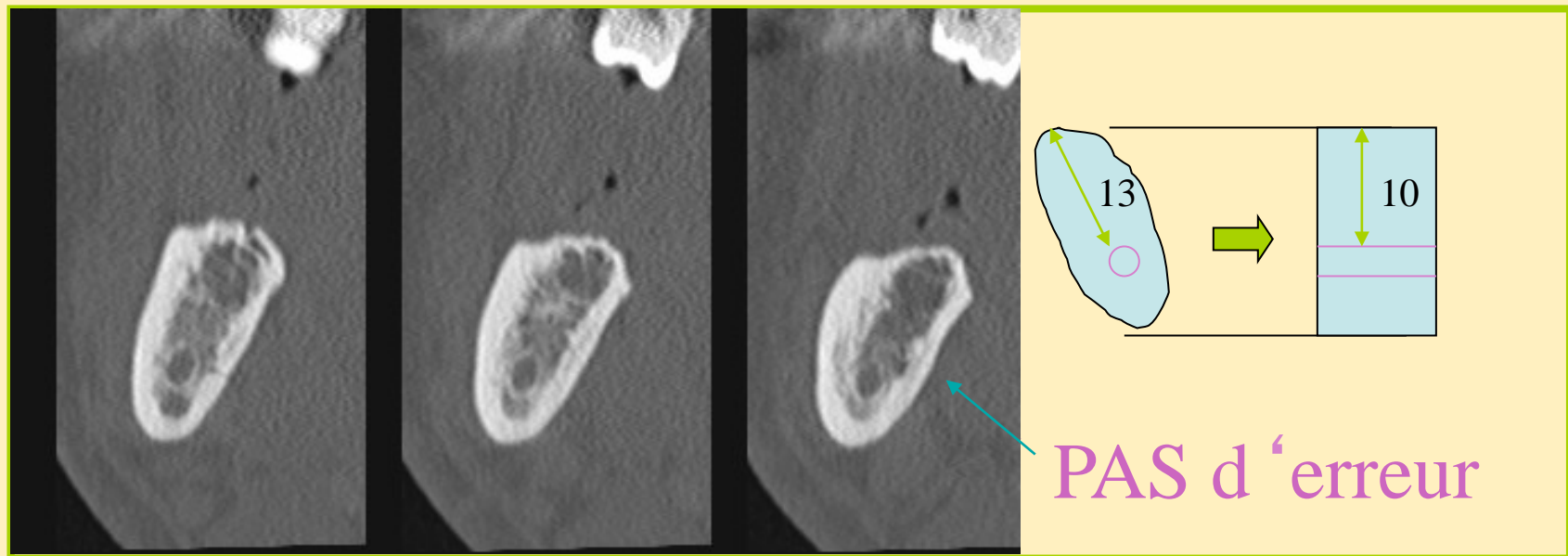


SCANNER EN IMPLANTOLOGIE



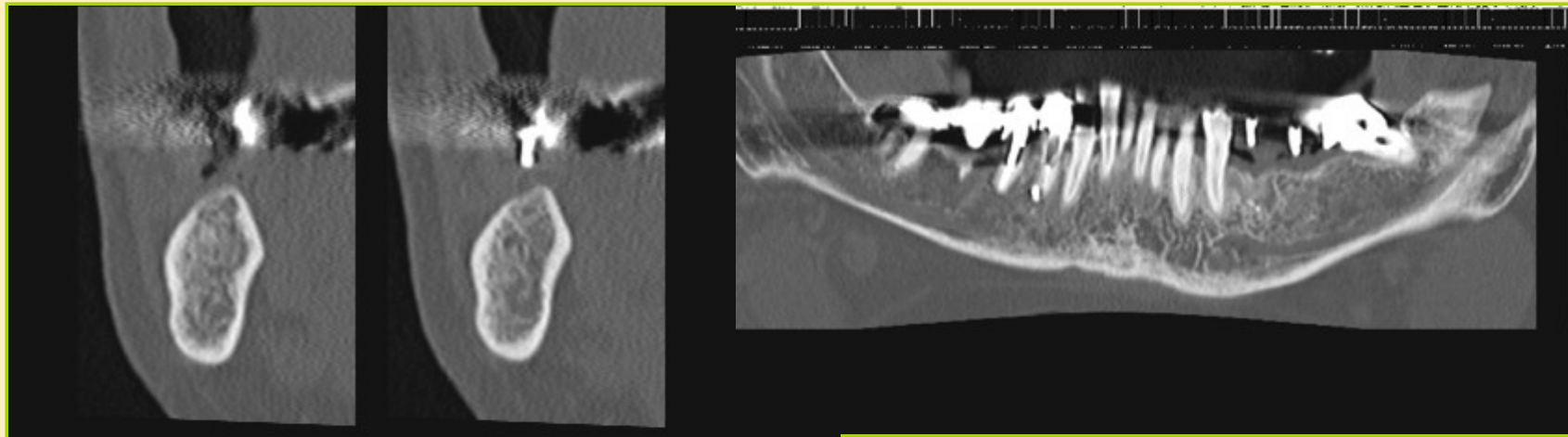
5°) LES MESURES

SCANNER EN IMPLANTOLOGIE

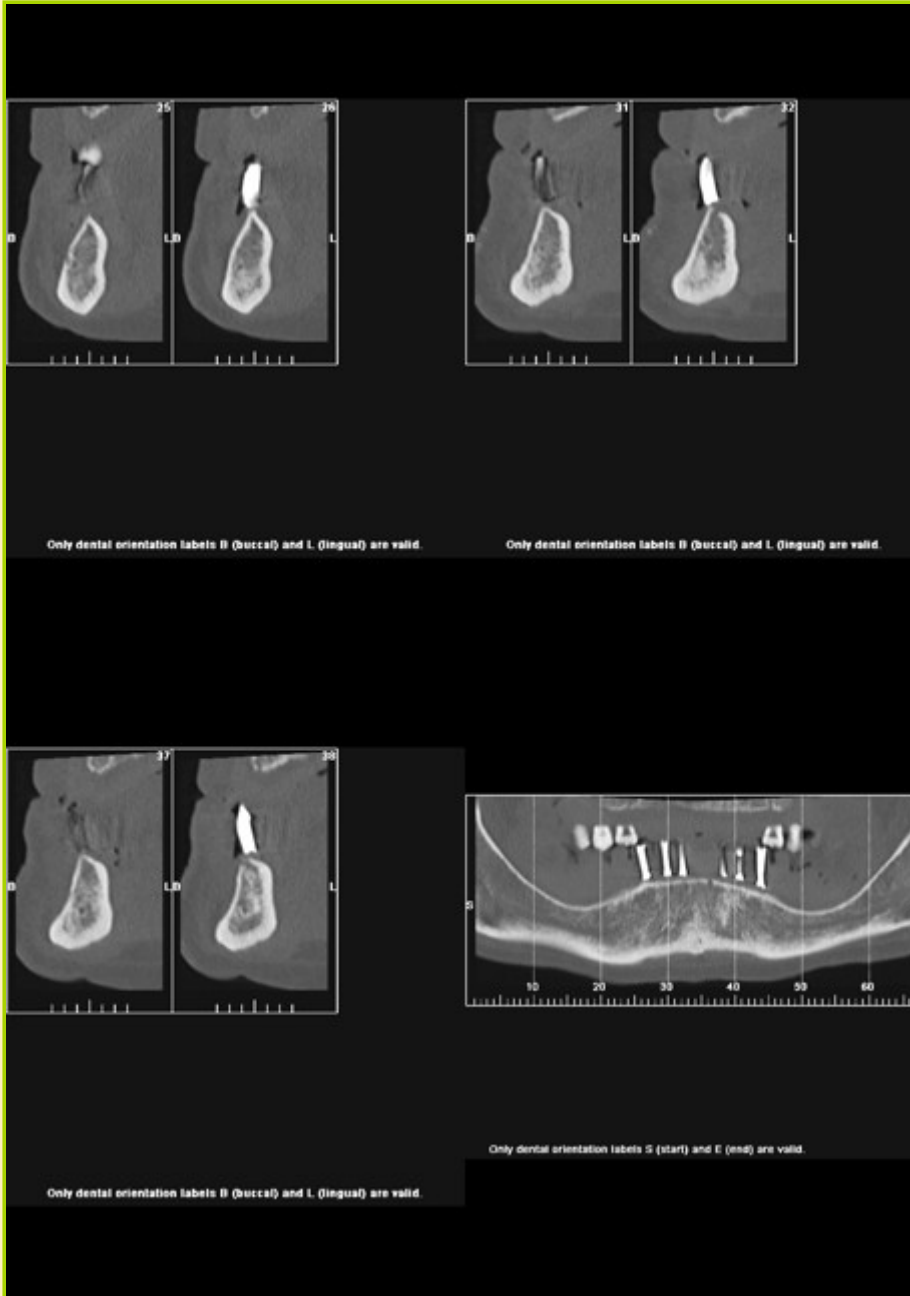


5°) LES MESURES

SCANNER EN IMPLANTOLOGIE

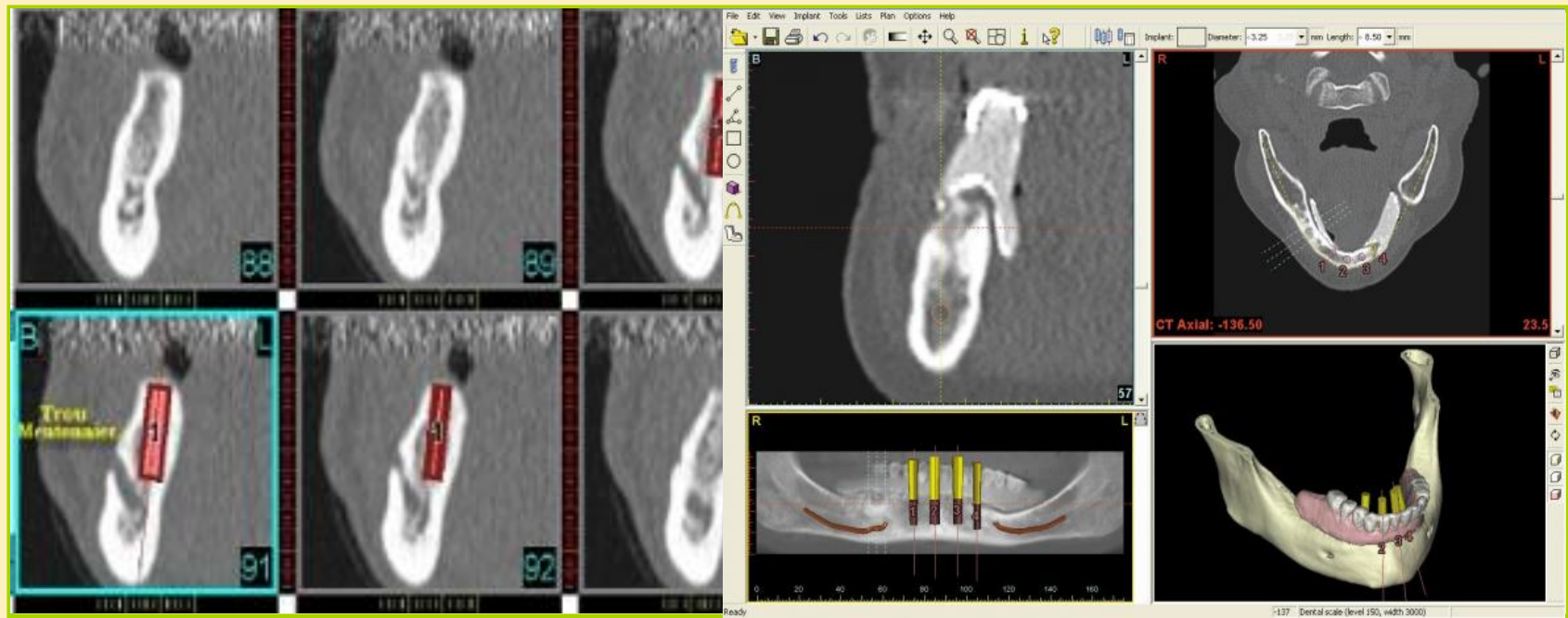


6°) LES REPERES EN BOUCHE



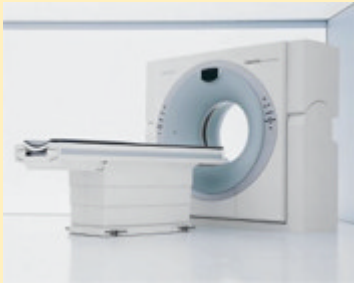6°) LES REPERES EN BOUCHE

SCANNER EN IMPLANTOLOGIE


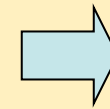
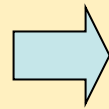


7°) LES LOGICIELS SIMPLES

LES LOGICIELS DE C.A.D

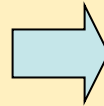


radiologue



dentiste

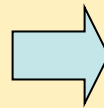
LES LOGICIELS DE C.A.D



Images axiales DICOM seules

~~(pano/ para-axiales)~~

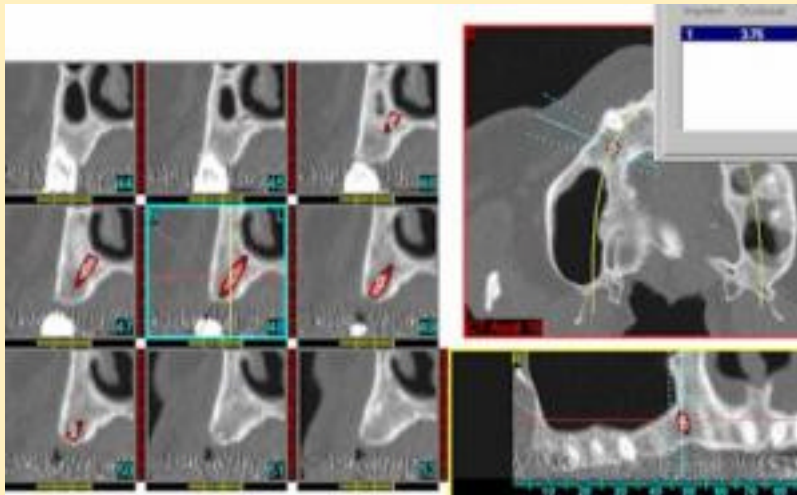
LES LOGICIELS DE C.A.D



LOGICIEL PROPRIETAIRE

- Vues 3D
- Rec. Para-axiales/ pano...

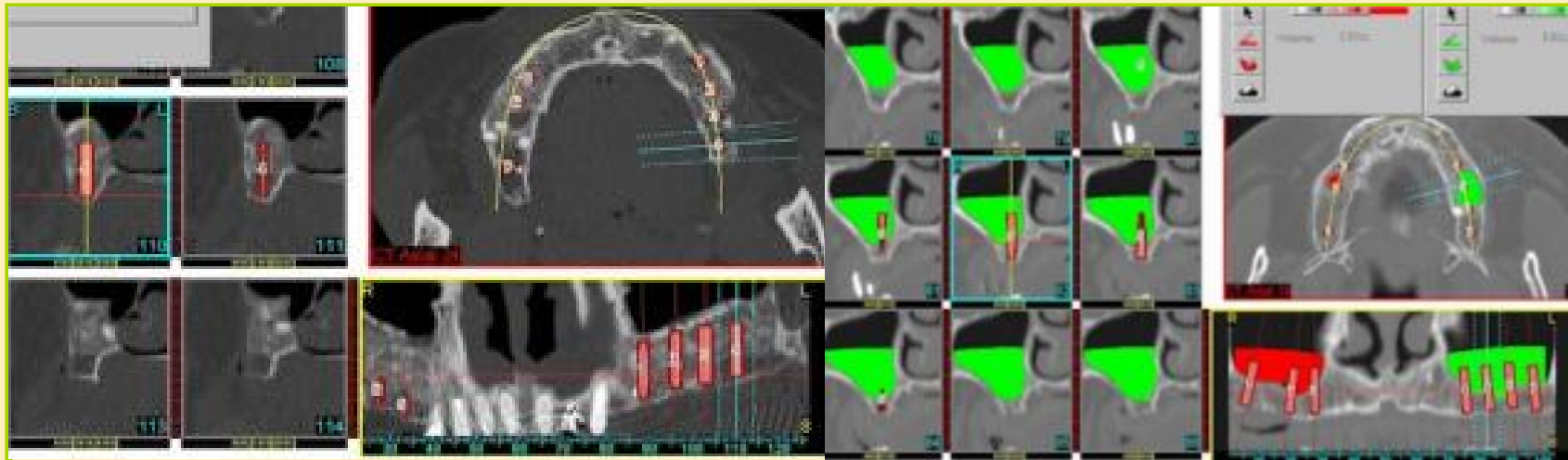
LES LOGICIELS DE C.A.D



- Mesures directes
- Mesures simulation

*Simplant**

LES LOGICIELS DE C.A.D

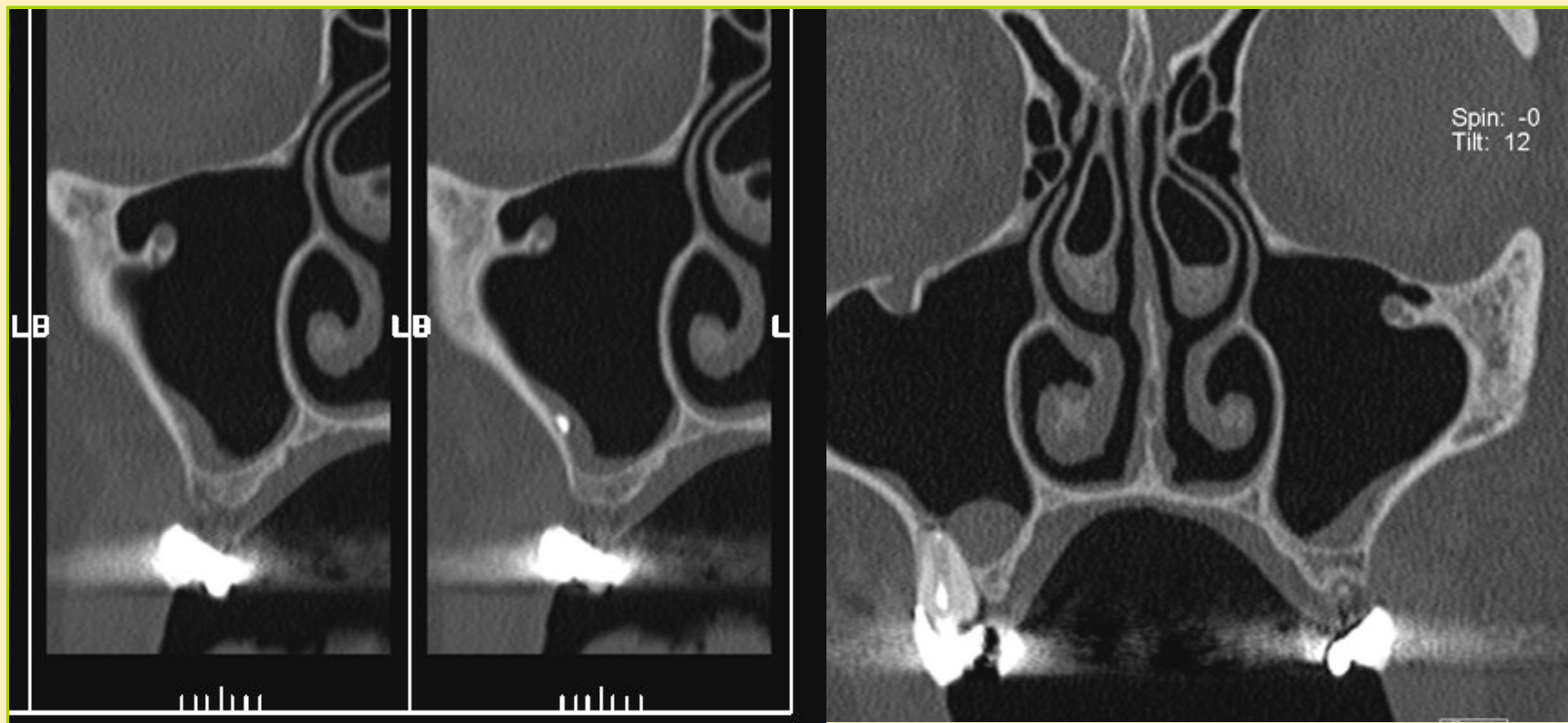


•Calcul du volume osseux
DISPONIBLE

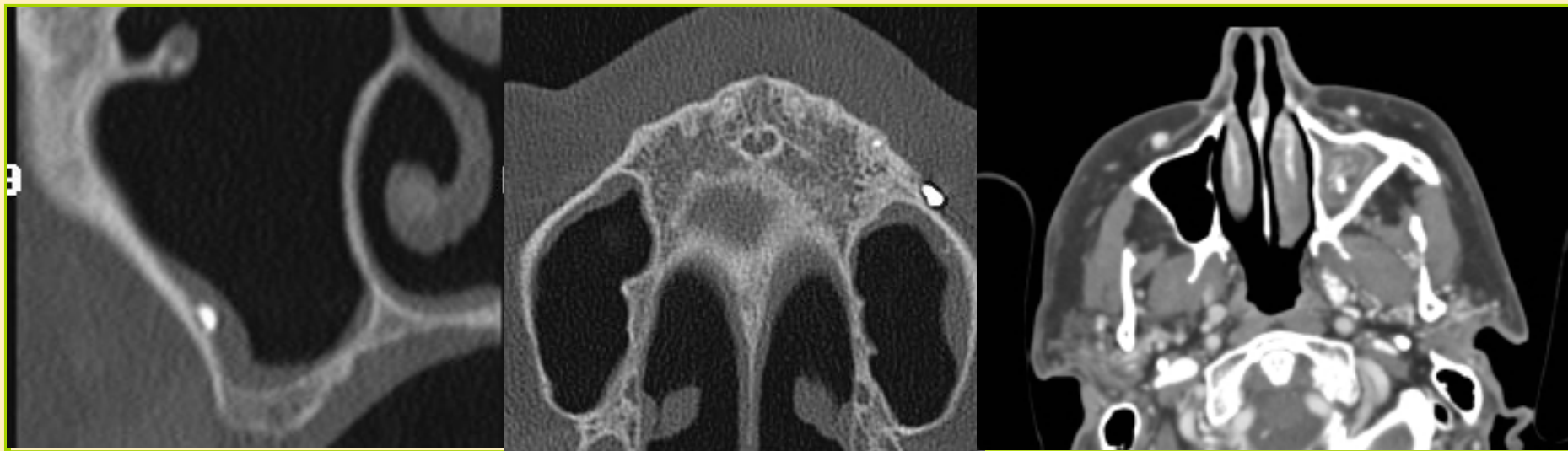•Calcul du volume osseux
MANQUANT

*Simplant**

GREFFES ET COMBLEMENTS SINUSIENS

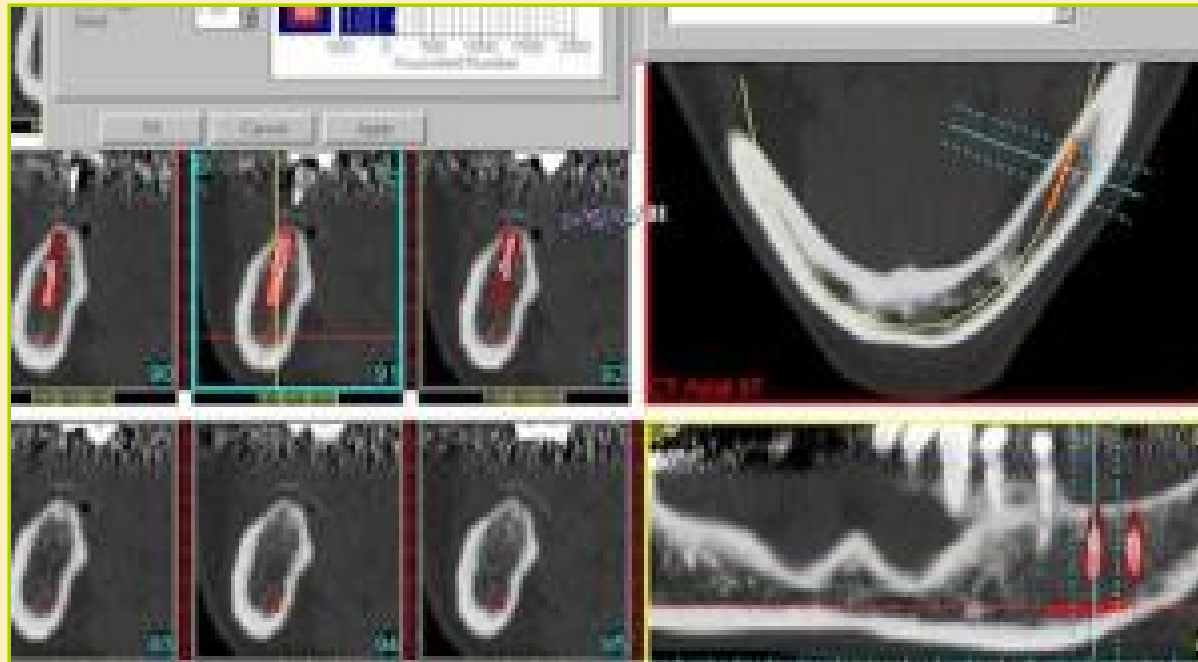


AMALGAMES INTRA-SINUSIENS



Sinusite
Aspergillaire

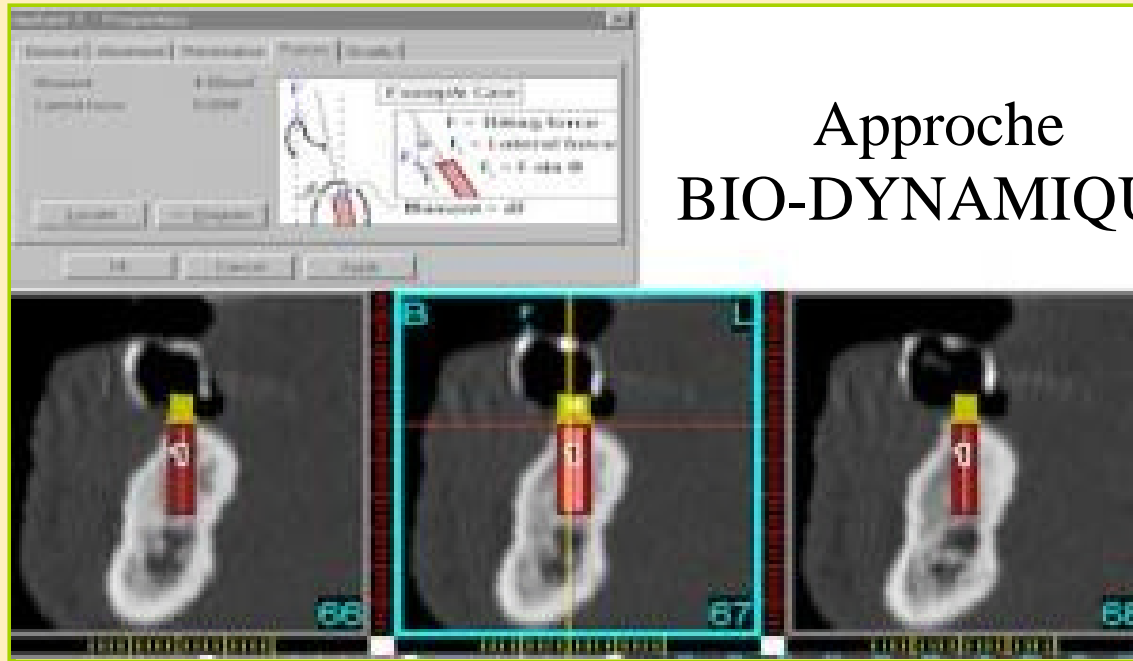
LES LOGICIELS DE C.A.D



Etude
QUALITATIVE
de l' OS
(1 mm)

*Simplant**

LES LOGICIELS DE C.A.D



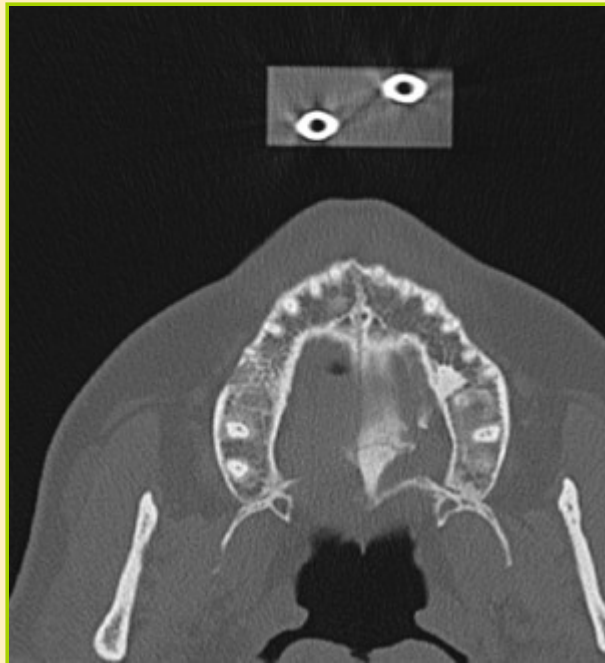
Approche BIO-DYNAMIQUE

- Angle de TRANSITION (axe prothèse/verticale)
- Porte-a-faux vertibulo-lingual
- Hauteur couronne
- Tissus mous

*Simplant**

APPLICATION PRATIQUE:

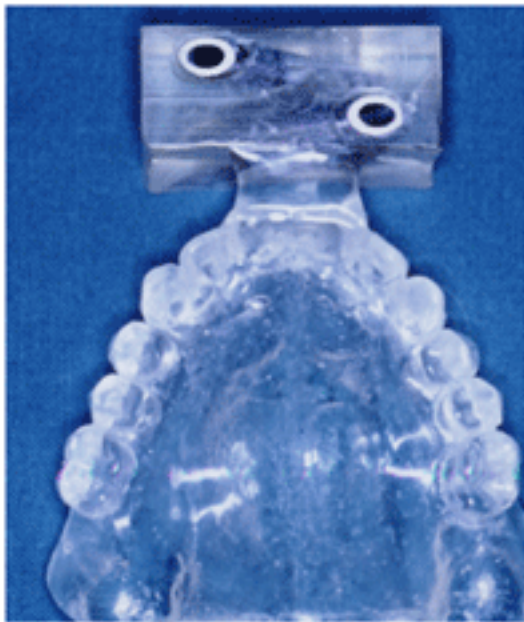CAD-Implant (Praxim)



- Coupes axiales
- Repère solide d' une gouttière
- Coupes axiales (plan d' occlusion)
- Images DICOM seules sur CD

APPLICATION PRATIQUE:

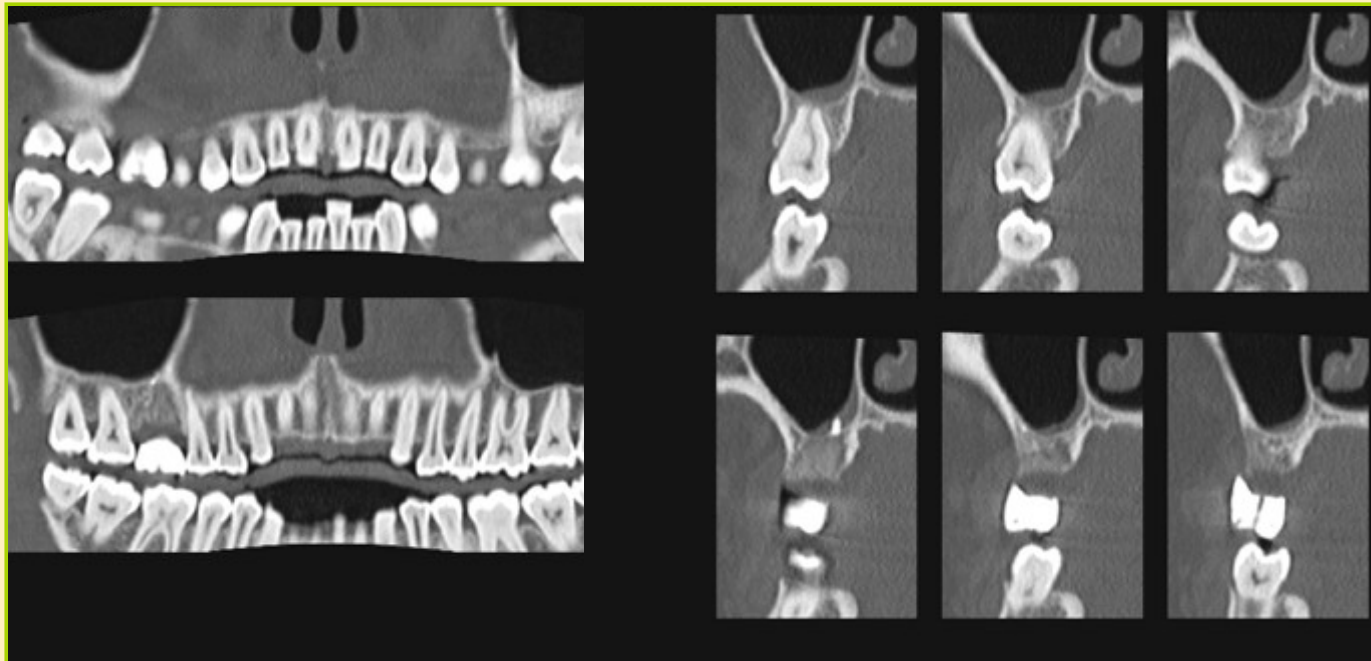
CAD-Implant (Praxim)



- Coupes axiales
- Repère solide d'une gouttière
- Coupes axiales (plan d'occlusion)
- Images DICOM seules sur CD

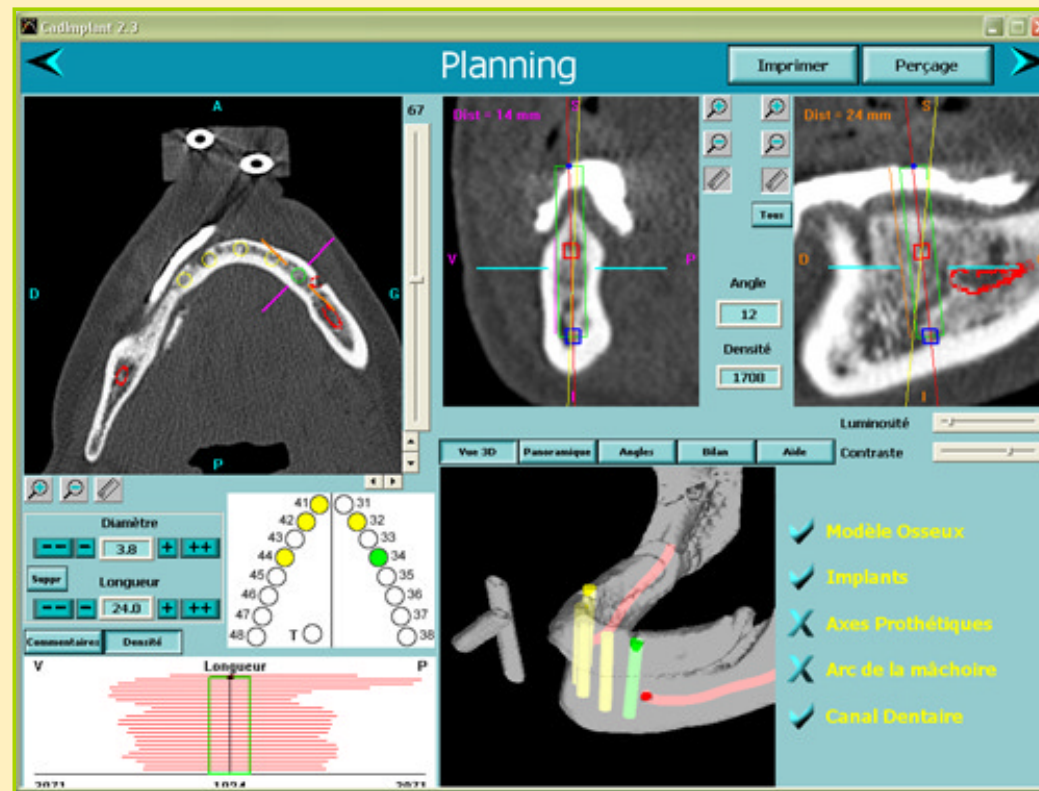APPLICATION PRATIQUE:

CAD-Implant (Praxim)



APPLICATION PRATIQUE:

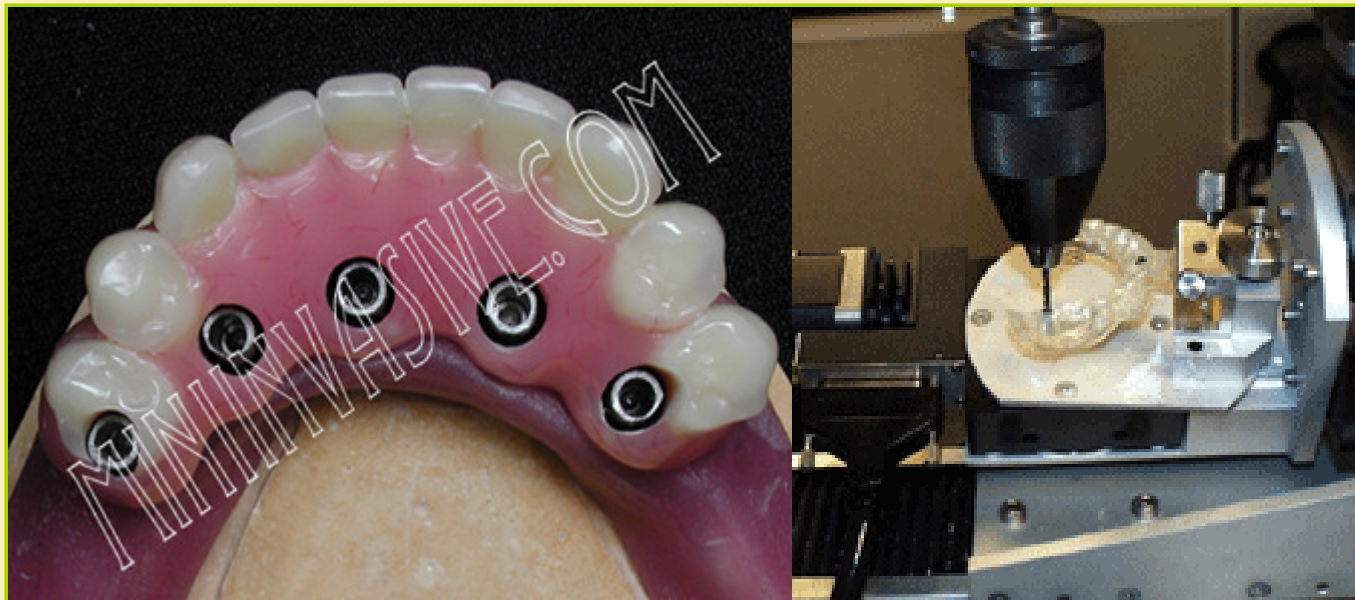CAD-Implant (Praxim)



PLANNING sur PC au cabinet

APPLICATION PRATIQUE:

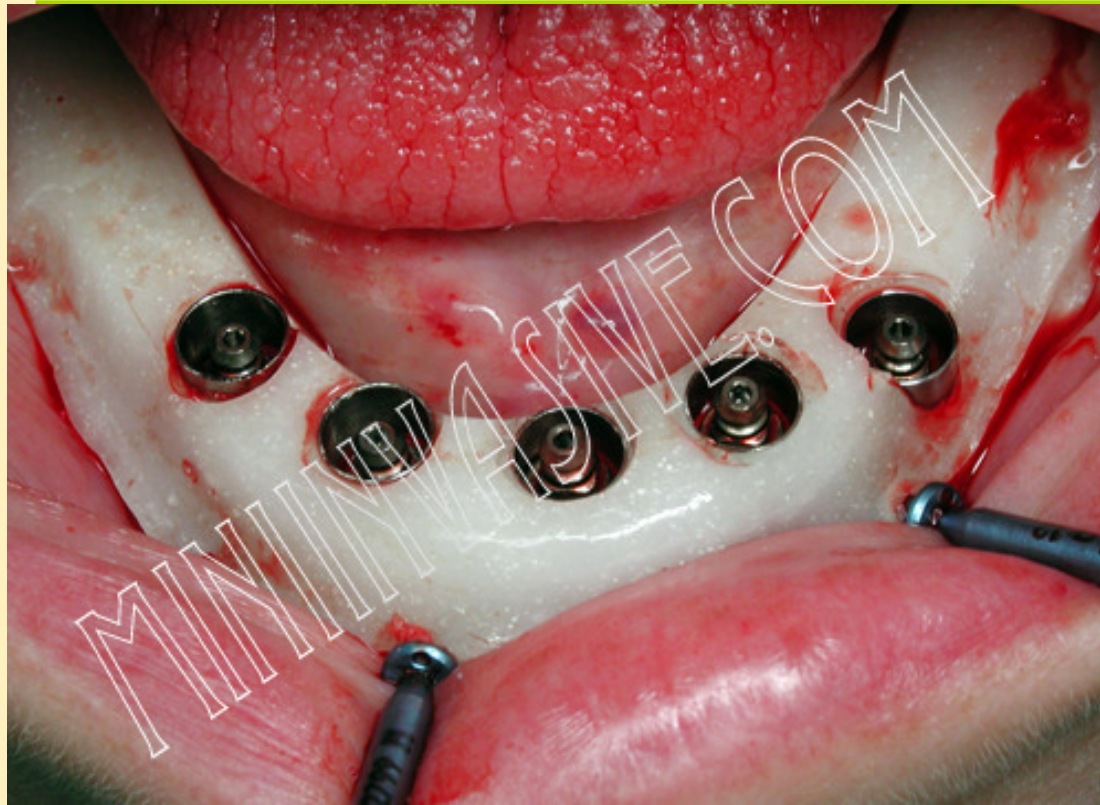CAD-Implant (Praxim)



GUIDE de PERCAGE

APPLICATION PRATIQUE:

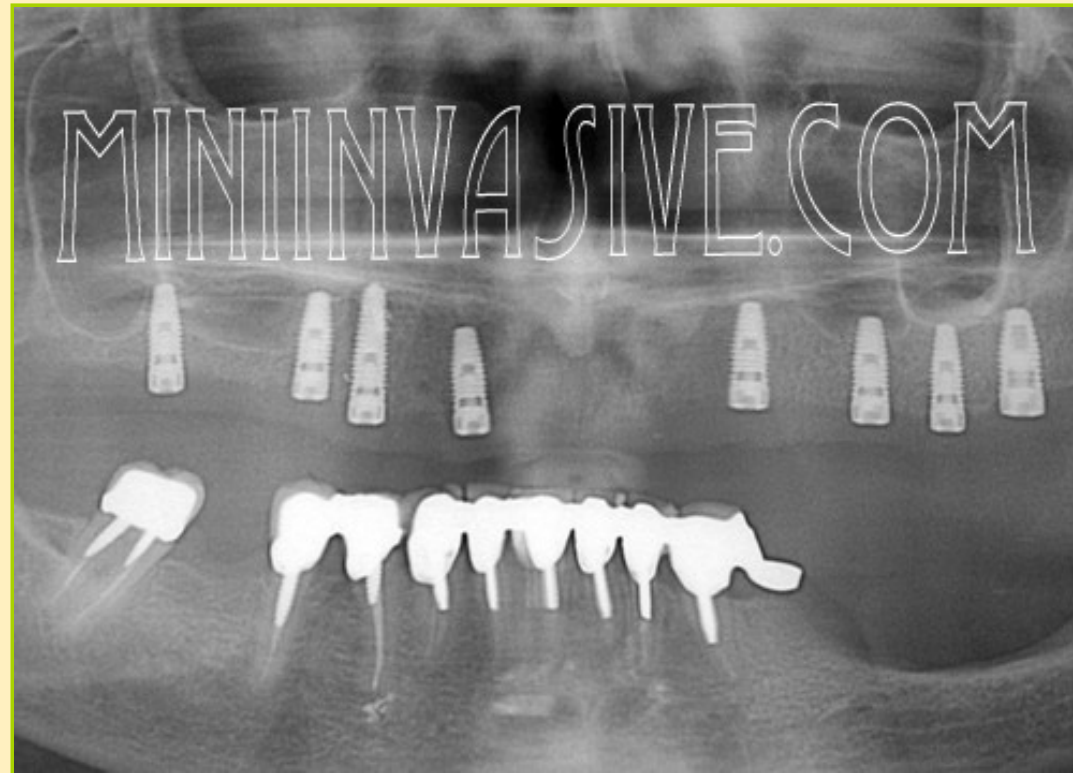CAD-Implant (Praxim)



Mise en place grâce au guide

APPLICATION PRATIQUE:

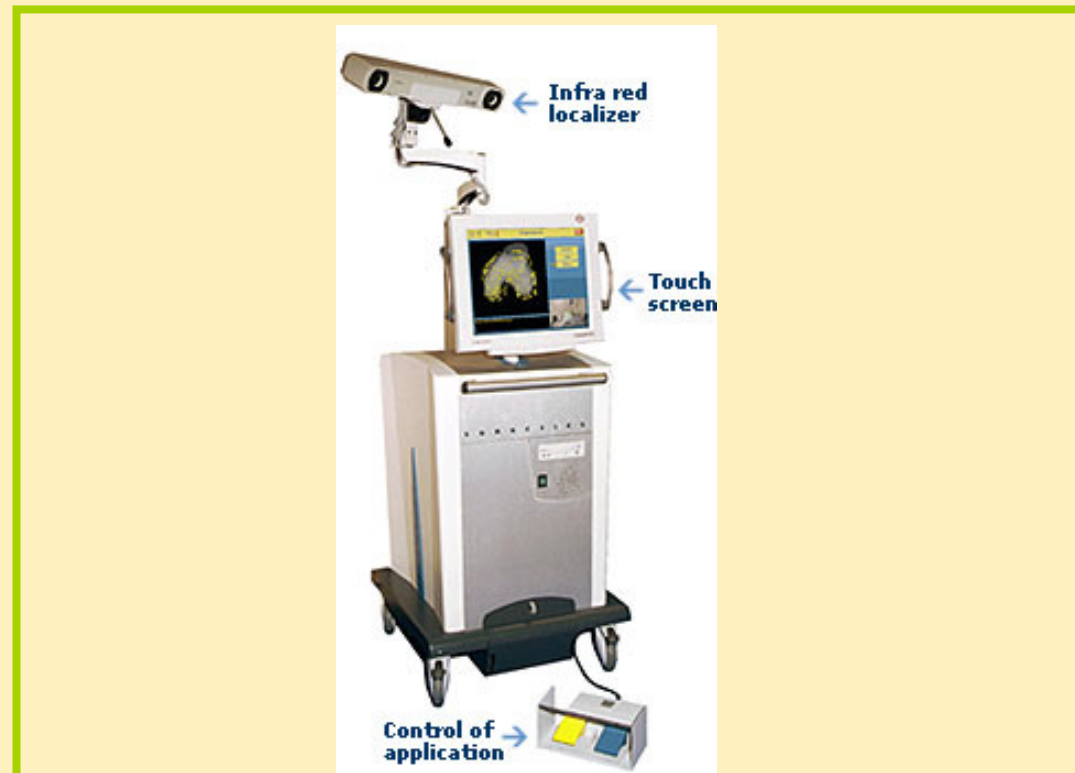CAD-Implant (Praxim)



IDEAL pour les IMPLANTATIONS ETENDUES

L' AVENIR (?)

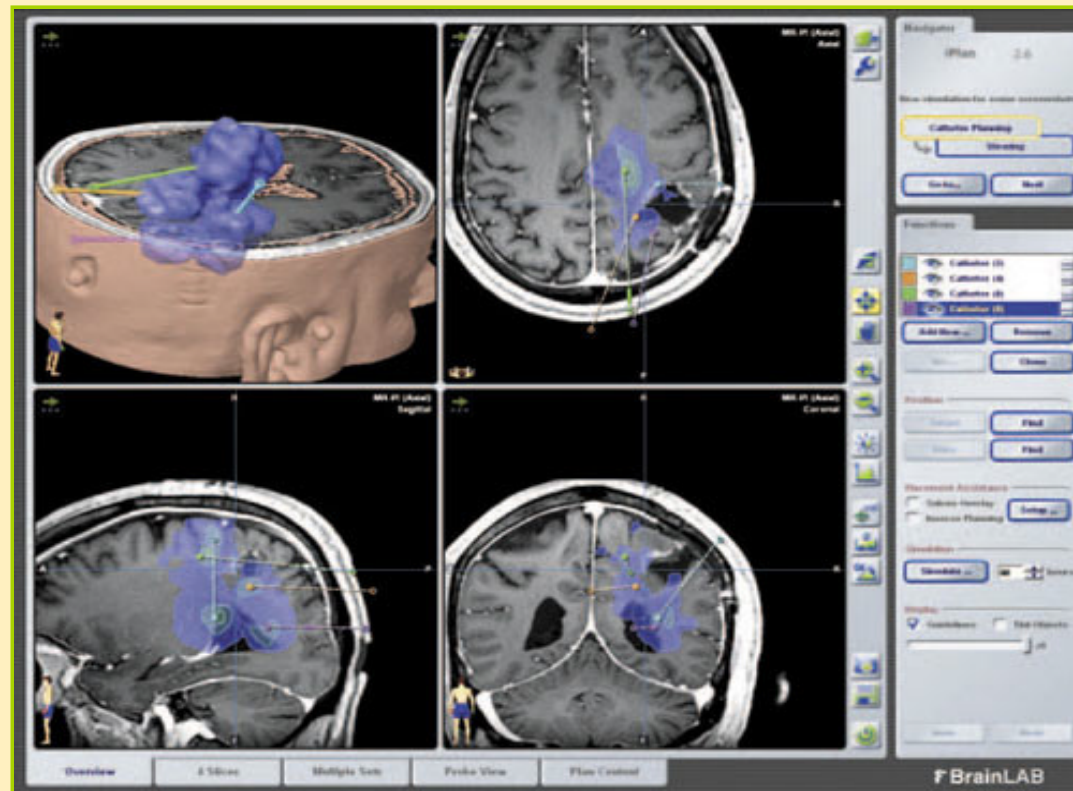
IMPLANTATION SOUS NAVIGATION



Dérivé de la NEUROCHIRURGIE

L'AVENIR (?)

IMPLANTATION SOUS NAVIGATION

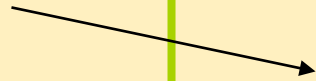

Dérivé de la NEUROCHIRURGIE

L'AVENIR (?)

IMPLANTATION SOUS NAVIGATION

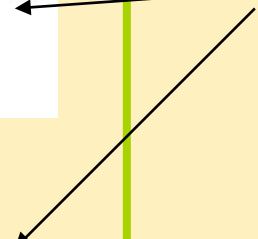
INFRA-ROUGE



Console/PC



Instruments
CALIBRES



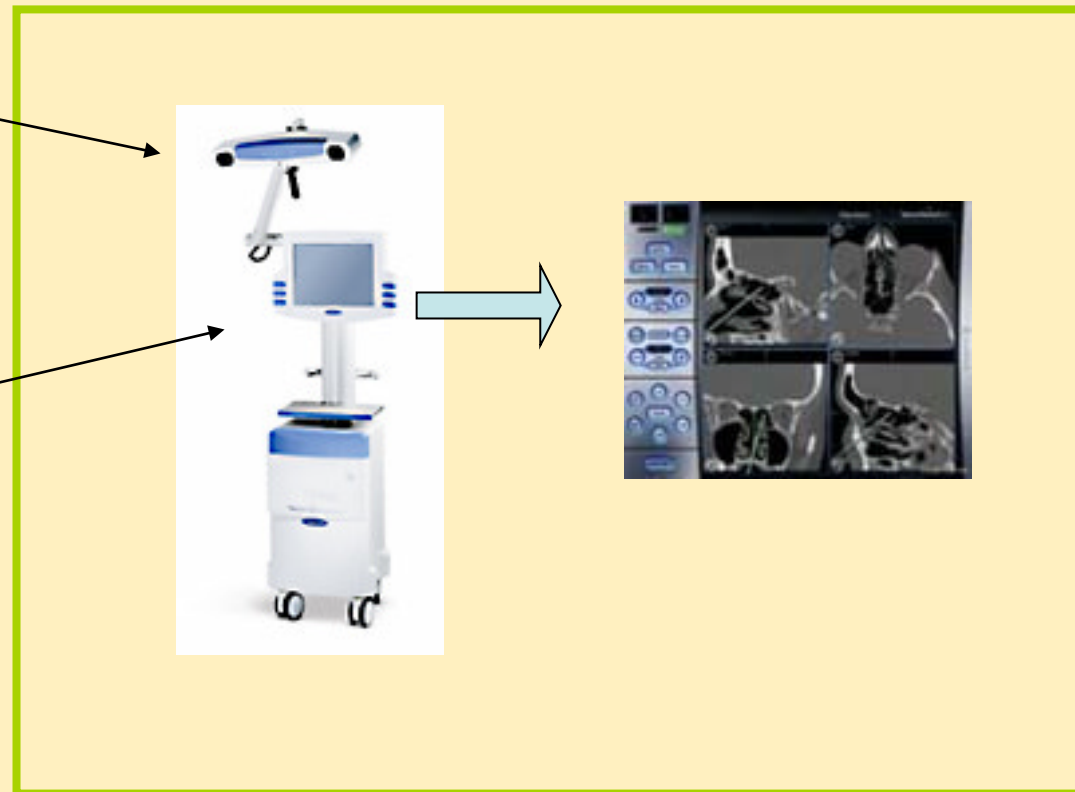
Orthopédie, ORL, IMPLANTS

L'AVENIR (?)

IMPLANTATION SOUS NAVIGATION

INFRA-ROUGE

Console/PC



Orthopédie, ORL, IMPLANTS

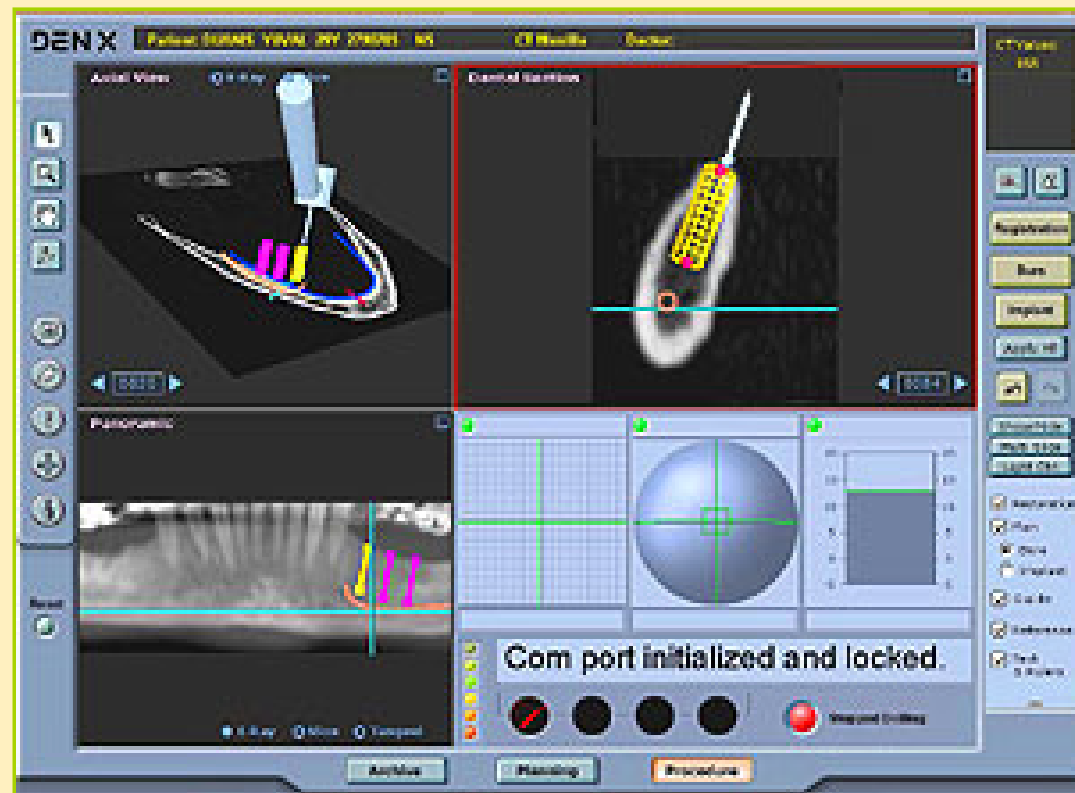L'AVENIR (?)

IMPLANTATION SOUS NAVIGATION



L' Avenir (?)

IMPLANTATION SOUS NAVIGATION



SYNTHESE 1

- PANO: débrouillage...ou cas évidents
- SCANNER: devient presque
INCONTOURNABLE
- ...surtout si vous utilisez un
LOGICIEL

LIMITES DU SCANNER

- PRIX ? (150 euros env.)
- Disponibilité
- Radiologue
- IRRADIATION

IRRADIATION


- le SCANNER
 - 10% des procédures radiologiques
 - 30% de l' irradiation médicale
- directive EURATOM
 - choisir la technique la moins irradiante
 - indication justifiée.

IRRADIATION

- 10 000 mSv: Décès
- 1000 mSv: signes cliniques
- 5 mSv: irradiation annuelle
à Clermont-Ferrand.
- 2,5 mSv: irradiation annuelle
à Paris.

IRRADIATION

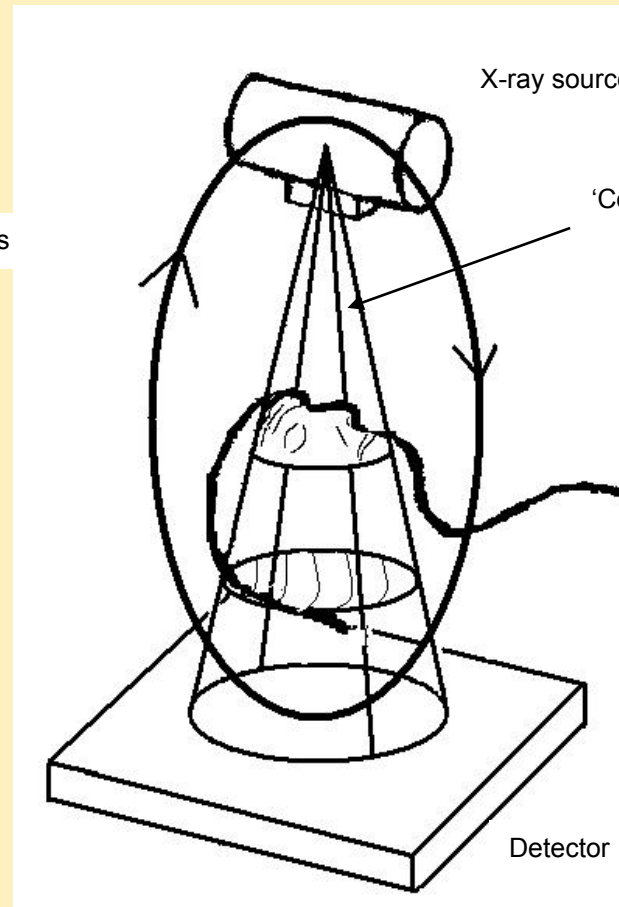
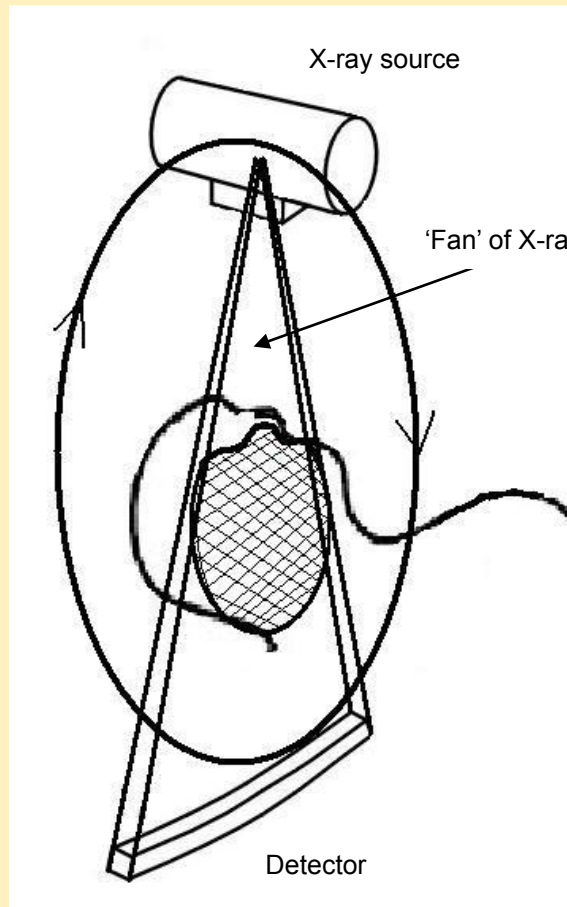
- 10 000 mSv: Décès
- 1000 mSv: signes cliniques
- 5 mSv: irradiation annuelle à Clermont-Ferrand.
- 2,5 mSv: irradiation annuelle à Paris.

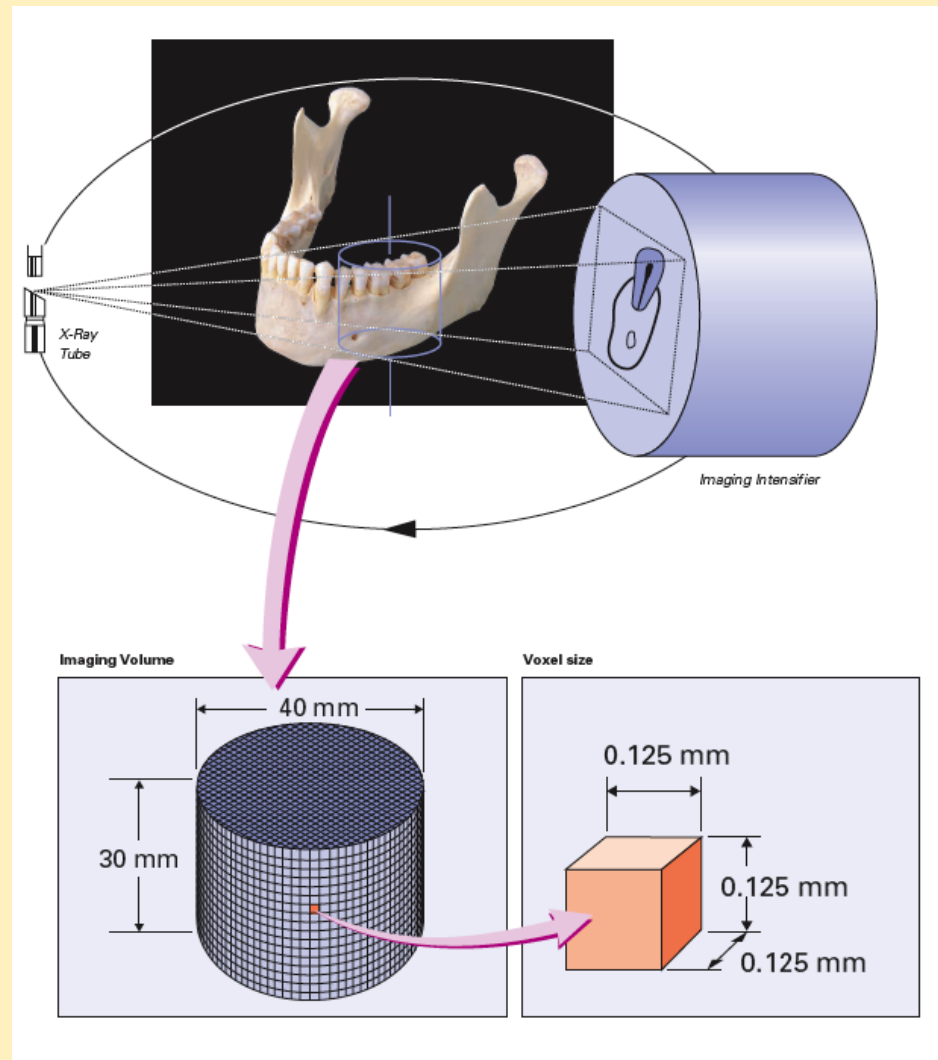


SCANNER
DENTAIRE:
2,5 mSv

LE « CBCT »
ou Cone Beam Computed
Tomography

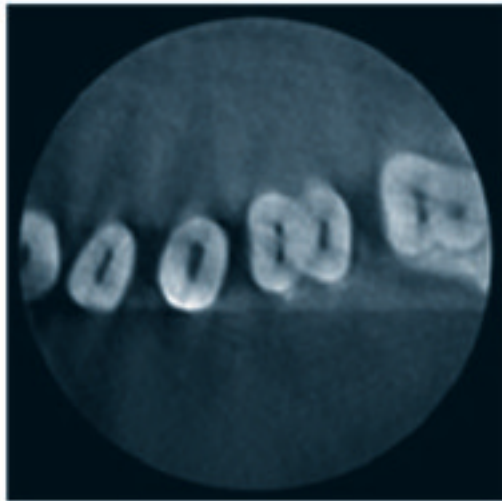
Principe du CBCT



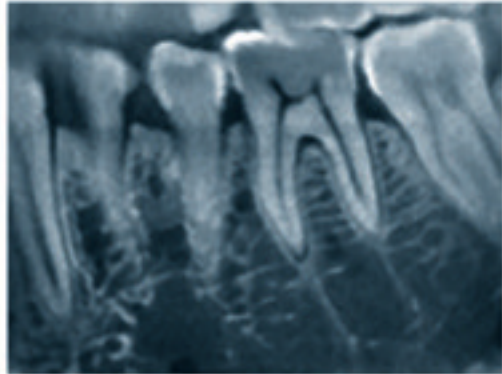
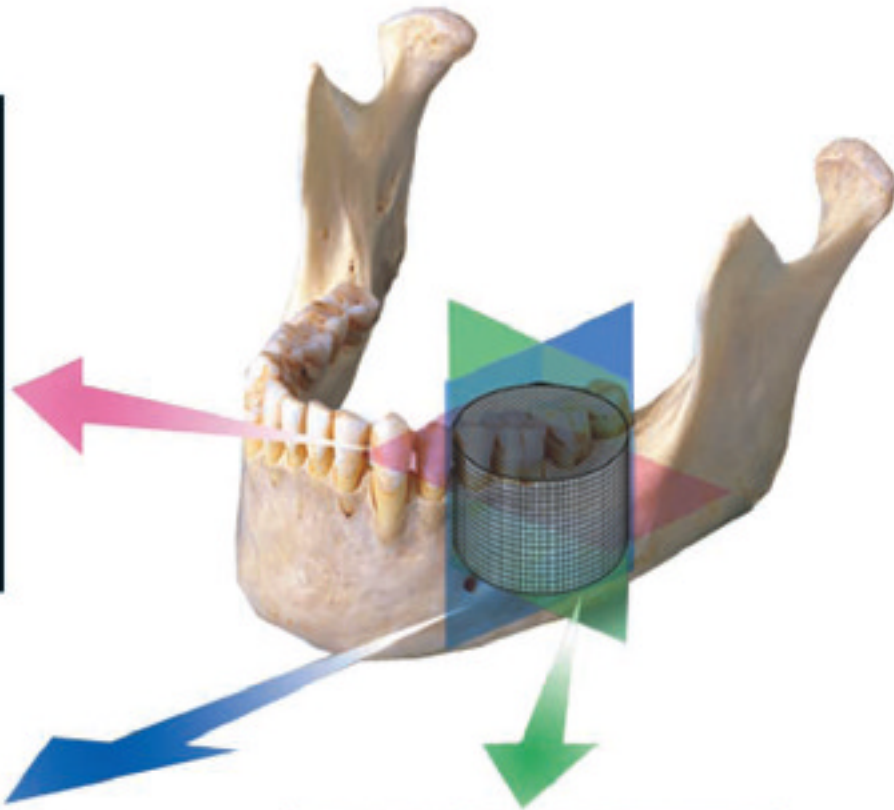


Acquisition d'un **VOLUME** (limité...)

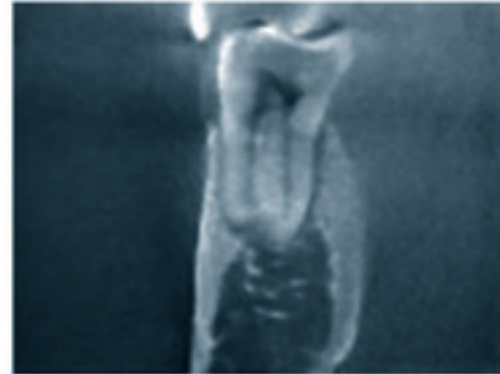
Reconstruction secondaire en **coupes** ou en **3D**



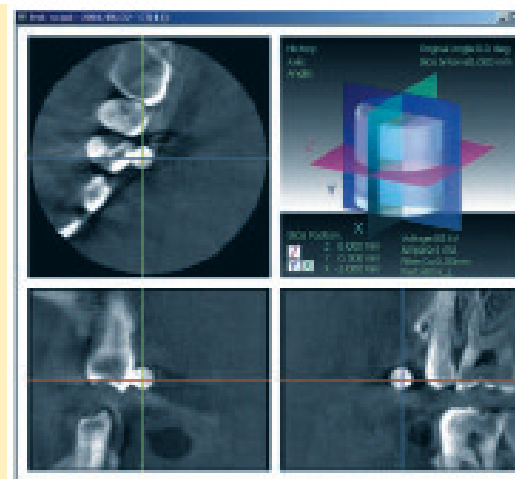
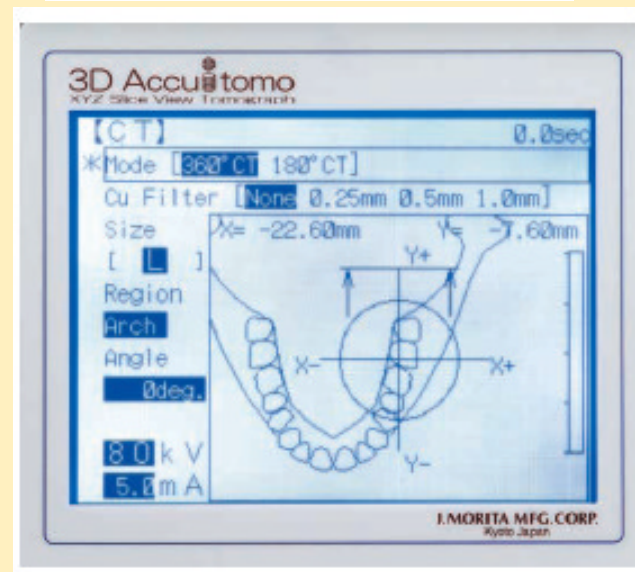
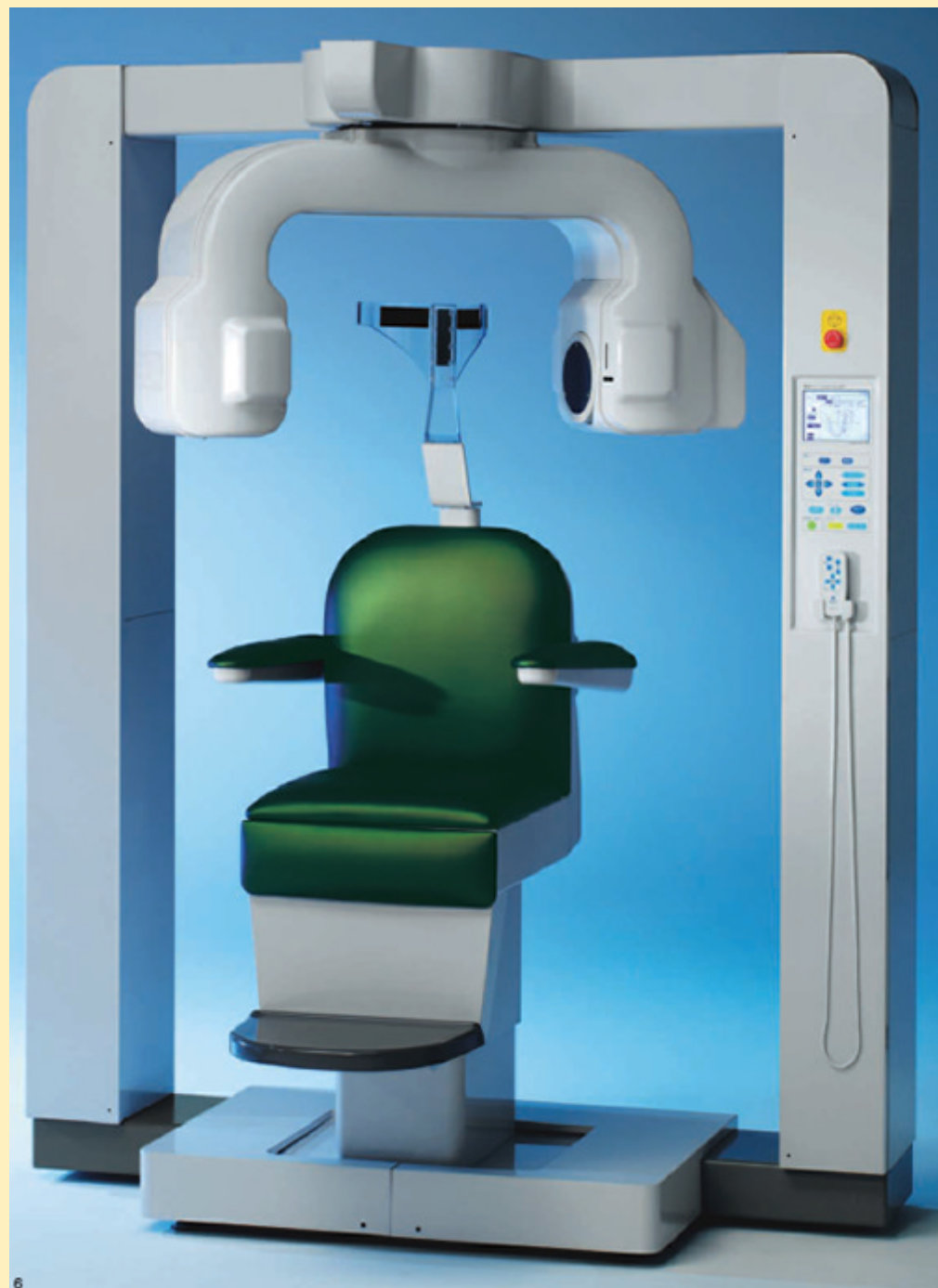Axial



Sagittal

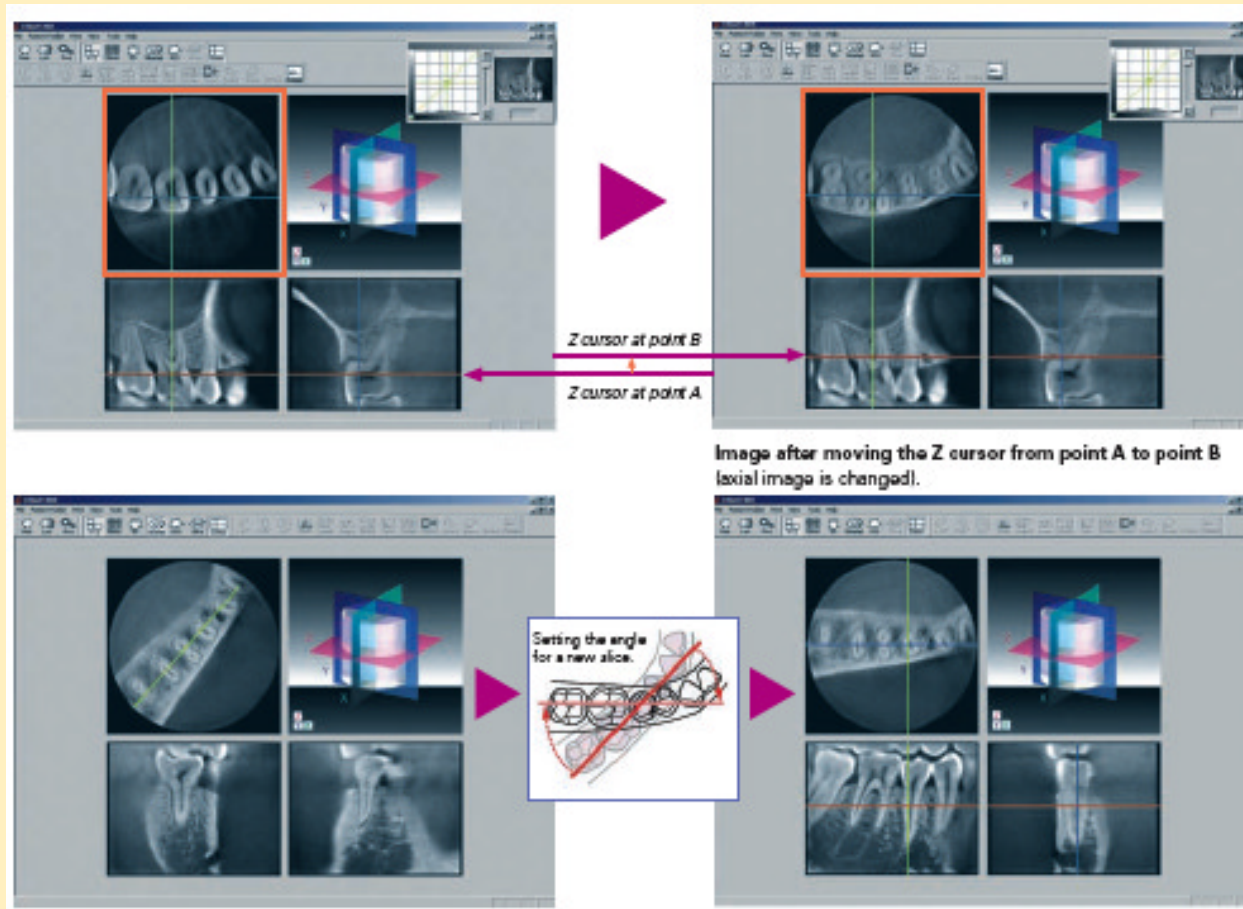


Coronal

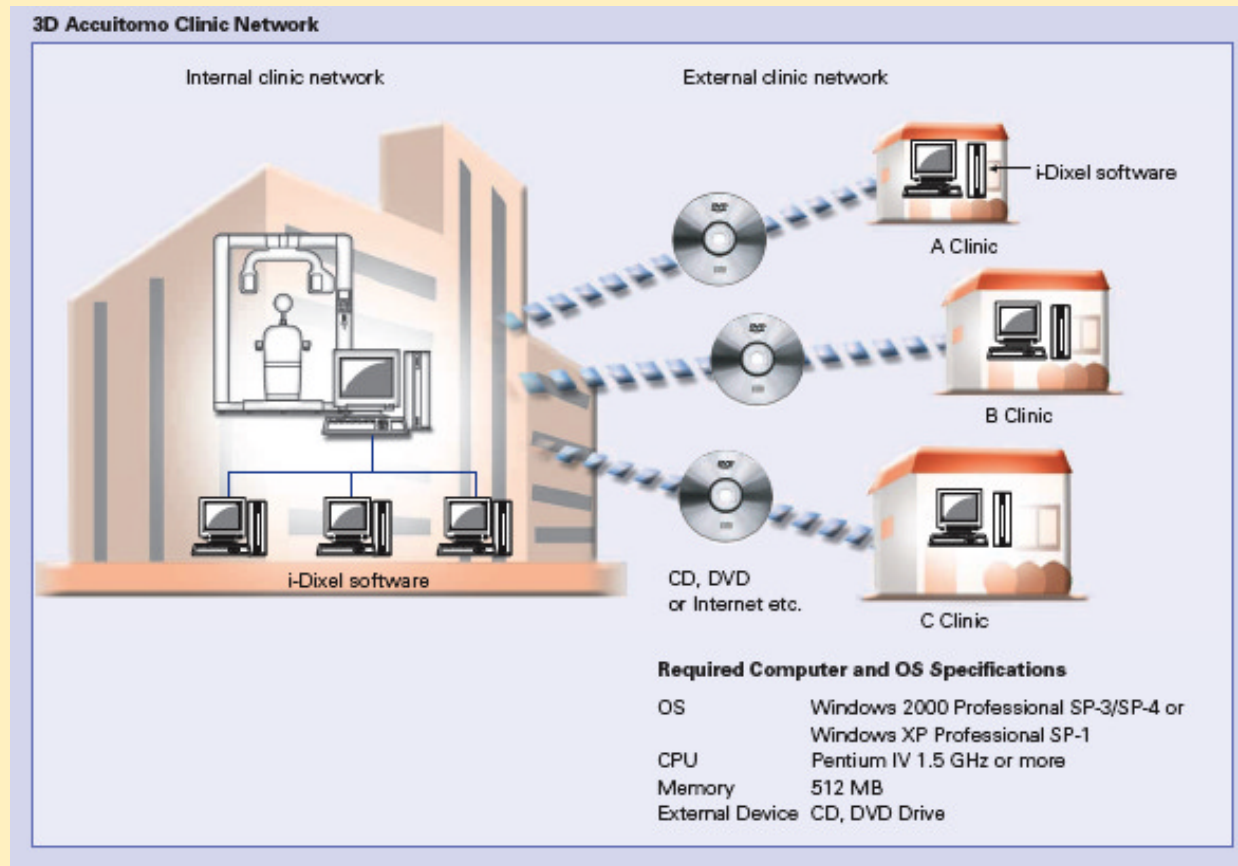


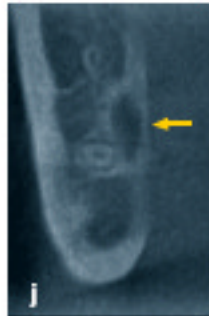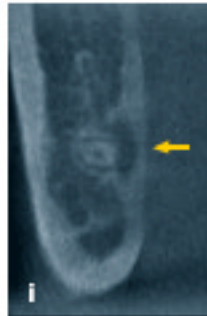
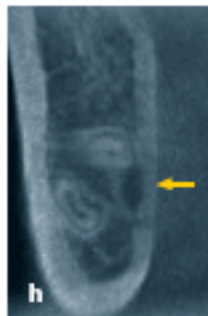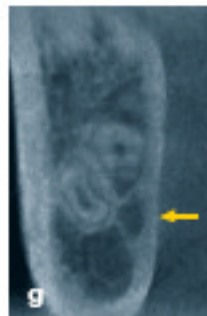
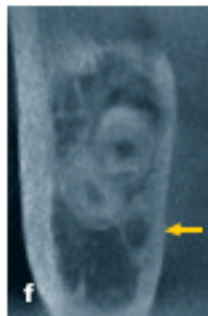
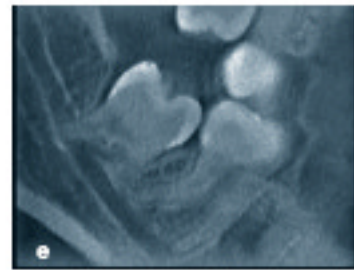
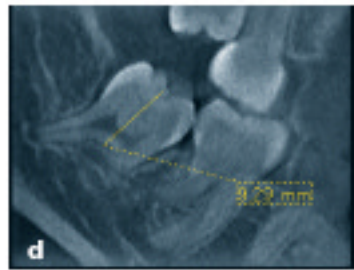
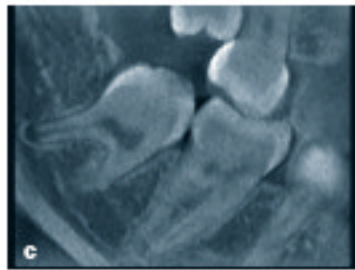
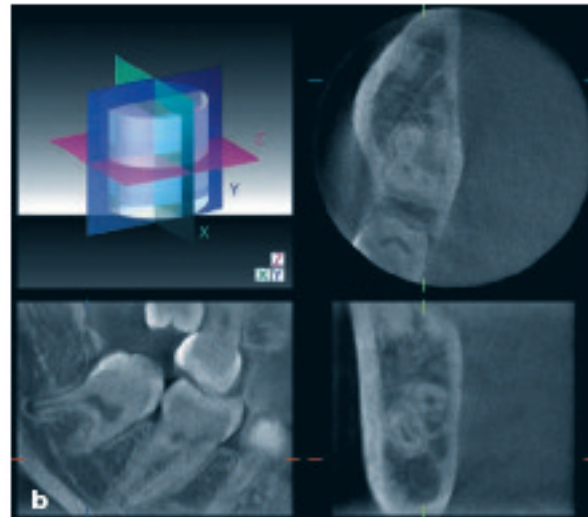


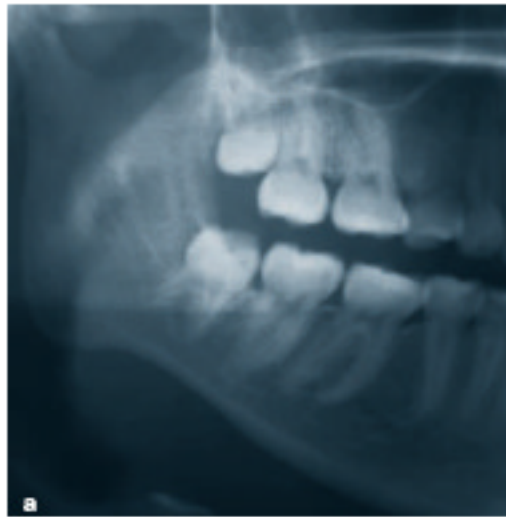Pilotage et Traitement d'images sur **console** PC

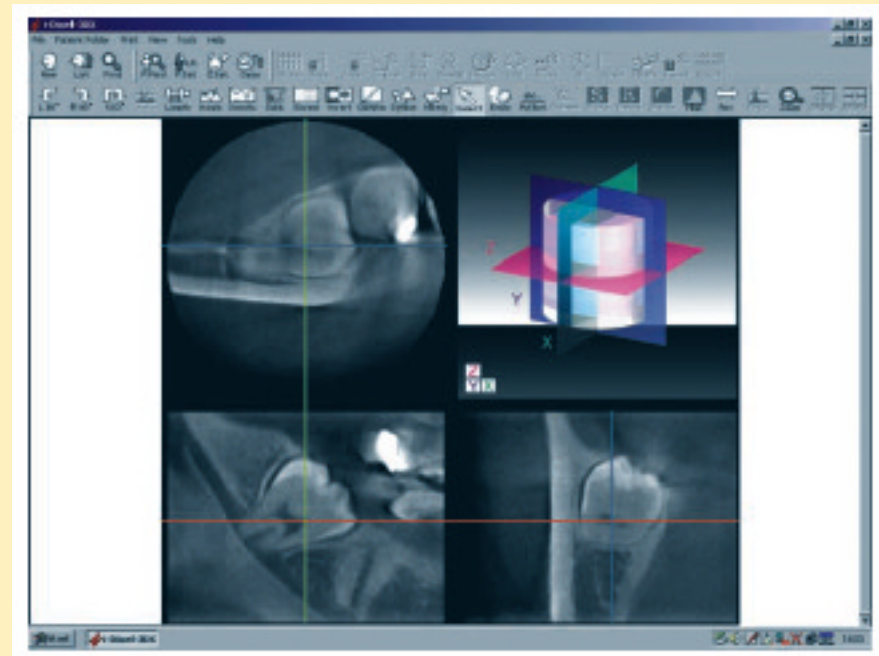
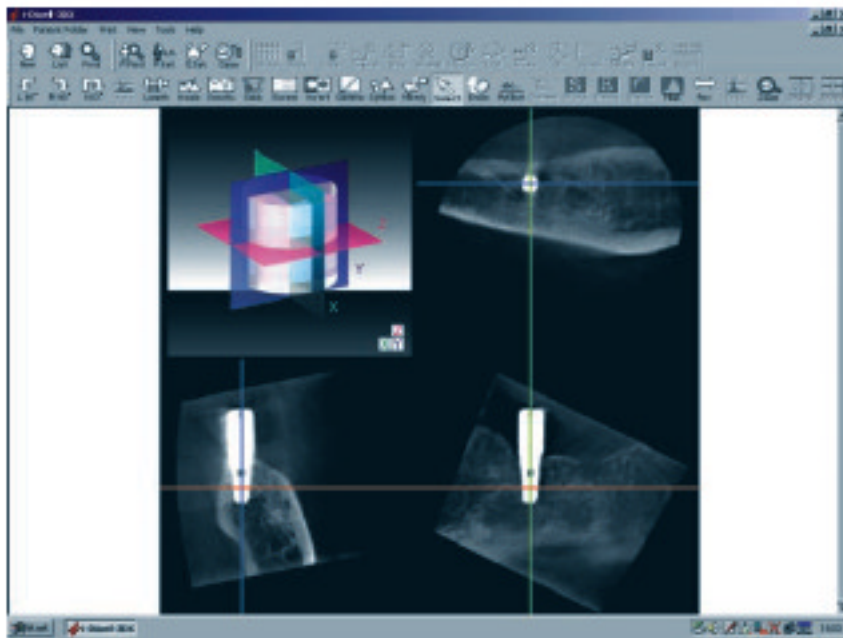
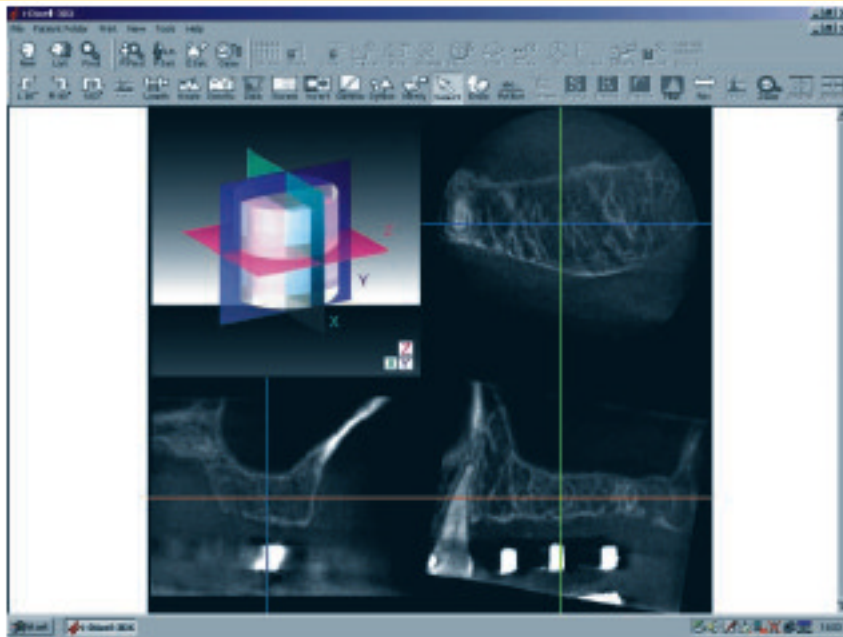


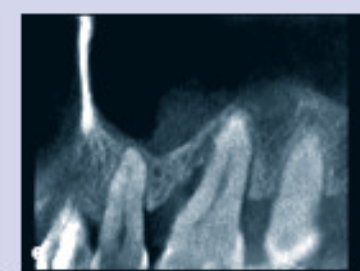
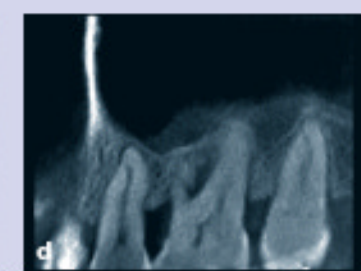
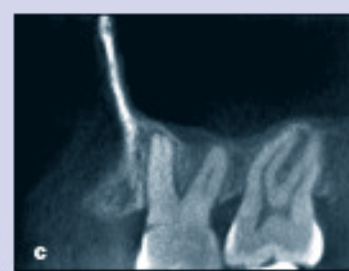
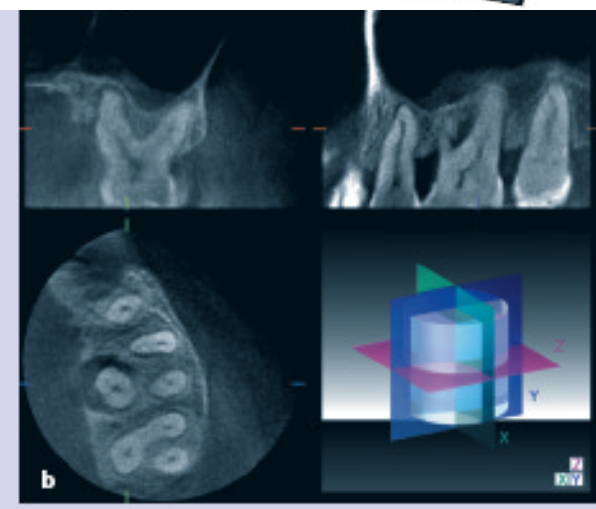
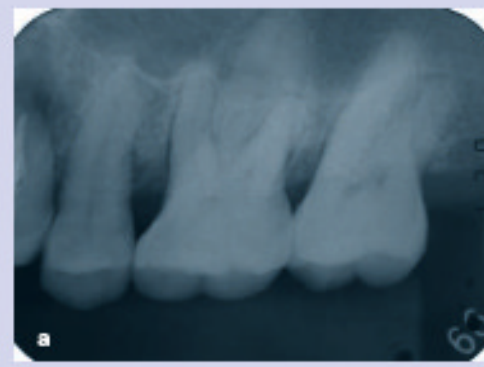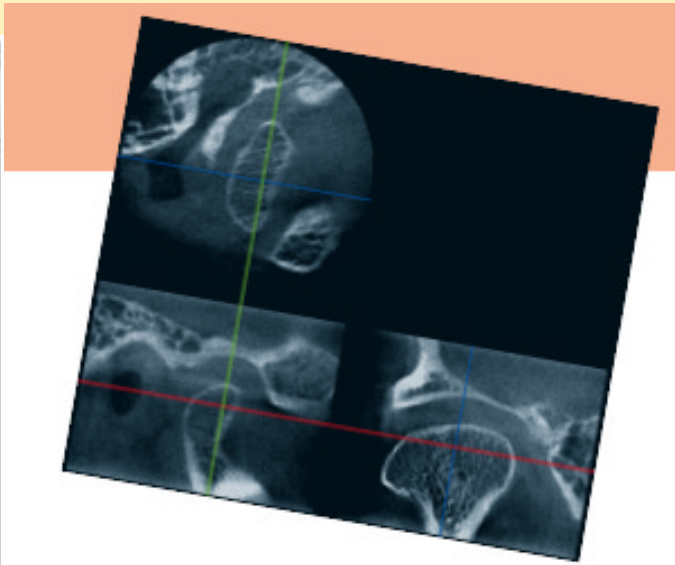
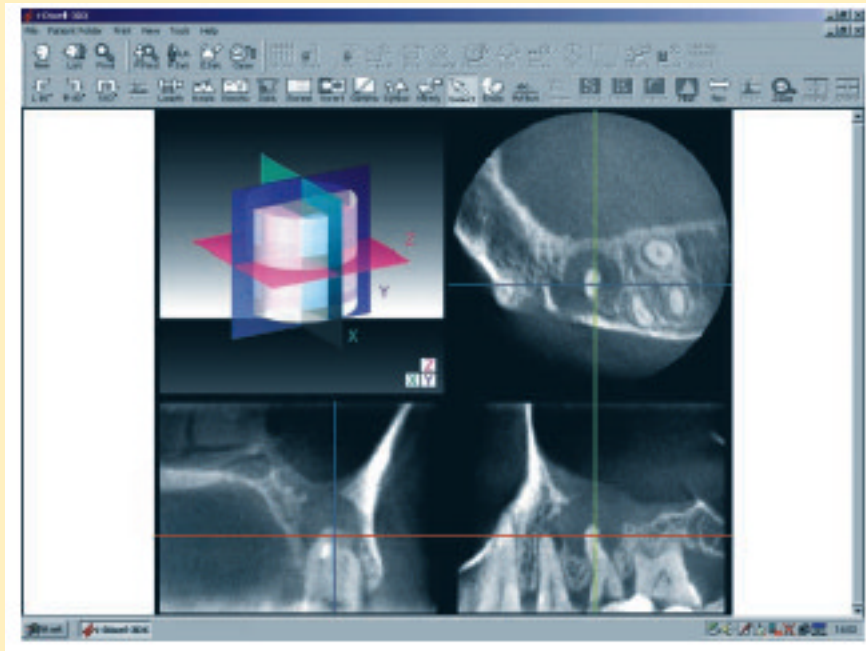
Images a la norme DICOM stockage, diffusion (réseau, CD...)





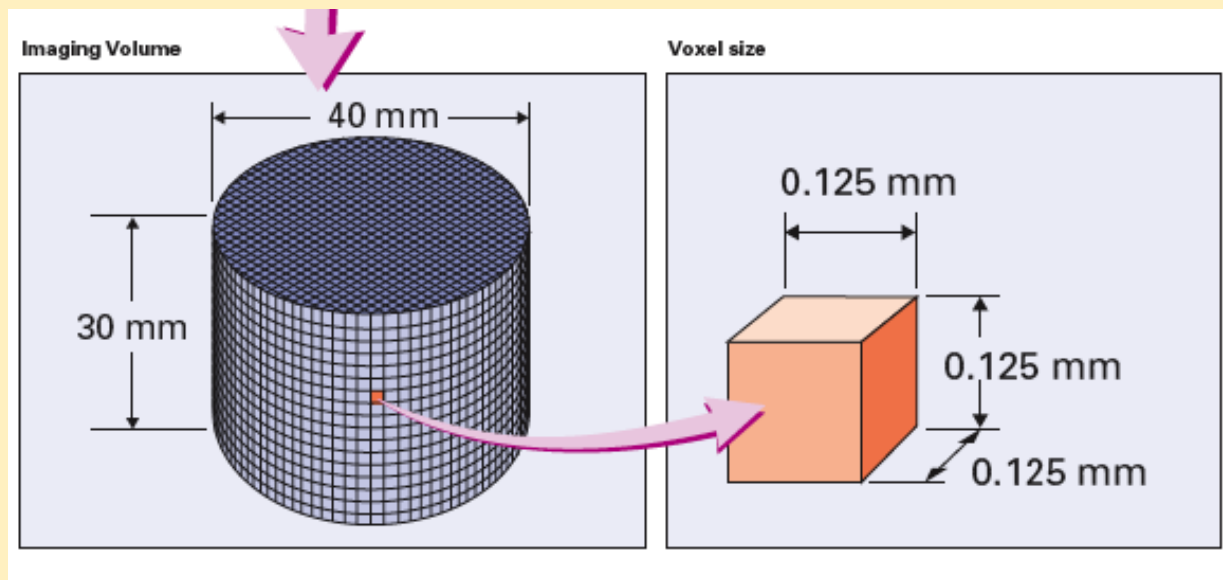
- Implantologie





Avantages du système CBCT

- Encombrement et ergonomie
- Budget (1/3 ou 1/4 du prix d'un scanner)
- Définition: 0,125 mm (scanner : 0,24 mm)



Avantages du système CBCT

- Réduction de l' irradiation*
 - Scanner dentaire : 250 micro.sV
 - CBCT: 50 micro.sV
 - Pano: 4 micro.sV

**Computed Tomography Radiation Safety
Issues in Ontario
Healthcare Human Factors Group
Centre for Global eHealth Innovation
University Health Network
Toronto, ON, Canada
June 16, 2006*

Avantages du système CBCT

- Réduction de l' irradiation (microSv)
 - Rétroalvéolaire 5
 - Télécrâne: 2,5
 - Panoramique 10 à 30
 - CBCT 60à 200
 - TDM (optimisé) 200 à 300

- Ludlom et coll.Dentomaxillofacial Radiology (2003) 32, 229-234

Limites du système CBCT

- Système dédié et limité à l'étude dentaire
- Taille du champ d'exploration limitée



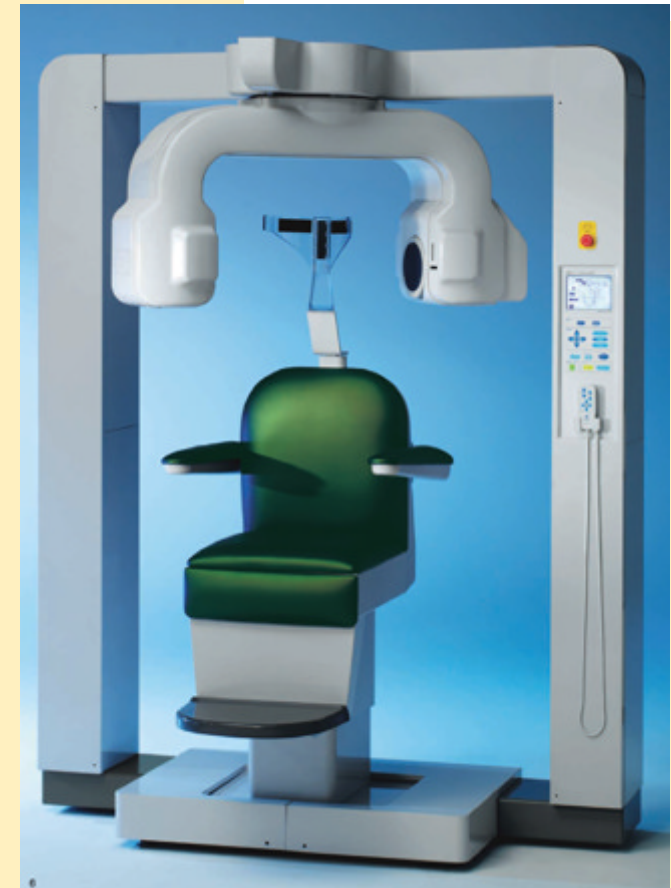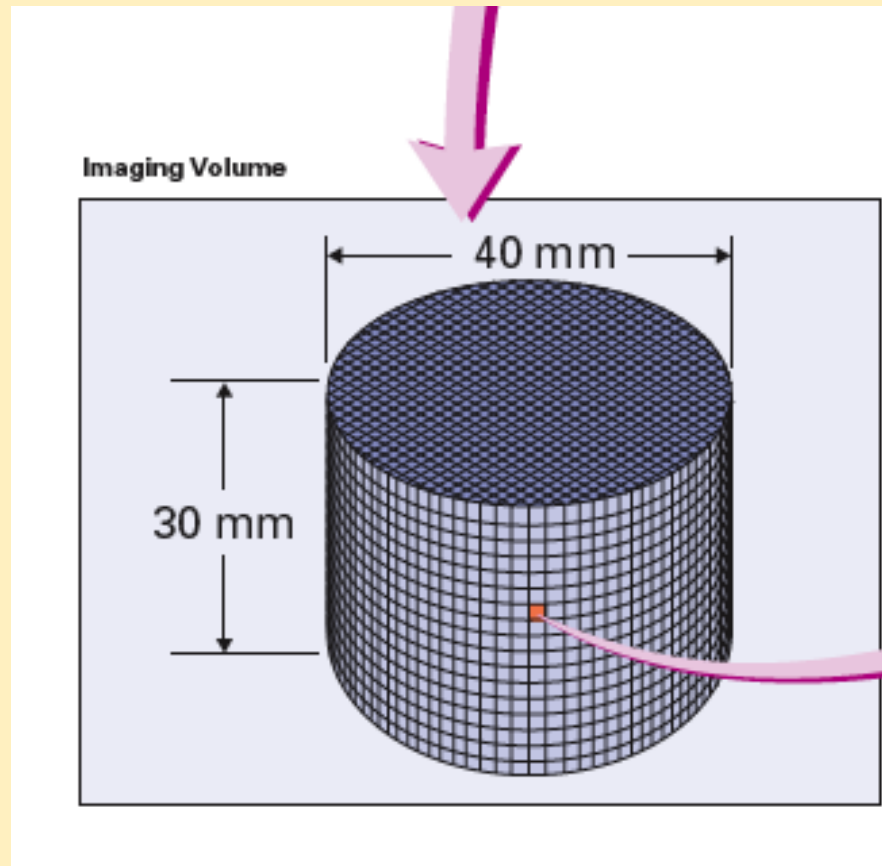
CBCT: 1' offre

- Morita (jpn): **Accuitomo 3D**
- Imaging sciences int (usa): **I-Cat**
- Planmeca (fin): **ProMax 3D**
- QR (it): **NewTom 3G et VG**

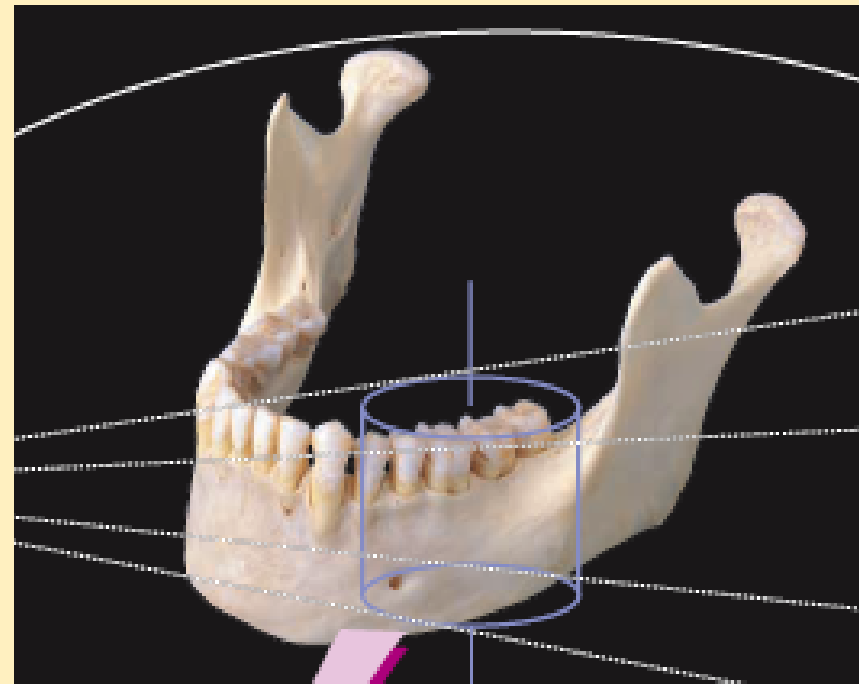
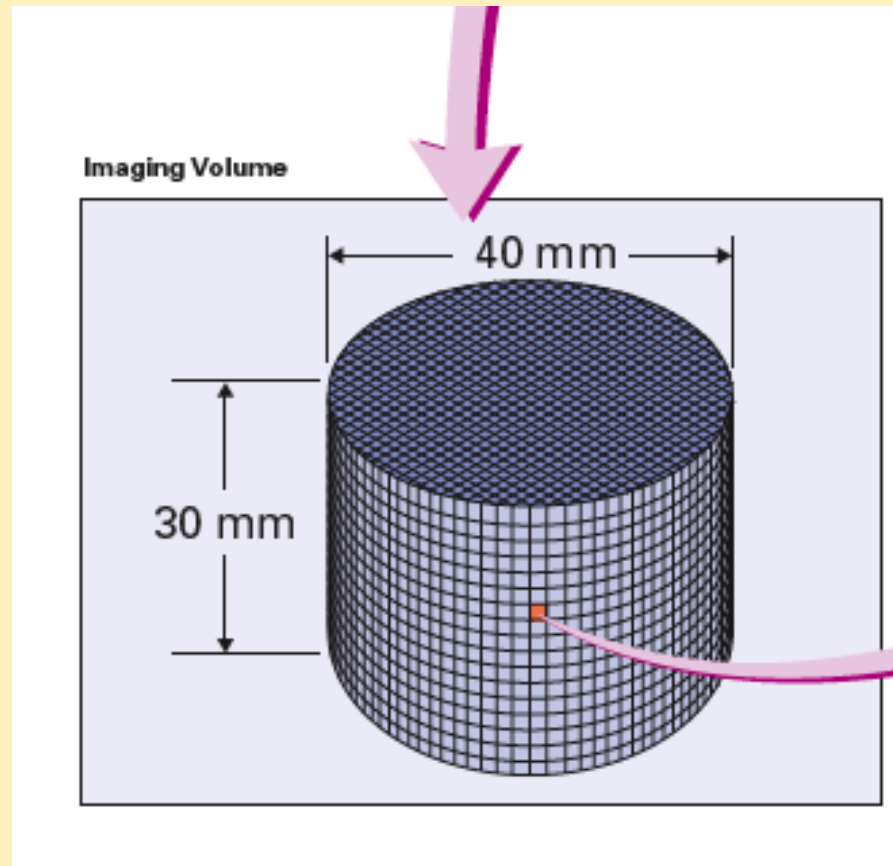
ACCUITOMO 3D



MORITA



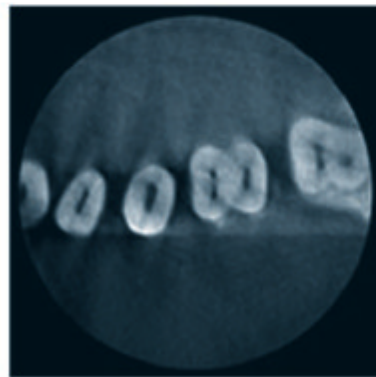
ACCUITOMO 3D



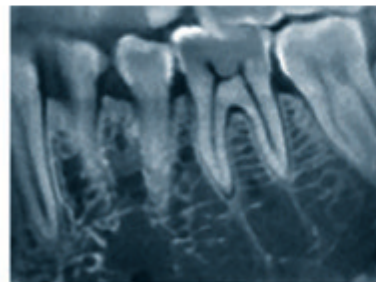
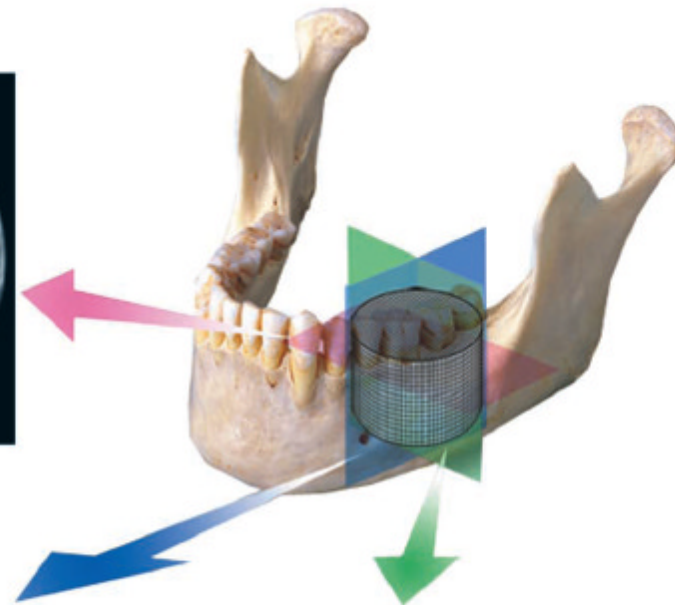
ACCUITOMO 3D



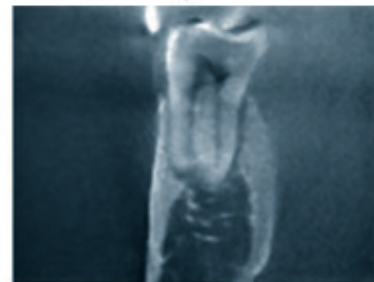
MORITA



Axial



Sagittal



Coronal

I-CAT

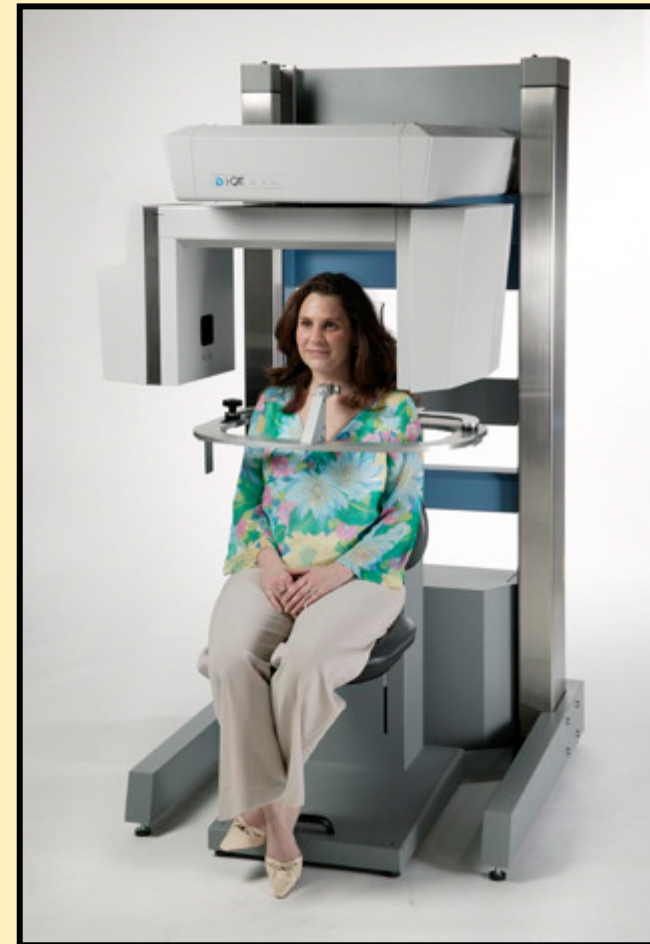
Imaging
Sciences
International 

Même architecture

Même résolution (0,125 mm)

Même dose (68 microSv)

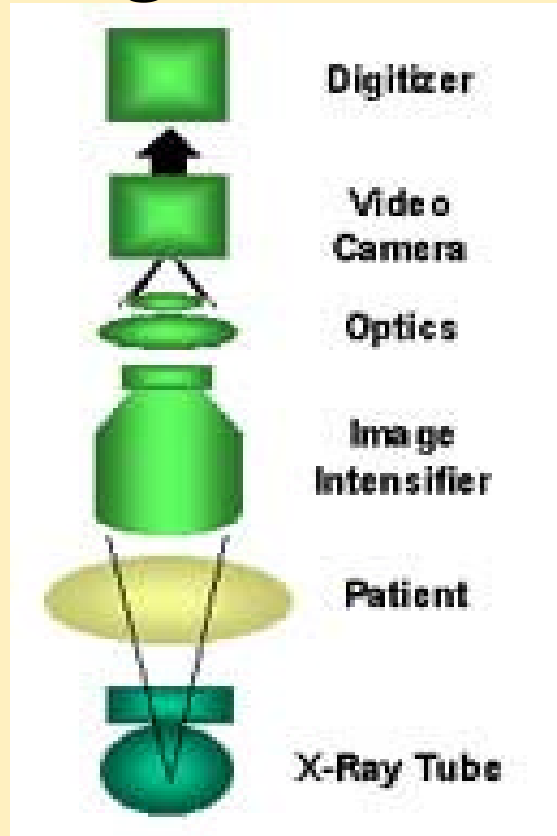
Principe un peu différent



I-CAT

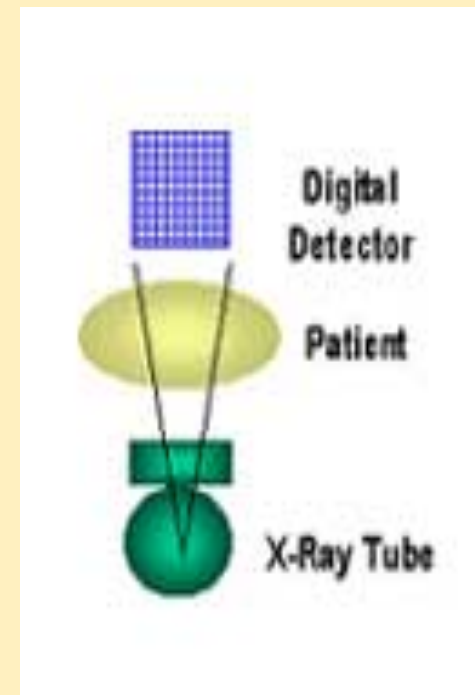


Image Intensifier



Used by other cone beam
CT units

Flat Panel




Used only by i-CAT

I-CAT



- **16cm x 13cm** **0.4, 0.3, 0.25mm**
- **16cm x 8cm** **0.4, 0.3, 0.25, 0.2mm**
- **16cm x 6cm** **0.4, 0.3, 0.25, 0.2mm**
- **16cm** **0.4, 0.3, 0.25, 0.2mm**



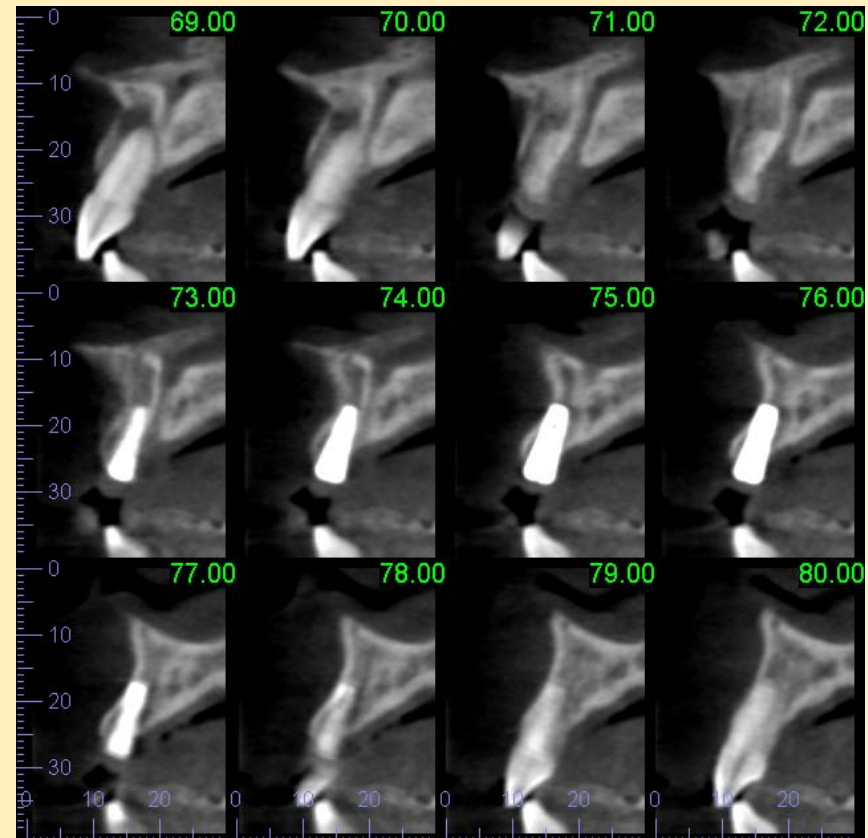
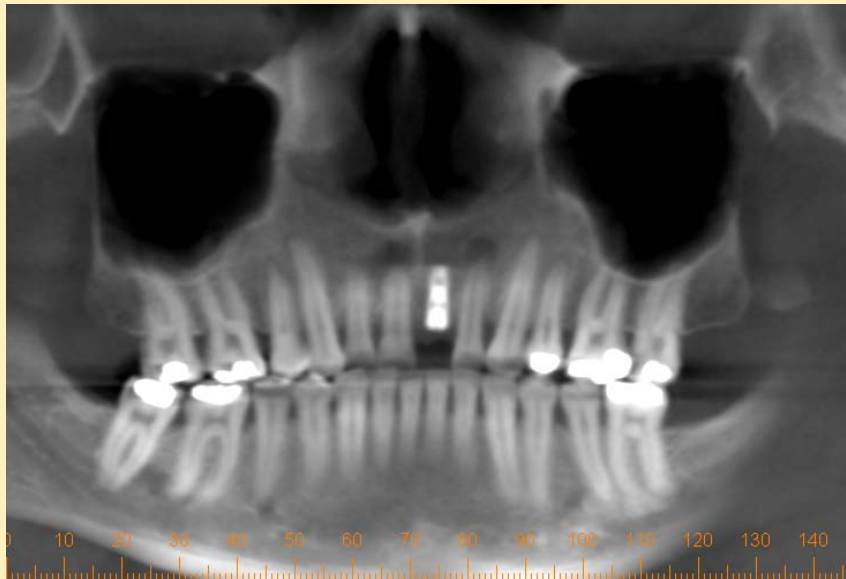
GRAND CHAMP !!



I-CAT

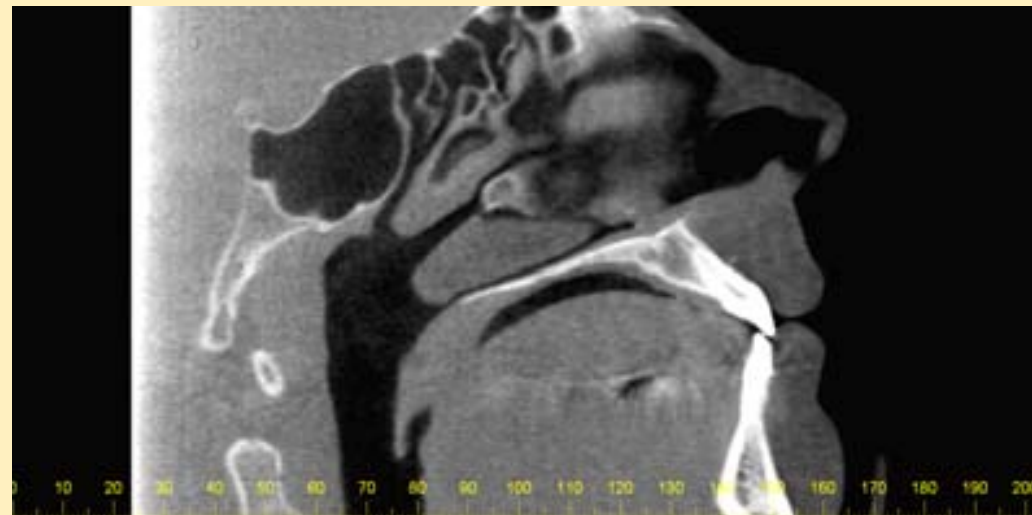
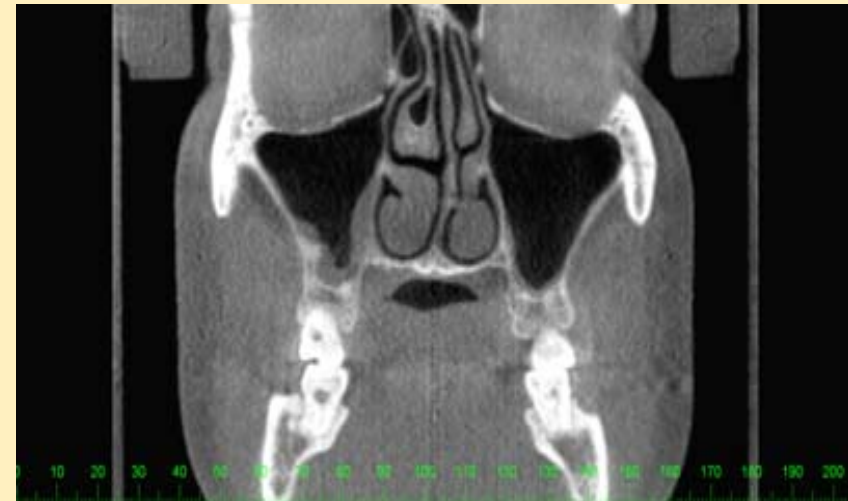
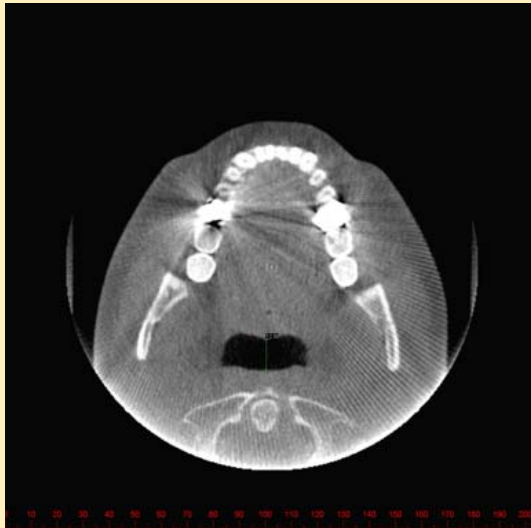
GRAND CHAMP !!



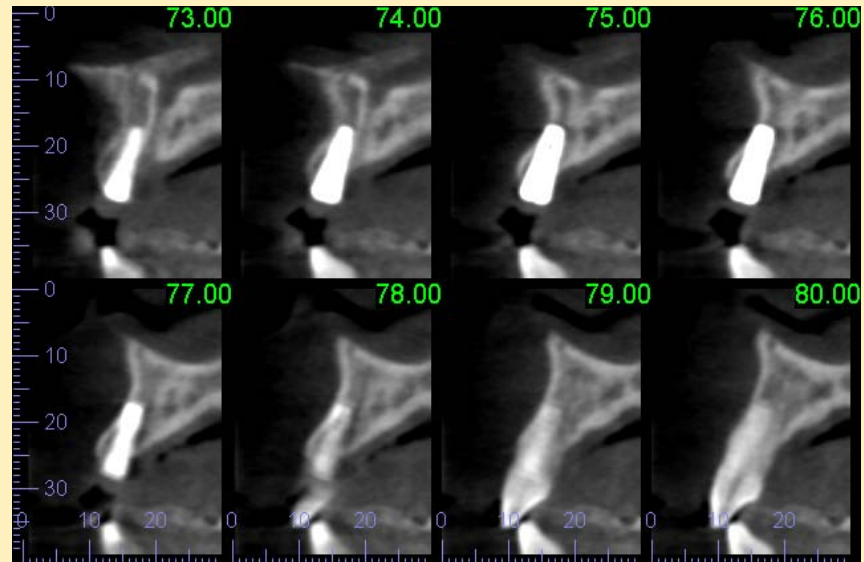
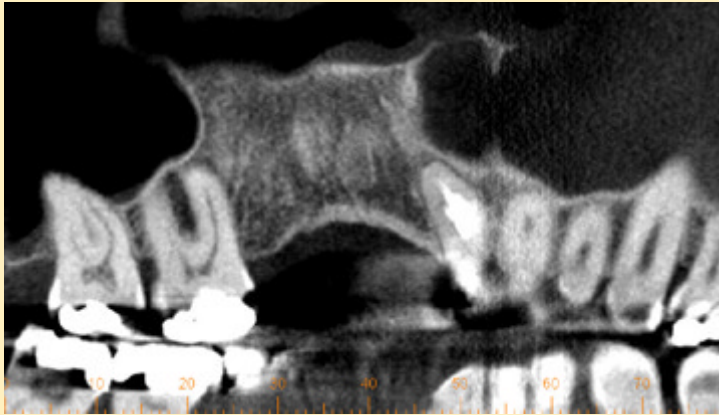
I-CAT

Imaging
Sciences
International 

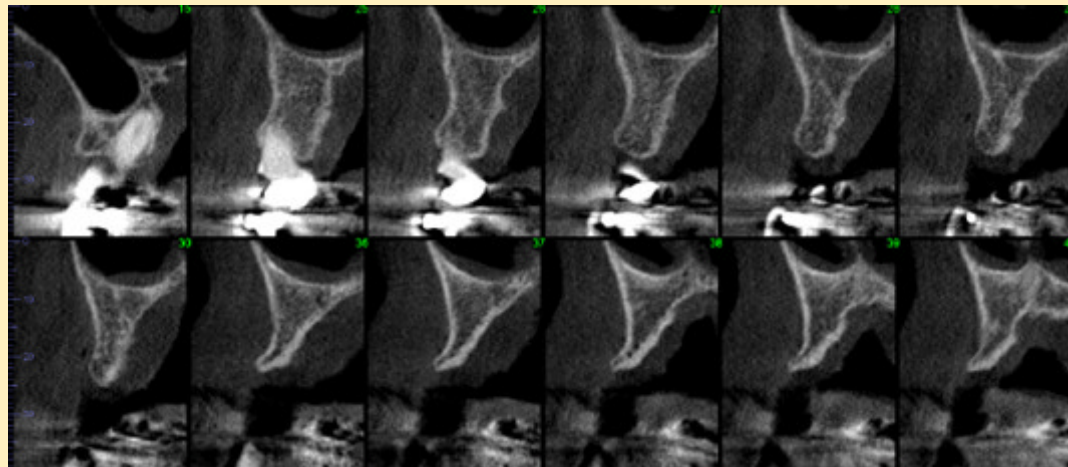


I-CAT


Imaging
Sciences
International 



IMPLANTS

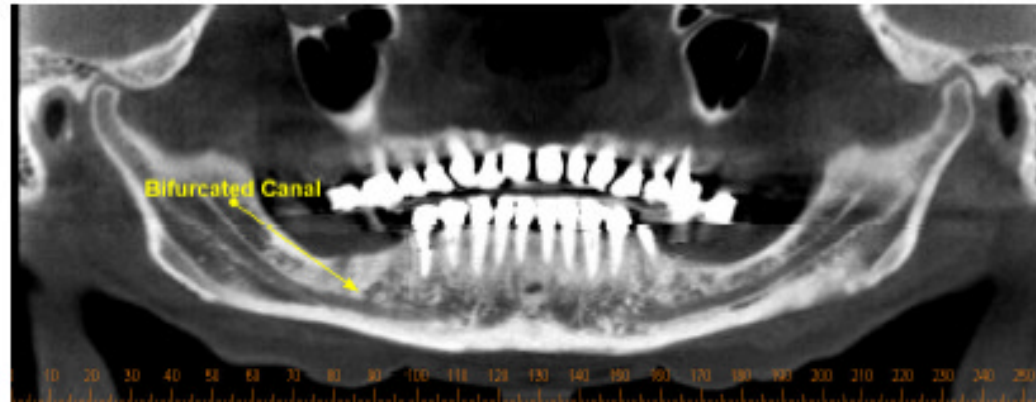


I-CAT

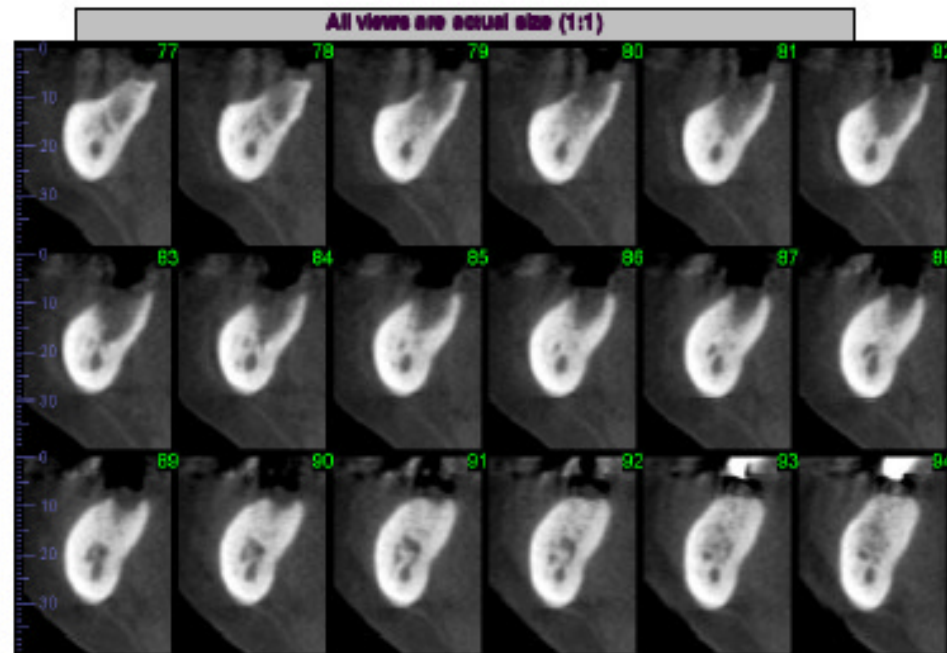


IMPLANTS

I-CAT

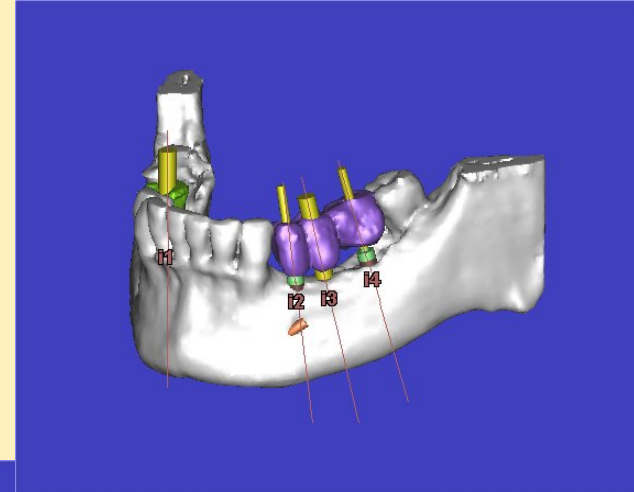
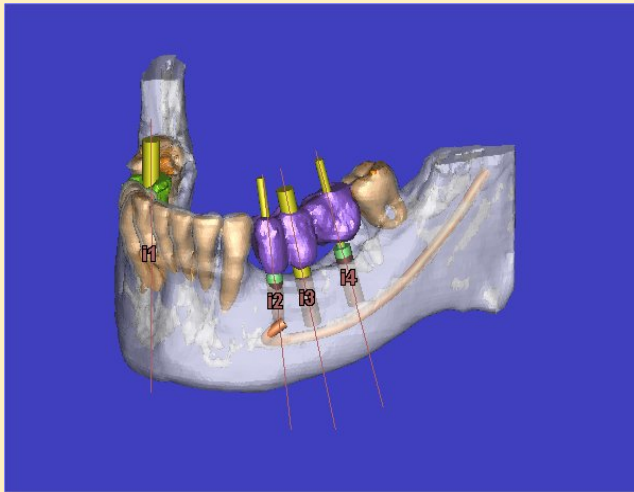


IMPLANTS

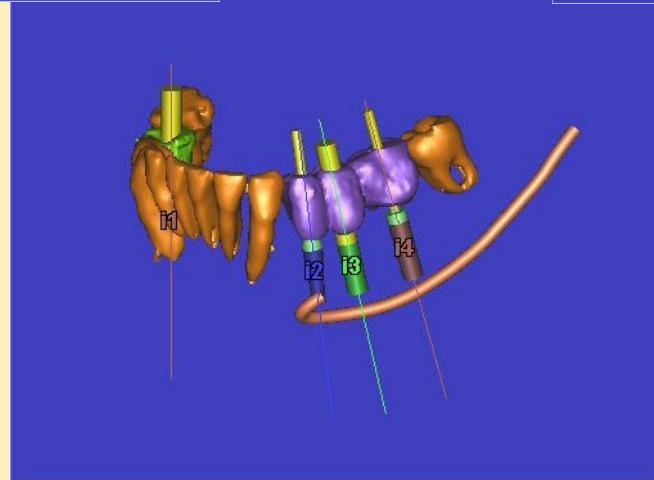


I-CAT

Imaging
Sciences
International 

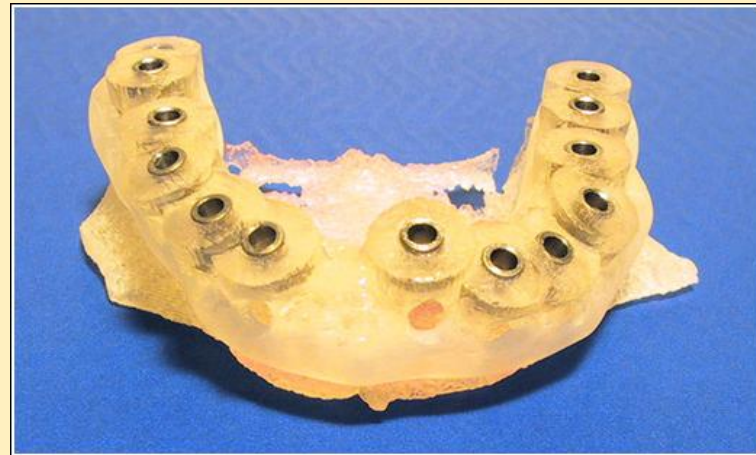
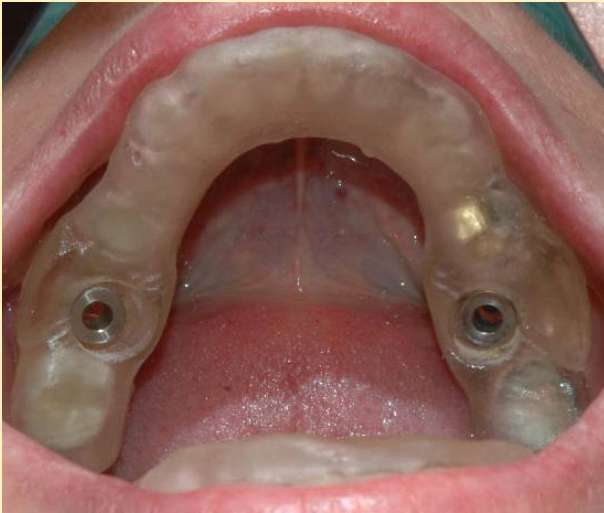
IMPLANTS



I-CAT

Imaging
Sciences
International 



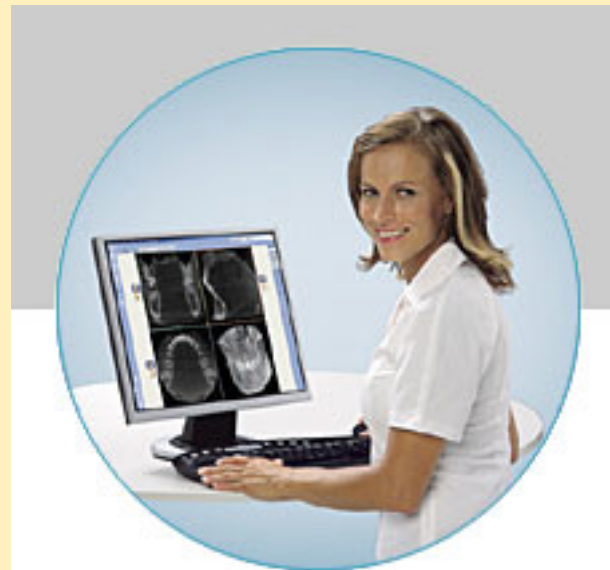
IMPLANTS

Pro Max 3D

PLANMECA

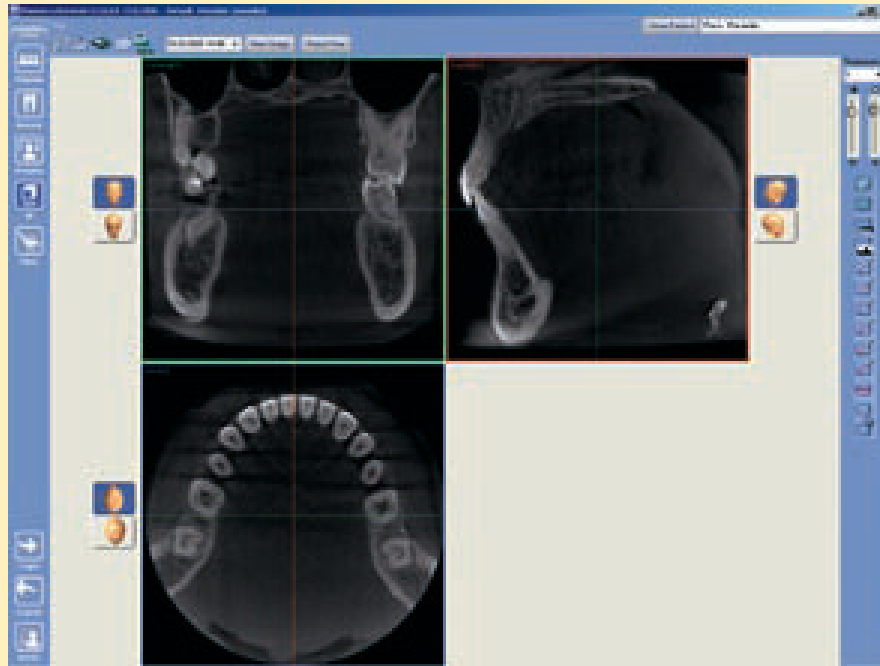

- Même principe
- Champ de 80X80 mm max.
- Irradiation: idem
- Résolution: 0,200 mm.



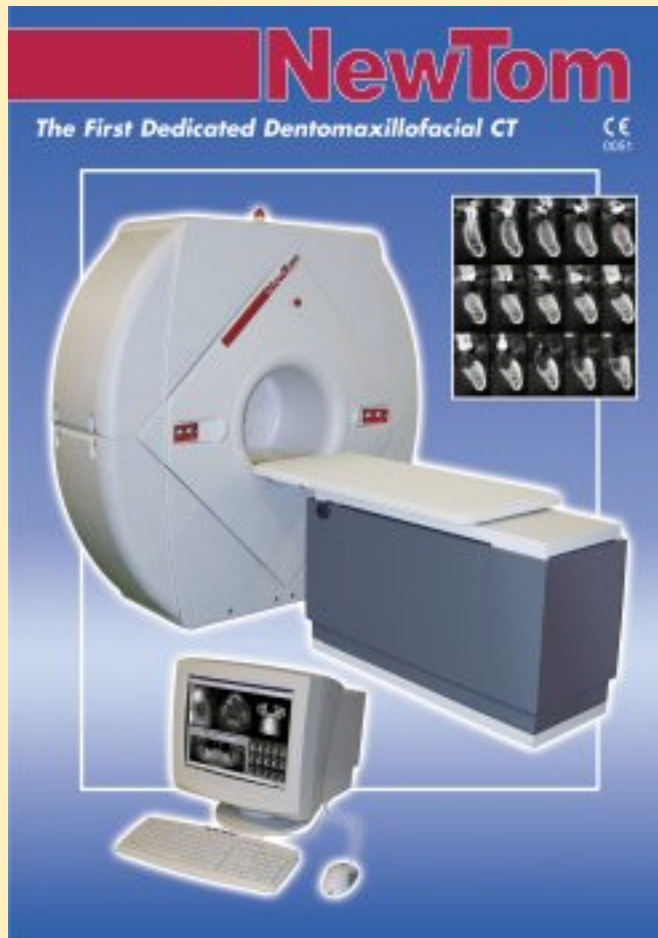Pro Max 3D

PLANMECA



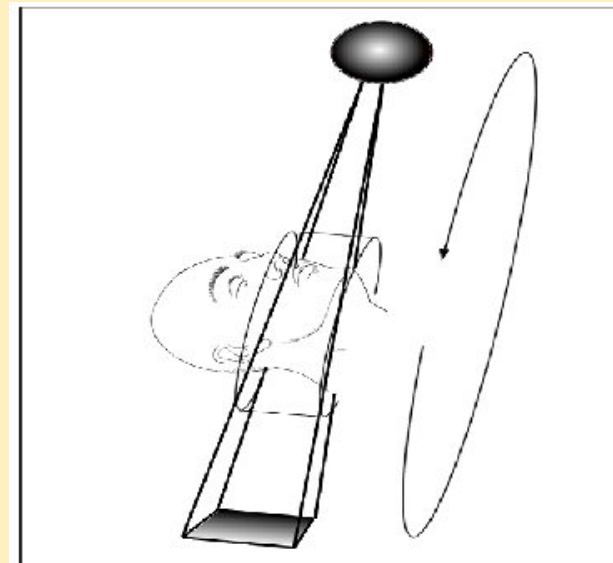
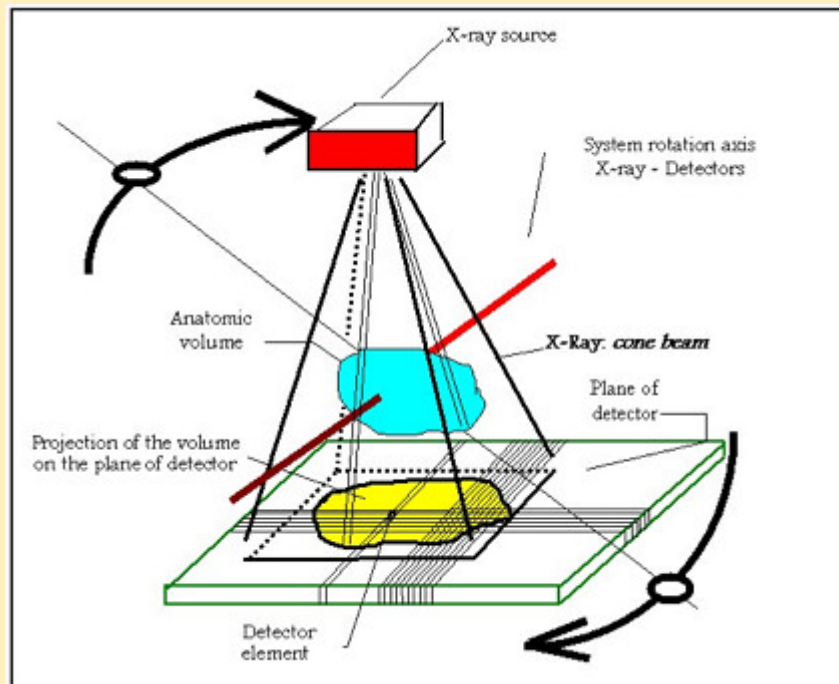
- Très proche de l' I-Cat
- C' est aussi un bon Pano
- Champ intermédiaire
- Images DICOM
 - Stockage
 - Logiciels de CAD
 - ...

Newtom 3G

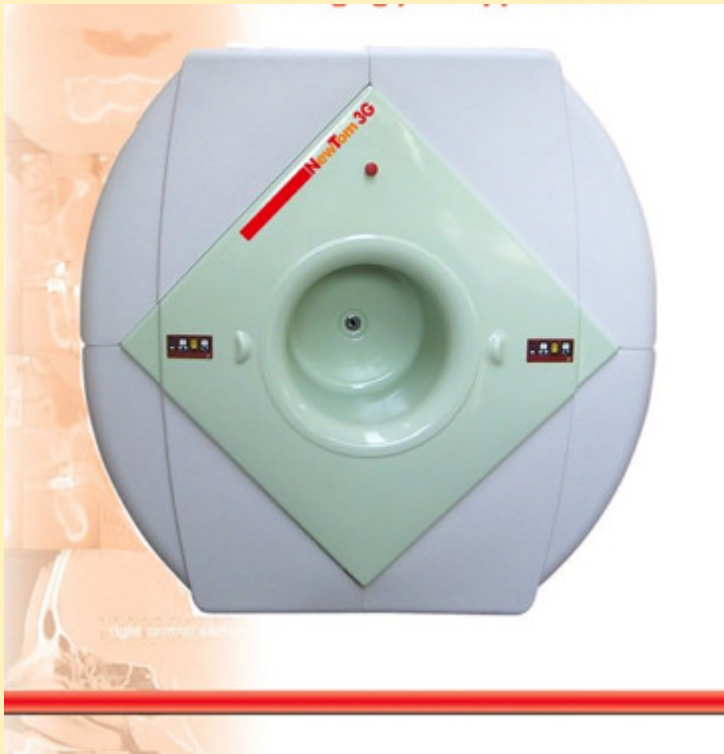

- « Petit » scanner
- Dents et maxillo-facial

Newton 3G

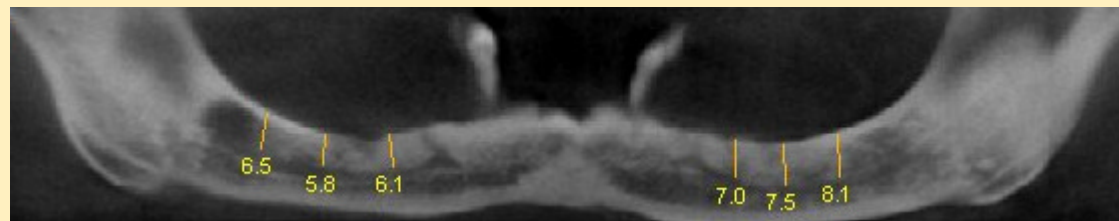
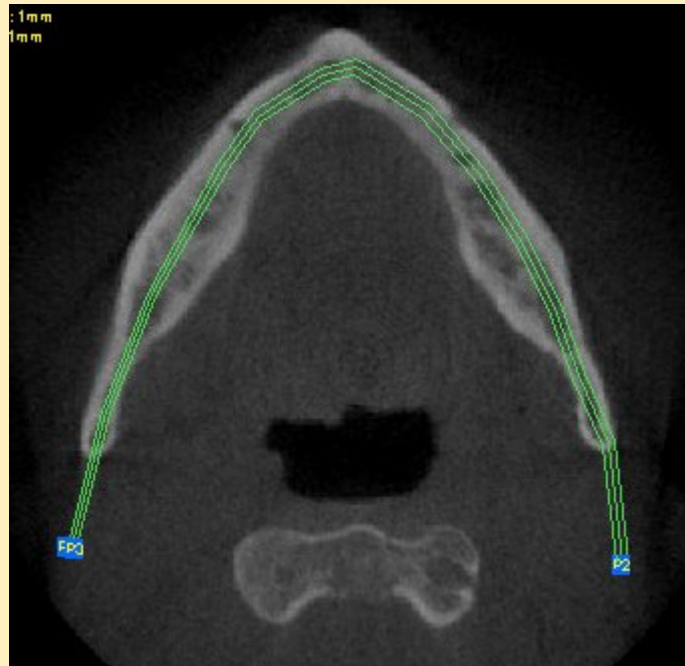


Newton 3G

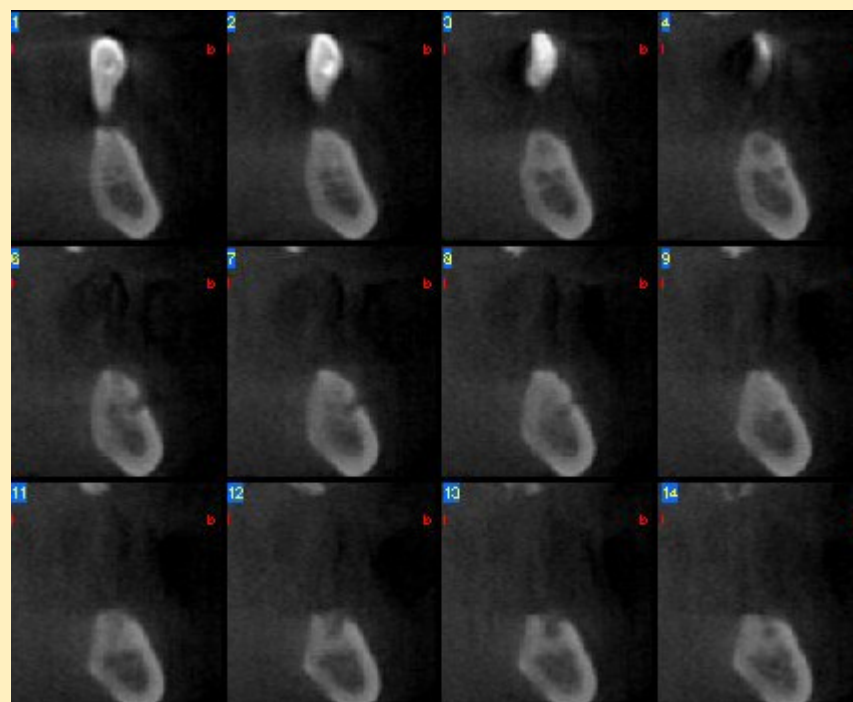
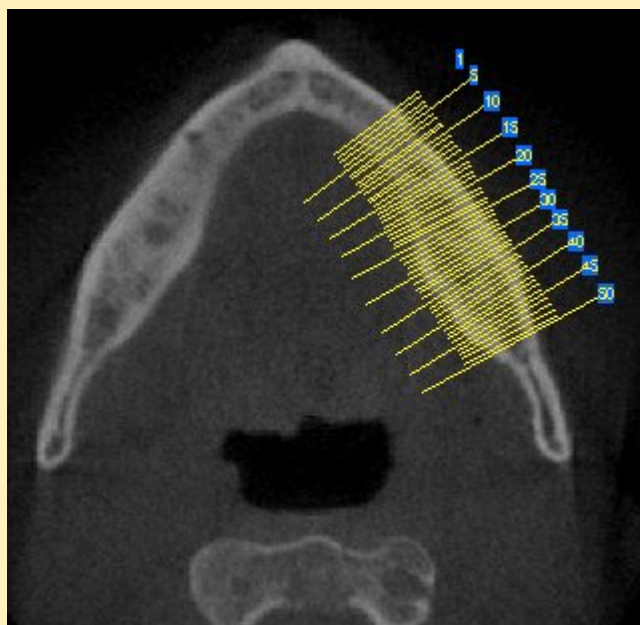


- **Résolution: 0,250 mm (0,125)**
- Dose: 50 microSv
- Capteur: 15X15 cm (proche ICat)

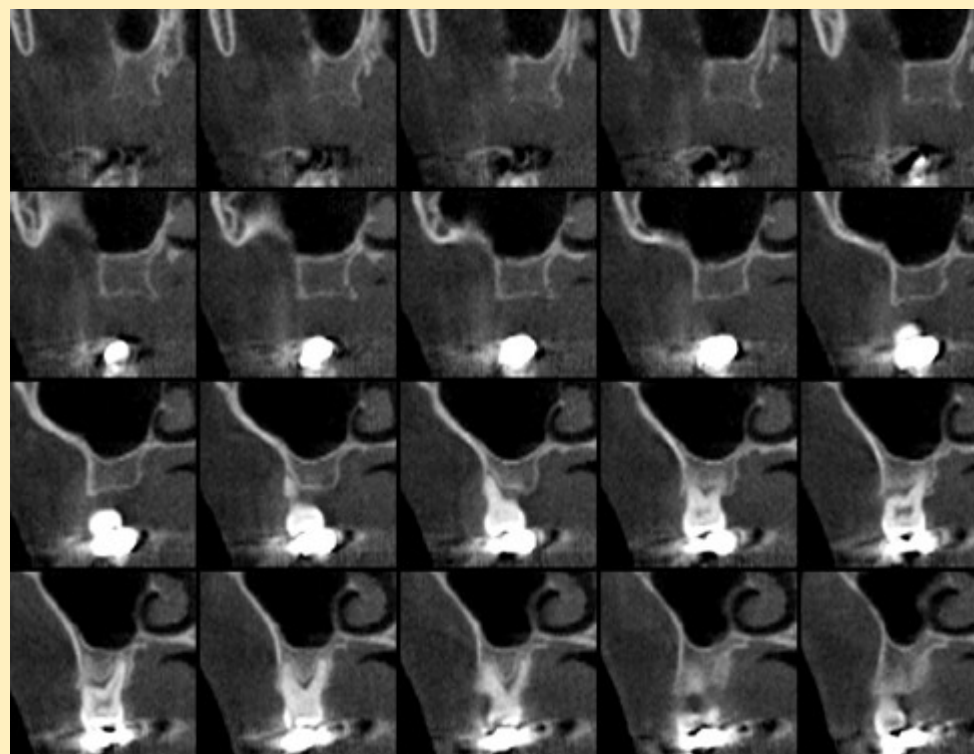
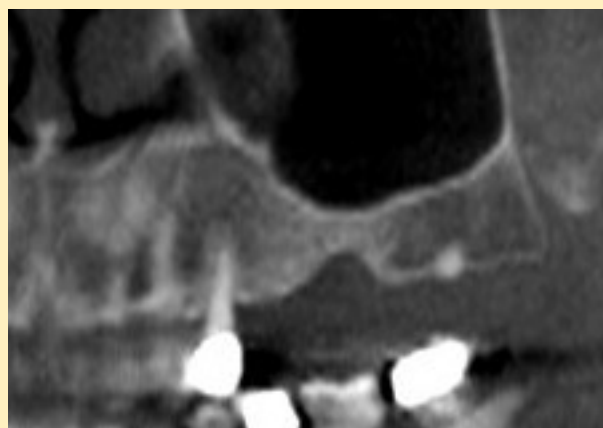
Newtom 3G



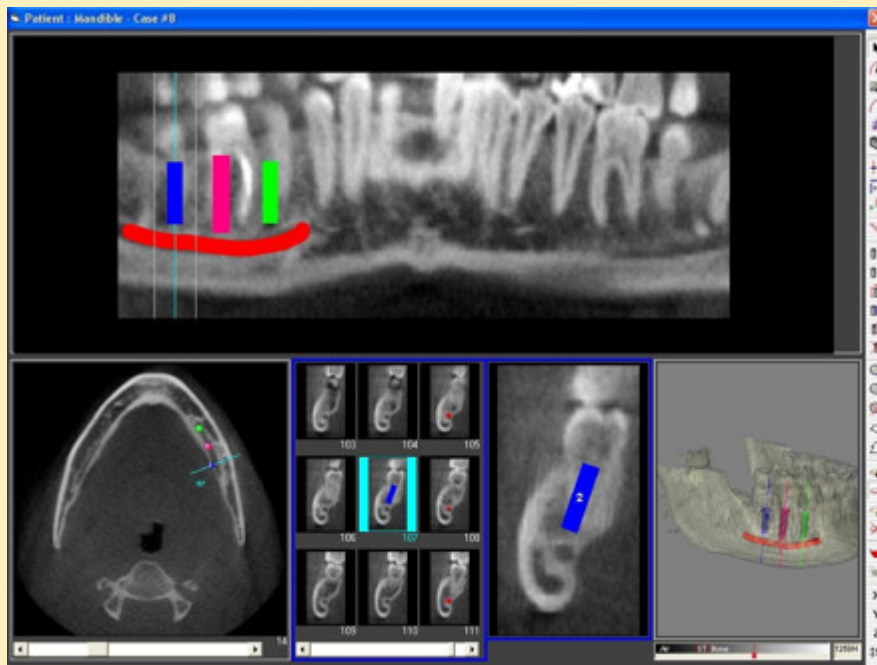
Newtonom 3G



Newtonom 3G

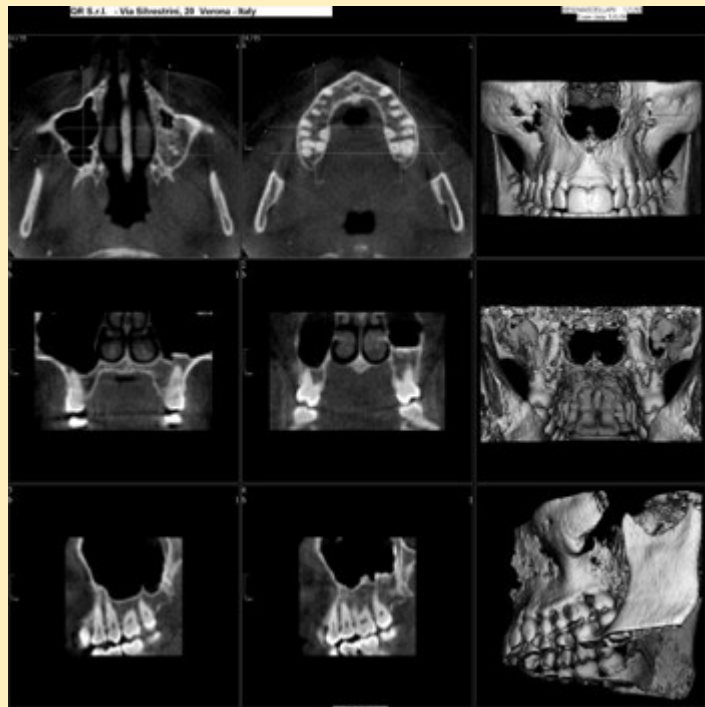

Newtom 3G




Logiciels de CAD spécifiques.

Newton 3G



Résolution limite (bruit++)
Temps d' acquisition long: 75 sec.
Temps de reconstructions très longs
(15/20mn).


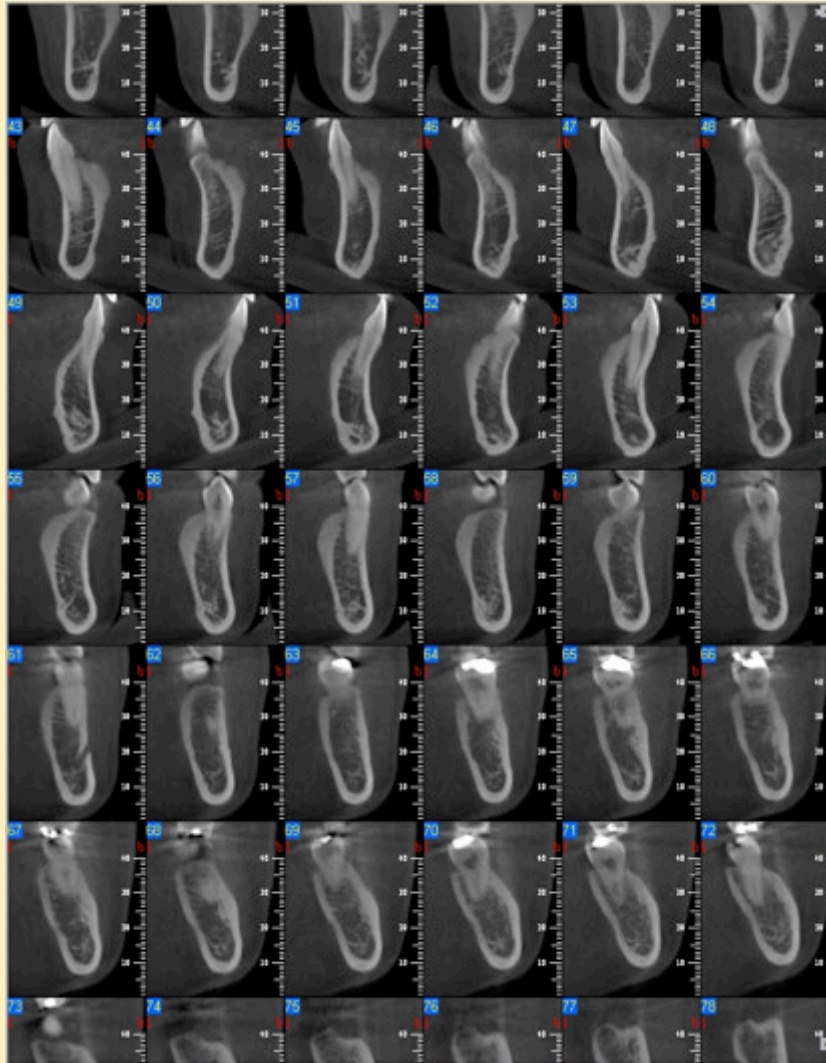
Newton VG



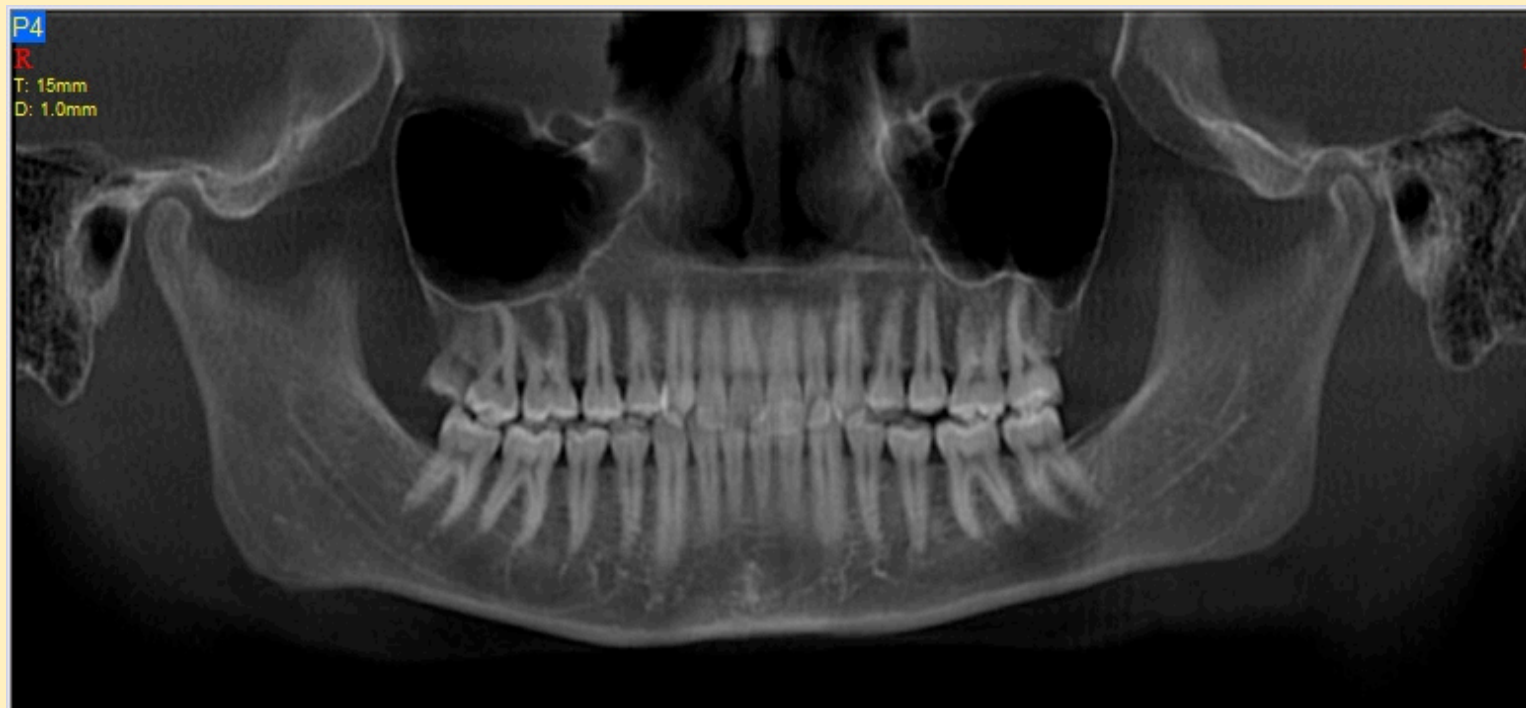Résolution limite (bruit++)
Temps d' acquisition long: 75 sec.
Temps de reconstructions très longs
(15/20mn).

NewTom VG

Newton VG



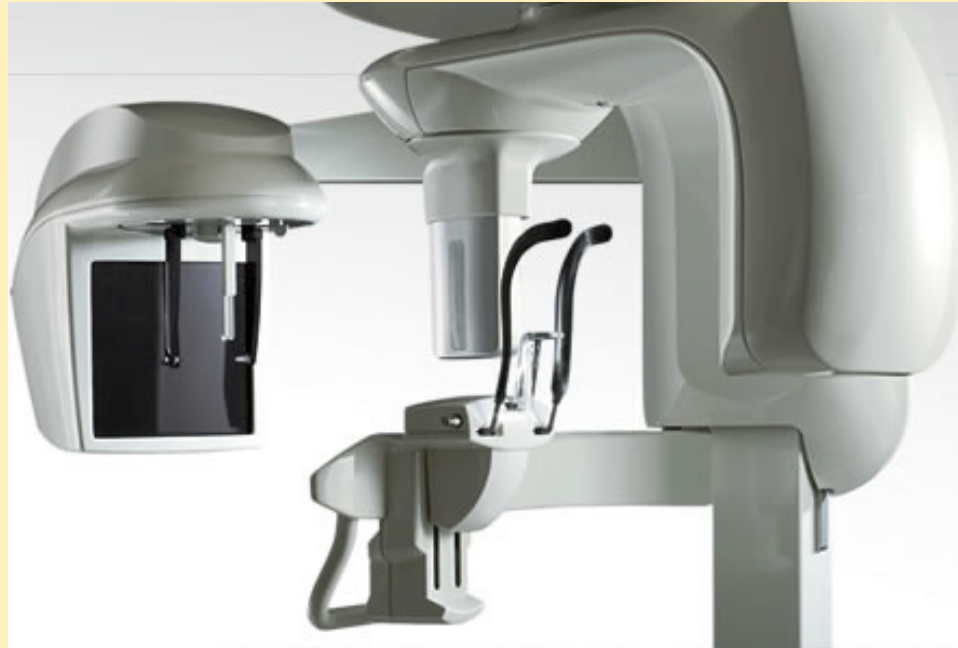Newton VG



Champ UTILE de 160 X140 mm

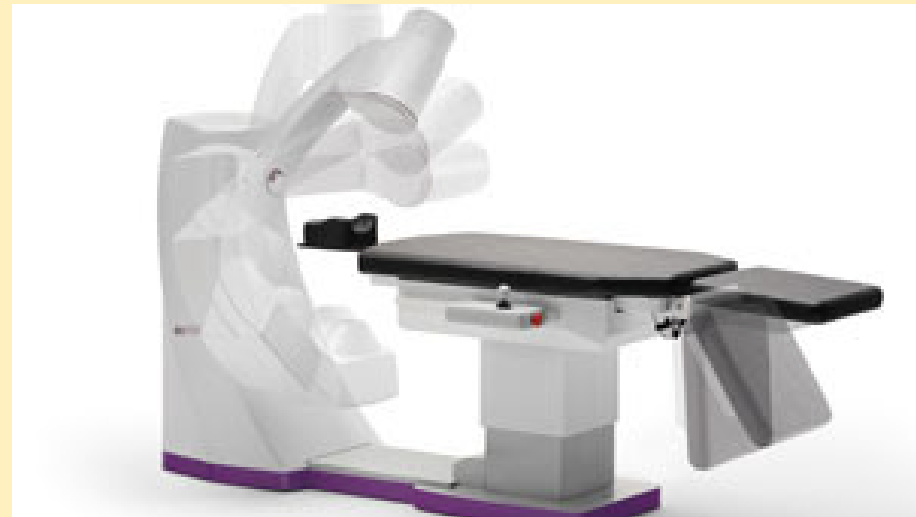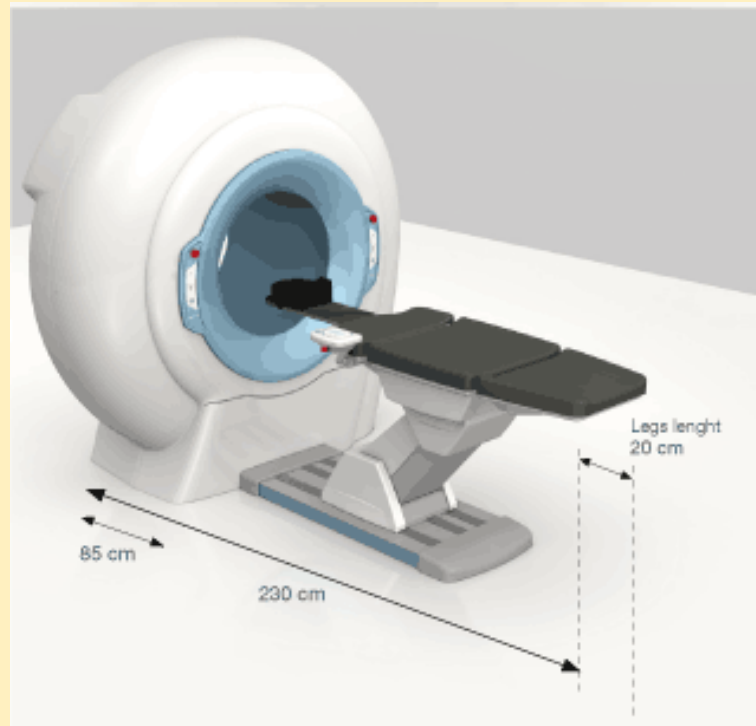
Kodak 9500

Kodak Dental Systems
by Carestream Health



Coût: 80 000 E (au lieu de 200 000)

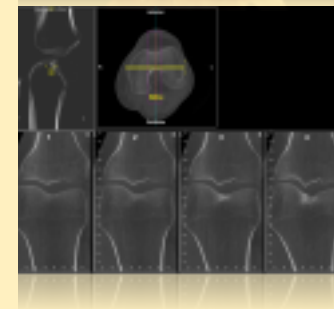
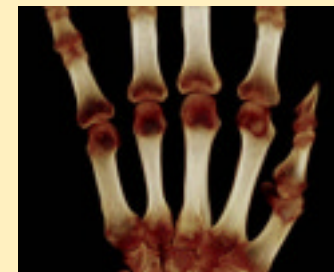
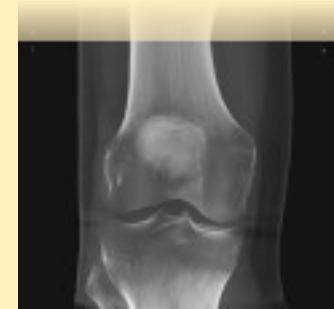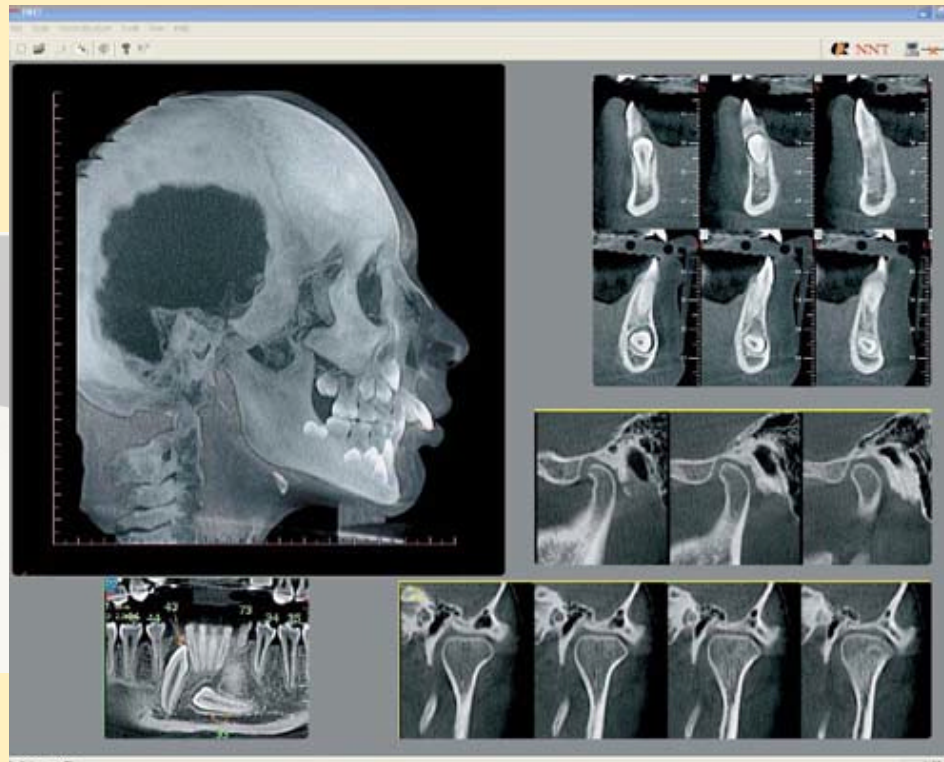
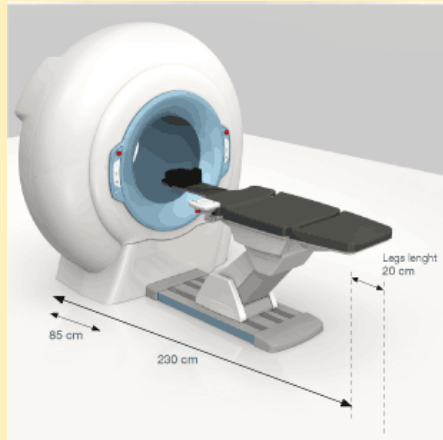
Nouvelle génération



NewTom 5G
Cone Beam 3D Imaging System

myray
new comfort
in digital imaging

Nouvelle génération



NewTom 5G
Cone Beam 3D Imaging System

CBCT: conclusions

- Moins cher et moins irradiant qu' un scanner (mais limité à l' étude dentaire).
- Petit champ= bonne résolution
- Grand champ= moindre résolution
- Évolution vers les grands champs
- Offre commerciale concentrée sur les dentistes (et non les radiologues...)